

## Case Report

# Disseminated Cryptococcosis presenting as cellulitis in a renal transplant recipient

Ramachandraiah Chaya<sup>1</sup>, Srinivasan Padmanabhan<sup>2</sup>, Venugopal Anandaswamy<sup>3</sup>, Aumir Moin<sup>4</sup>

<sup>1</sup>Department of Microbiology, Apollo BGS Hospitals, Mysore, Karnataka, India

<sup>2</sup>Department of Nephrology, Apollo BGS Hospitals, Mysore, Karnataka, India

<sup>3</sup>Department of Pathology, Apollo BGS Hospitals, Mysore, Karnataka, India

<sup>4</sup>Department of Neurology, Apollo BGS Hospitals, Mysore, Karnataka, India

## Abstract

Cellulitis is an unusual presentation of cryptococcal infection in renal allograft recipients. In such patients, disseminated cryptococcal infection can result in significant morbidity and mortality. Patients are often treated with antibiotics before a definitive diagnosis is made, delaying appropriate therapy. We describe the case of a 43-year-old post renal transplant recipient presenting with fever and swelling in the right thigh. On physical examination, the patient was found to have features suggestive of cellulitis with minimal slurring of speech. Material obtained from incision and drainage of the wound showed yeast cells resembling *Cryptococcus spp.* Blood culture and cerebrospinal fluid culture were also found to have growth of *Cryptococcus neoformans*. He received treatment with amphotericin B 6 mg/kg daily intravenously for two weeks, then continued with fluconazole 400 mg daily for three months. The patient showed a remarkable improvement. There was no recurrence of cryptococcosis after four months of follow-up. The diagnosis of disseminated cryptococcosis should be considered in differential diagnosis of cellulitis among non HIV immunocompromised hosts. A high clinical suspicion and early initiation of therapy is needed to recognize and treat patients effectively.

**Key words:** disseminated cryptococcosis; renal transplant recipient; cellulitis

*J Infect Dev Ctries* 2013; 7(1):060-063.

(Received 24 December 2011 – Accepted 15 March 2012)

Copyright © 2013 Chaya *et al.* This is an open-access article distributed under the Creative Commons Attribution License, which permits unrestricted use, distribution, and reproduction in any medium, provided the original work is properly cited.

## Introduction

Cryptococcosis remains a significant opportunistic infection in solid organ transplant recipients [1]. Although cryptococcal infection commonly presents as meningitis, secondary involvement of skin is apparent in about 10% to 20% of immunocompromised patients with cryptococcosis [2]. The skin lesions typically appear as pedunculated, dome-shaped papules with an umbilicated center [3]. Although cutaneous lesions largely represent hematogenous dissemination, skin has also been identified as a portal of entry of *Cryptococcus* species and a potential source of subsequent disseminated disease in solid organ transplant recipients [4]. We report a case of disseminated cryptococcosis which presented as cellulitis in a renal transplant recipient.

## Case report

A 43-year-old man who had received a kidney transplant 3 years back presented to the emergency department of our hospital complaining of headache,

fever with chills, and swelling and pain in the right thigh. At admission, the patient was conscious, alert and oriented. His pulse rate was 90 beats/minute, respiratory rate was 20 breaths/minute, and blood pressure was 130/90 mmHg. The patient was found to be febrile with tenderness, induration and erythema in the right thigh.

The patient was provisionally diagnosed to have cellulitis of the right thigh and blood was also sent for culture. He was started on antibiotics (amoxicillin clavulanate and metronidazole) and was also receiving immunosuppressants (cyclosporine, mycophenolate mofetil, and prednisolone) following renal transplantation. Despite treatment the patient had fever and chills with pain.

Doppler study of the right thigh was performed to rule out deep vein thrombosis, but the study showed focal subcutaneous edema in the right thigh. Incision and drainage was performed because the generalized swelling had increased. The drained material was sent to the microbiology department for Gram's stain and

culture. In laboratory examinations of the material, Gram stain showed a moderate number of pus cells with a significant number of round yeast cells with an unstained capsule around them resembling *Cryptococcus spp.* (Figure 1). The material was also stained using India ink to demonstrate round budding yeast cells with a clear halo, indicating the capsule (Figure 2). Culture on chocolate agar and Sabouraud's dextrose agar showed cream-coloured, smooth, mucoid yeast-like colonies of *Cryptococcus neoformans*. The identification was further confirmed by Gram stain and positive urease test. Blood culture also yielded *Cryptococcus neoformans* on the third day of hospitalization (Figure 3). Laboratory studies were obtained and revealed a white blood cell (WBC) count of 7070 cells per mm<sup>3</sup>, with 88% polymorphonucleated cells (PMNs), platelet count of  $111 \times 10^3$  cells per mm<sup>3</sup> and blood C-reactive protein (CRP) level of 96 mg/L. His INR was 1.22. An extended metabolic and renal panel demonstrated: sodium 120 mmol/L, potassium 4.6 mmol/L, chloride 97 mmol/L, creatinine 1.2 mg/dL, urea 41 mg/dL and uric acid 2.8 mg/dL. Cerebrospinal fluid examination revealed protein level of 42 mg/dL and glucose of 10 mg/dL. Cryptococcal antigen test was positive by latex agglutination.

Therapy was initiated with amphotericin B lipid complex, 6 mg/kg/day for two weeks. A total dose of 200 mg/day was administered by intravenous infusion, using a controlled infusion device, over a period of approximately 180 minutes. An in-line membrane filter was used for the intravenous infusion of amphotericin B lipid complex; the pore diameter of the filter was 5 micron. During the initial dosing period, the patient was under close clinical observation. The patient showed significant clinical improvement without any adverse effects. After two weeks of amphotericin B, therapy was continued with oral fluconazole 400 mg daily for three months. After the symptoms subsided the patient was discharged and followed up at our outpatient department with oral fluconazole. There was no recurrence of cryptococcosis after four months of follow-up.

## Discussion

Fungal infection following solid-organ transplantation remains a major cause of morbidity and mortality [5]. Cryptococcosis is the third most common invasive fungal infection in organ transplant recipients, after candidiasis and aspergillosis [6]. The immunosuppressive regimens used in solid organ

transplantation are potent inhibitors of T-cell immunity. This predisposes patients to infection by pathogens such as *Cryptococcus neoformans*, with meningitis having an incidence of five per 1,000 transplant recipients, as was seen in the present case. Mortality in these patients is very high at 50%, despite advances in anti-fungal chemotherapy [7].

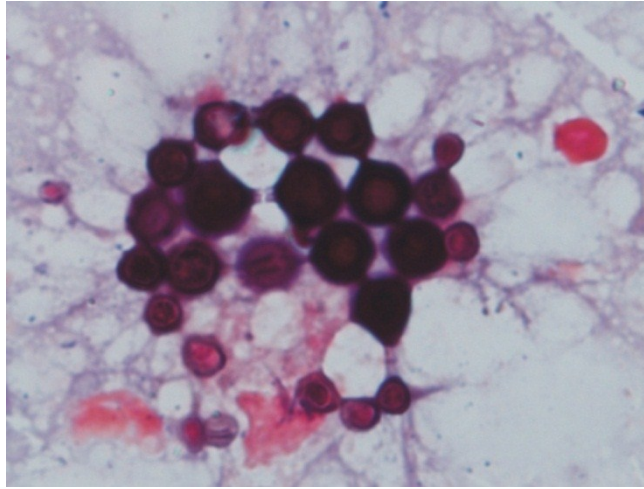
Although a rarity, several cases of cellulitis have also been reported, which appear to be mainly restricted to lower parts of the body, especially the legs, as was seen in the present case [8].

Disseminated cryptococcosis is defined by 1) a positive culture from at least two different sites, or 2) a positive blood culture [9]. The present case falls into both categories. The clinical presentation of disseminated cryptococcosis is variable and depends on the organ systems involved. *C. neoformans* has been identified in cultures from blood, cerebrospinal fluid (CSF), sputum, ascites, urine, bone marrow, and skin [10]. Central nervous system (CNS) involvement is the most common manifestation of disseminated cryptococcosis [9]. Patients often present in a subacute manner with headache and fever, as was seen in the present case [11].

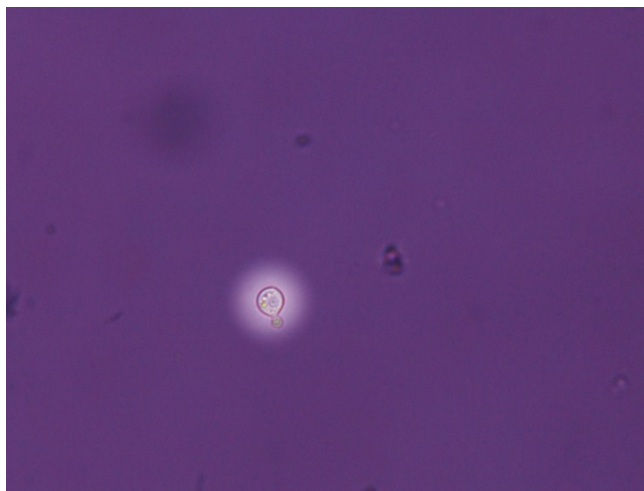
The laboratory diagnosis of cryptococcosis is established by the isolation of the organism in culture, histopathology, or detection of its polysaccharide capsular antigen [12]. The present case was also diagnosed by culture, India ink and latex agglutination test. The organism grows in blood and chocolate agar within 3 to 5 days. Analysis of CSF usually reveals a poor white blood cell (WBC) count, with normal or low CSF glucose levels, and a positive cryptococcal antigen test. The India ink test is more specific and helps in demonstrating the fungus [13].

The Infectious Diseases Society of America (IDSA) recently updated its guidelines on the management of cryptococcal disease. Patients with central nervous system (CNS) disease should be treated with liposomal amphotericin B (AmB), 3 to 4 mg per kg per day intravenously, or amphotericin B lipid complex (5 mg per kg per day, intravenously) plus flucytosine (100 mg per kg per day in four divided doses) for at least two weeks, followed by fluconazole (400 to 800 mg [6 to 12 mg per kg] per day, orally) for eight weeks, then a lower dose of fluconazole (200 to 400 mg per day, orally) for six to 12 months. If induction therapy does not include flucytosine, four to six weeks of therapy with liposomal formulations of amphotericin B should be considered. Liposomal amphotericin B (6 mg per kg

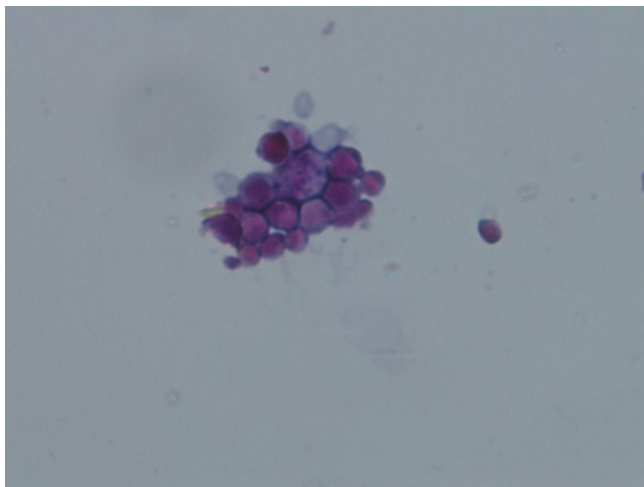
**Figure 1.** Gram stain of aspirate showing round budding yeast cells



**Figure 2.** India ink preparation of aspirate showing capsulated budding yeast cell



**Figure 3.** Gram stain of blood sample showing round yeast cells



per day) may be considered for patients with high-fungal burden disease or relapse [14]. According to a study by Hsin-Yun Sun *et al.*, the use of lipid formulations of AmB has been associated with a significant six-fold decrease in mortality. The mortality was lower among patients receiving lipid formulations of AmB, compared with those receiving AmB deoxycholate (odds ratio, 0.16; 95% confidence interval, 0.03–0.84;  $P = 0.03$ ). Overall, flucytosine was less likely to be used when induction therapy included lipid formulations of AmB but not AmB deoxycholate and fluconazole [15]. The present case was also started with liposomal formulation of amphotericin B without flucytosine in the induction phase of therapy. Our patient showed significant clinical improvement after therapy.

In conclusion, cellulitis is an unusual presentation of cryptococcal infection in renal allograft recipients. In such patients, disseminated cryptococcal infection can result in significant morbidity and mortality. Patients are often treated with antibiotics before a definitive diagnosis is made, delaying appropriate therapy. Lipid formulations of Amphotericin B have emerged as the main treatment option for cryptococcosis and appear to offer a survival benefit for these patients. Hence a high clinical suspicion and early initiation of therapy are needed to recognize and treat patients effectively.

### Acknowledgements

The authors are grateful to Dr. S. Sujatha, Professor, Department of Microbiology, Jawaharlal Institute for Postgraduate Medical Education and Research (JIPMER), Puducherry, India, for her continuous support and valuable guidance.

### References

1. Singh N, Dromer F, Perfect JR, Olivier Lortholary O (2008) Cryptococcosis in solid organ transplant recipients: Current state of the science. *Clinical Infectious Diseases* 47: 1321-1327.
2. Tilak R, Prakash P, Nigam C, Tilak V, Gambhir IS, A K Gulati AK (2009) Cryptococcal meningitis with an antecedent cutaneous cryptococcal lesion. *Dermatology Online Journal* 15: 12.
3. Probst C, Pongratz G, Capellino S, Szeimies RM, Schölmerich J, Fleck M, Salzberger B, Ehrenstein B (2010) Cryptococcosis mimicking cutaneous cellulitis in a patient suffering from rheumatoid arthritis. *BMC Infectious Diseases* 10: 239.
4. Neuville S, Dromer F, Morin O, Dupont B, Ronin O, Lortholary O; the French Cryptococcosis Study Group (2003)

Primary cutaneous cryptococcosis: a distinct clinical entity. *Clin Infect Dis* 36: 337-347.

5. Silveira FP and Husain S (2008) Fungal infections in solid organ transplantation. *Med Mycol* 45: 305-320.
6. Castro Ferreira I, Carvalho C, Coentrao L, Gaiao S, Bustorff M, Santos J, Sampaio S, Portugal R, Pestana M (2011) Early-onset of disseminated cryptococcal infection in two renal transplant recipients. *Clin Nephrol* 75: 542-546.
7. SA Summers, A Dorling, JJ Boyle, S Shaunak (2005) Cure of disseminated cryptococcal infection in a renal allograft recipient after addition of  $\gamma$ -interferon to anti-fungal therapy. *American Journal of Transplantation* 5: 2067-2069.
8. Christianson JC, Engber W, Andes D (2003) Primary cutaneous cryptococcosis in immunocompetent and immunocompromised hosts. *Med Mycol* 41: 177-188.
9. Chuang YM, Ho YC, Chang HT, Yu CJ, Yang PC, Hsueh PR (2008) Disseminated cryptococcosis in HIV-uninfected patients. *Eur J Clin Microbiol Infect Dis* 27: 307-310.
10. Kokturk N, Ekim N, Kervan F, Arman D, Memis L, Caglar K, Kalkanci A, Demircan S, Kurul C, Akyurek N (2005) Disseminated cryptococcosis in a human immunodeficiency virus-negative patient: a case report. *Mycoses* 48: 270-274.
11. Vasant Baradkar, M Mathur, A De, S Kumar, M Rathi (2009) Prevalence and clinical presentation of Cryptococcal meningitis among HIV seropositive patients. *Indian Journal of Sexually Transmitted Diseases and AIDS* 30: 19-22.q.
12. Srinivas U, Kar R, Saxena R, Prasad PH (2008) Cryptococcal neofomans profiles in peripheral blood neutrophils: An unusual presentation. *Indian J Pathol Microbiol* 51: 296-297.
13. Subramanian S and Mathai D (2008) Clinical manifestations and management of cryptococcal infection. *J Postgrad Med* 51: 2126.
14. Perfect JR, Dismukes WE, Dromer F, Goldman DL, John R Graybill JR (2010) Clinical practice guidelines for the management of cryptococcal disease: 2010 update by the infectious diseases society of america. *Clin Infect Dis* 50: 291-322.
15. Sun HY, Wagener MM, Singh S (2009) Cryptococcosis in solid-organ, hematopoietic stem cell, and tissue transplant recipients: Evidence-based evolving trends. *Clin Infect Dis* 48: 1566-1576.

### Corresponding author

Dr. D. R. Chaya MD  
Microbiologist  
Department of Lab Services  
Apollo BGS Hospital  
Adichunchanagiri Road  
Kuvempunagar  
Mysore 570 023  
Karnataka  
India  
Mobile No. 09986687037  
Email: drchayadr17@yahoo.com

**Conflict of interests:** No conflict of interests is declared.