

Case report

A finding of live *Fasciolopsis buski* in an ileostomy opening

Rakesh K. Mahajan¹, Shalini Duggal², Niraj K. Biswas³, Nandini Duggal¹, Charoo Hans¹

¹Department of Microbiology, Dr Ram Manohar Lohia Hospital, New Delhi, India

²Department of Microbiology, Dr B. L. Kapur Memorial Hospital, Delhi, India

³Jhalawar Medical College, Jhalawar, Rajasthan, India

Abstract

A pair of live *Fasciolopsis buski* wriggled their way out through the ileostomy opening in a young adult male who had recently migrated to Delhi and had met with a road traffic accident. Finding this parasite in the national capital, a non endemic area for Fasciolopsiasis, prompted us to emphasize the importance of changes in the ecology, human demography, and human behaviour that may provide an environment conducive to their adaptability to the new geographical requirements. Awareness of Fasciolopsiasis, which is endemic in some regions of India, especially in rural settings, is an important issue because early diagnosis is essential. Hence, a surveillance mechanism among the migratory population to institute preventive interventions is necessary.

Key words: endemic, intestinal trematode, plant-borne, migratory population

J Infect Dev Ctries 2010; 4(6):401-403.

(Received 3 July 2009 – Accepted 30 November 2009)

Copyright © 2010 Mahajan *et al.* This is an open-access article distributed under the Creative Commons Attribution License, which permits unrestricted use, distribution, and reproduction in any medium, provided the original work is properly cited.

Introduction

Fasciolopsis buski (*F. buski*), also called giant intestinal fluke, is a duodenal digenetic trematode, of the Fasciolidae family. It was described for the first time by Busk in the duodenum of a sailor in 1843 in London and its life cycle in humans was first described by Barlow in 1925 [1]. *F. buski* is found mainly in southeast Asian countries including India. It seems to be restricted to areas where water plants such as water chestnut, water caltrops, water bamboo, etc. are cultivated and in communities that consume these water plants uncooked.

Aquatic snails act as intermediate host for the parasite and harbor the infective metacercariae that encyst on water plants after being released into the water. The mature fluke develops and starts laying eggs within three to four months after infective metacercariae have been ingested [2]. Two species of the snails, *Segmentina (Polypylis) hemisphaerula* and *Segmentina (Trochorbis) trochoides*, have been particularly found to play an important role in disease transmission. Though pigs and humans both act as definitive hosts, pigs appear to be the only reservoir of infection [3].

Clinically, fasciolopsiasis may present with occasional loose stools, loss of weight and abdominal pain. As the worm burden increases, the patient may

give history of passing greenish yellow, extremely malodorous stools and there may be associated edema of the face and limbs, generalized abdominal pain, ascitis and even death [4]. Adult worms at the site of attachment cause deep inflammatory ulcerations and their metabolites on absorption may also induce toxic and sensitization reactions.

The present case is first of its kind where an ileostomy opening acted as a corridor for the escape of adult *Fasciolopsis buski*.

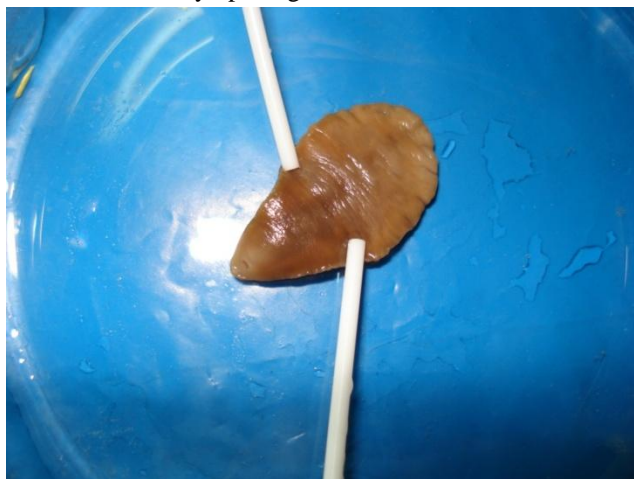
Case report

An 18-year-old boy fell down from a moving vehicle and was brought to the surgical emergency of our hospital. In the accident, he sustained a fracture at the neck of the femur as well as a blunt injury to the abdomen, resulting in peritonitis. Ultrasonography abdomen revealed a significant amount of free fluid in the peritoneal cavity.

The patient was taken for an exploratory laparotomy. About a 20 cm length of ileum was found gangrenous and an ileostomy was undertaken after resecting the dead portion. About 500 ml of fecal fluid was also removed.

About one month after the surgery, while replacing the ileostomy bag with a fresh one, the

Figure 1. Adult worm of *Fasciolopsis buski* recovered from the ileostomy opening.



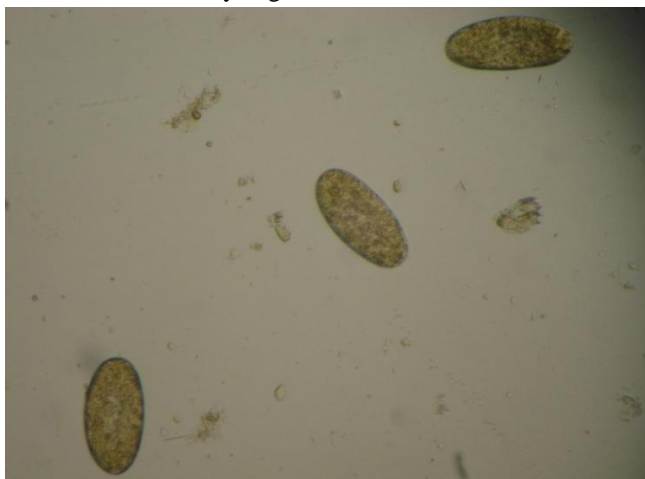
patient felt two large fleshy structures crawling on the abdominal wall around the ileostomy opening. Immediately, he called for the resident doctor on duty, who collected them in a glass container and referred the contents immediately to the Microbiology Department for identification and comments.

When transferred to a petri dish, the contents proved to be two large, fleshy worms whose leaf shape doubtlessly pointed to their lineage of Flukes. This is the first report of fasciolopsiasis from our tertiary care hospital and also the very first case where live *F. buski* pushed their way out through an ileostomy opening.

The worms were dorsoventrally flattened, non segmented and reddish brown in color. Absence of a cephalic cone ruled out the probability of the parasite as being *Fasciola hepatica*. One of them measured about 36 mm × 24mm and the other about 40 mm × 20mm in size. The ventral sucker was prominent in both, while the oral sucker was clear in only one of them. The worms had morphology classical of *Fasciolopsis buski* (Figure 1).

To further assess further whether the patient was harboring more of *F. buski* or some other parasites, contents of the ileostomy bag were examined macro- as well as microscopically. Formol ether concentration of the sample showed a number of large, ovoid bile-stained ova morphologically resembling those of *F. buski* (Figure 2), though it was not possible to differentiate them from ova of *F. hepatica*. The parasites were fixed in formalin, and their unbranched intestinal caeca and uterine segment examined under 40X. These were teased with a 25 G

Figure 2: Ova of *Fasciolopsis buski* recovered from contents of ileostomy bag.



needle to release the ova, which were again visualized on microscopy.

Other laboratory investigations revealed Hb 7.2 gm%, TLC 13,500/cu mm, DLC: P₇₈L₁₃E₉. Absolute eosinophil count was 900/cu mm and immunoglobulin profile showed elevated levels of IgA at 602.0 mg/dL (reference range 90-310 mg/dL).

To de-worm, the patient was given Nitazoxanide [5] 500 mg BD for five days. After taking just two doses of the drug, the patient passed five more worms through the ileostomy opening. Three more stool samples were examined over the next week and none of them showed any evidence of ova/cyst. Thereafter, the patient did not complain of any such findings and was discharged after his wound healed.

Discussion

Though fasciolopsiasis appears to be attracting research interest, not much literature is available on the subject topic. *F. buski* infestation has been reported in India from mainly from Bihar [6], Uttar Pradesh, and Maharashtra but also sporadically from other states [7]. It appears to be affecting mainly rural areas where certain water plants are eaten raw. This particular case migrated to Delhi just five days before the accident from eastern Uttar Pradesh where he worked as an agriculture farm laborer. There was a freshwater pond in his native village that has aquatic plants such as water chestnut, and he gave history of eating raw water chestnuts and vegetables washed in the pond water. Snails abound in that pond and the surrounding damp area. The patient had a significant past history of vague abdominal pain and passing loose stools.

Delhi, the national capital, is emerging as a hot favorite for migrants in anticipation of some job opportunities. The migrant population is bringing with them certain problems that have historically been endemic problems of their native areas. The Yamuna River, which traverses practically the whole city, has certain sectors where edible water plants and snails are plenty; this situation can play a significant role in providing epidemiological support allowing this parasite to establish in this geographical area. This report of fasciolopsiasis from an area that is completely non-endemic for this clinical entity underscores the need for a surveillance mechanism through a high degree of suspicion among patients from endemic areas with complaints compatible with fasciolopsiasis.

This case also raises another possibility as to whether Nitazoxanide can be included in the treatment strategy of fasciolopsiasis as just two doses of the drug caused expulsion of five more worms after the initial two that were removed. Although the drug of choice is Praziquantel, the patient in this case was treated with Nitazoxanide, a novel agent that has a broad spectrum of activity against many other gastrointestinal pathogens, as these cases may have multiple parasitic infestations [5,6]. Use of Nitazoxanide would definitely need more scientific support since some other unknown mechanism might have been operative in this subject case with an ileostomy opening.

Given that the present distribution of parasitic diseases reflects the success of hygiene and control measures in the more developed parts of the world rather than any clear geographical or ecological restriction, it becomes extremely pertinent to stress the need to disseminate health education at the community level focused on measures such as the importance of properly cleaning and processing vegetables, discouraging the use of night soil as

fertilizer etc. Such measures could go a long way in preventing and controlling a battery of infectious diseases including fasciolopsiasis. Furthermore, the importance of continuing medical education to medical personnel in areas of emerging and re-emerging problems in tropical countries to sensitize them to current issues of public health cannot be overemphasized.

References

1. Chi Hiong UGo, Burke AC. Intestinal flukes. Updated 14 December 2007. website: www.emedicine.com/med/topic1177.htm Accessed on 18 February 2009.
2. Graczyk TK, Gilman RH, Fried B (2001) Fasciolopsiasis: Is it a controllable food-borne disease? *Parasitol Res* 87: 80-83.
3. Manning GS and Ratanarat C (1970) *Fasciolopsis buski* (Lankester, 1857) in Thailand. *Am J Trop Med Hyg* 19: 613-19.
4. Rabbani GH, Gilman RH, Kabir I, Mondel G (1985) The treatment of *Fasciolopsis buski* infection in children: A comparison of thiabendazole, mebendazole, levamisole, pyrantel pamoate, hexaresorcinol and tetrachloroethylene. *Trans R Soc Trop Med Hyg* 79: 513-15.
5. DA Bobak (2006) Use of nitazoxanide for gastrointestinal tract infections: treatment of protozoan parasitic infection and beyond. *Curr Infect Dis Rep* 8:91-95.
6. Rai S, Wadhwa V, Kharbanda P, Uppal B (2007) A case of poly-parasitism involving a trematode and four different nematodes in a migrant from Bihar. *Indian J Med Microbiol* 25: 62-63.
7. CD Alert. Food borne trematode (Fluke) infections: A neglected health problem in India. November 2005, vol.9 no. 11.

Corresponding author

Shalini Duggal
Department of Microbiology
B.L.Kapur Memorial Hospital
Delhi, India
shaliniduggal2005@rediffmail.com

Conflict of interests: No conflict of interests is declared.