

Case report

Molecular diagnosis and source tracing of an infection of *Aureobasidium pullulans*

Dongli Liu¹, Lin Ma¹, Yi Shi¹, Anli Wang¹, Changhong Liu¹

¹ Institute of Pathogenic Microbiology, Shaanxi Provincial Center for Disease Control and Prevention, Xi'an 710054, Shaanxi, China

Abstract

Aureobasidium pullulans (*A. pullulans*) is a dematiaceous, yeast-like fungus that is ubiquitous in nature, which can colonize the human hair and skin. *A. pullulans* has been clinically implicated to cause skin and soft tissue infections, meningitis, splenic abscesses, and peritonitis. Herein, molecular diagnostic of internal transcribed spacer (ITS) sequencing was used to investigate a suspected case of *A. pullulans* infection, and the infection source had been traced. A 27-year-old female case was suspected of kala-azar due to the recurrent fever. Bone marrow specimens were analyzed. The samples were negative for *Leishmania*, *Penicillium marneffei* and *Histoplasma capsulatum*. DNA was extracted from the bone marrow specimens, and the 583-bp sequence was amplified with the fungal ITS universal primers. The sequence was compared by Blast query to be identified as *A. pullulans*. A strain of *A. pullulans* was also isolated from the kitchen of the patient's living room. Culture characteristics were the same as the human pathogens of *A. pullulans*, and the ITS sequence was identical to the bone marrow ITS amplification. In conclusion, a deep infection caused by *A. pullulans* is rare, often occurring in the indwelling catheter, which may cause peritonitis and other symptoms. ITS sequencing of fungi can be used as a diagnostic reference. As *A. pullulans* is a common fungus in environment, amplification of ITS sequence of *A. pullulans* in the aseptic body fluid would be necessary to make a comprehensive diagnosis based on the clinical symptoms and signs.

Key words: *Aureobasidium pullulans*; fungal infection; internal transcribed spacer (ITS) sequencing.

J Infect Dev Ctries 2019; 13(12):1174-1179. doi:10.3855/jidc.11830

(Received 09 July 2019 – Accepted 29 October 2019)

Copyright © 2019 Liu *et al.* This is an open-access article distributed under the Creative Commons Attribution License, which permits unrestricted use, distribution, and reproduction in any medium, provided the original work is properly cited.

Introduction

Fever of unknown origin (FUO) refers to a fever at a temperature of 38.5°C lasting for more than 3 weeks, the pathogenesis of which is still not clear even after detailed history, physical examination and routine laboratory tests. The factors of bacterial and fungal infection have been recognized as the main cause of FUO [1]. Fungi can cause opportunistic infection in people with immunodeficiency and immunosuppression, with the presence of FUO in its several presentations [2]. Melanized fungi have been increasingly recognized as important pathogens [3]. *Aureobasidium pullulans* (*A. pullulans*) is a black yeast-like species producing the biodegradable extracellular polysaccharide pullulan (poly- α -1, 6-maltotriose). *A. pullulans* could be found in soil, rocks, wood and household dust, which could colonize human hair and skin [4]. However, human infection of *A. pullulans* is commonly rare, and only one case of skin infection has been reported in mainland China [5], which is not a deep infection. Importantly, *A. pullulans* can reproduce on the surface of implanted medical devices. A previous

study has reported two cases of sepsis caused by the intravenous catheter infection of *A. pullulans* in Taiwan, China [6]. Diagnosis of *A. pullulans* infection is always difficult, taking a long time, which generally depends on the fungal culture. On the other hand, molecular diagnosis makes a more rapid method. The rDNA internal transcribed spacer (ITS) region is one of the most often analyzed DNA regions for this fungus. The rDNA ITS region is rather conserved for *A. pullulans* [7] and therefore useful for the identification at the species level. For the subspecific differentiation, analysis of more variable DNA loci would be necessary [8]. In this study, a case of *A. pullulans* infection diagnosed by ITS sequencing were reported. Moreover, the patient's living environment was investigated, and the fungal samples were collected and subjected to gene tracing.

Case report

The patient, a 27-year-old rural woman, was previously healthy, pregnant 1 years ago and bearing a child. On February 21, 2018, after overwork for 2 days,

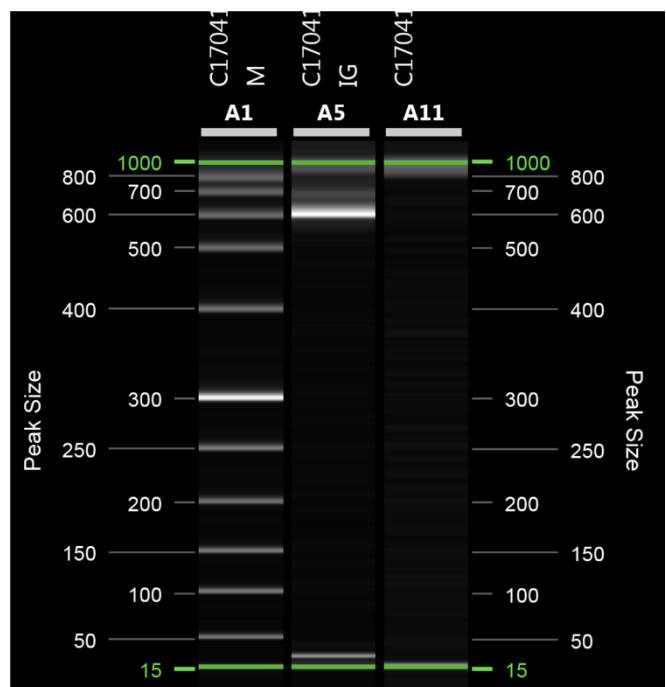
she had a fever at night, with the temperature of 38.5°C, as well as rash, intermittent cough and white mucus sputum. The subject was first admitted to Baoji Hospital of Traditional Chinese Medicine, where the upper respiratory tract infection was diagnosed, and the treatments with ibuprofen and roxithromycin were ineffective. She subsequently developed limb joint pain (mainly in the metacarpophalangeal, knee and ankle joints), and the body temperature reached 39.7°C. On March 1, the subject was admitted to Baoji People's Hospital. Results of the blood routine examination were as follows: White Blood Cells (WBC), $5.3 \times 10^9/L$; neutrophils, 84.0%; and procalcitonin (PCT), 1.04 ng/mL. Levofloxacin, moxifloxacin, Lianhua Qingwen Capsule, oseltamivir, ibuprofen and/or other treatments were ineffective. The highest body temperature was 40.0°C. Results of the blood routine examination on March 10 were as follows: routine WBC, $11.0 \times 10^9/L$; neutrophils%, 90.8%; and PCT, 0.444 ng/mL. The bone marrow aspiration indicated infectious bone marrow. On March 13, the subject was admitted to the Emergency Department of the First Affiliated Hospital of Xi'an Jiaotong University. The blood routine examination indicated: the WBC, $18.17 \times 10^9/L$; neutrophils%, 92.0%; and PCT, 0.626 ng/mL. She received hospitalization based on *fever to be investigated for septic shock*. There was still intermittent fever, with the body temperature up to 40.0°C. After the anti-infection treatment of meropenem, linezolid, voriconazole, Shupu deep, and doxycycline, the subject's body temperature, blood indexes, and PCT were gradually decreased. On March 29, the subject developed abdominal pain and diarrhea. The blood pressure was reduced to 60/29 mmHg, and the results from the blood gas analysis indicated pH 7.37, with 12 mmol/L HCO_3^- and 5 mmol/L Lac. Based on these results, septic shock was considered. On April 1, the subject was transferred to the ICU for anti-infection, acidosis correction and liver protection. Thereafter, the infection indexes were gradually decreased to normal levels, however still with intermittent fever. The subject was administered with A Qianglong to inhibit the inflammation. CT examination showed bilateral pleural effusion, pericardial effusion, mediastinal and bilateral axillary lymph node enlargement, peritoneal effusion, hepatomegaly, and splenomegaly. No fungal hyphae, spores, or acid-fast bacilli were found under the tracheal brush microscope. Liver function tests indicated the elevated transaminase level and reduced albumin level. Moreover, the procalcitonin level was increased. On April 13, the bone marrow aspiration smears were taken, and the results

suggested suspiciousness of kala-azar. The bone marrow specimens were sent to our laboratory for testing, i.e., the Shaanxi Provincial Center for Disease Control and Prevention.

The patient's bone marrow smear was stained with the *Wright's* staining. Under the oil microscope, no *Leishmania* or yeast-like structure was observed in macrophages. Moreover, serum *Leishmania* rK39 immunochromatographic test strips (Inbios International, Seattle, WA, US) or *Leishmania* IgG ELISA (DRG, Marburg, Germany) showed negative results. Furthermore, there was no colony growth in the bacterial culture and fungal biphasic culture for 15 days. DNA was extracted from the patient's bone marrow by the Dneasy Blood & Tissue Kit (Cat. No., 69504; Qiagen, Hilden, Germany). PCR was performed with the *Leishmania*- [9], *Histoplasma capsulatum*- [10] and *Penicillium marneffeii*-specific [10] primers, respectively, and no specific bands were observed. Moreover, the 16S rDNA V3 [11] amplification showed negative results.

A fragment of rDNA was amplified with the ITS1 and ITS4 primers [12], and a positive band was detected by the QIAxcel Advance Capillary Electrophoresis (Qiagen, Hilden, Germany) (Figure 1). The amplified products were spliced and subjected to the bidirectional sequencing with SeqMan Pro 7.1.0 (Lasergen, <https://www.dnastar.com/>), obtaining a 583 bp

Figure 1. ITS sequence PCR amplification electrophoresis.



A1: DNA ladder; A5: Patient's bone marrow; A11: Negative control.

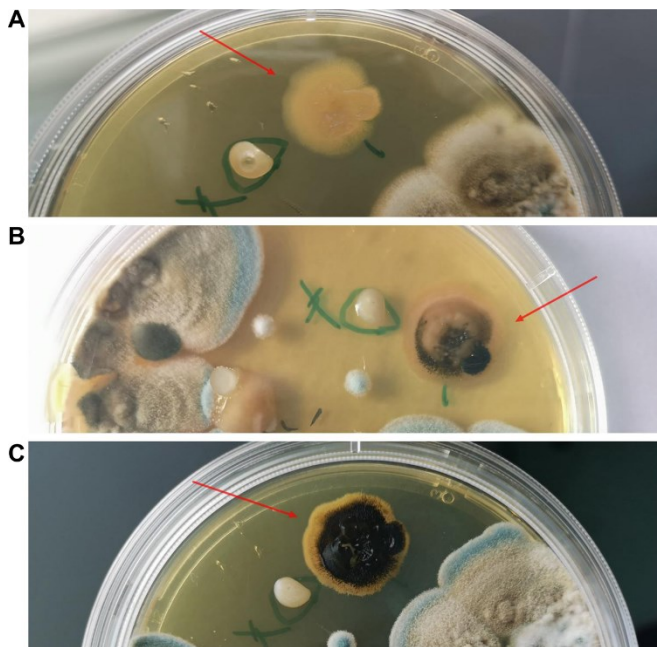
sequence (Accession No. MK772063) which was named as *LiRui* isolate. The sequences were aligned in the BLASTN 2.8.0+ (<http://blast.ncbi.nlm.nih.gov>) and the fungal sequence database MycoBank (<http://www.mycobank.org/>), both indicating *Aureobasidium pullulans*.

The patient was treated with amphotericin B and hormonal drugs. On May 2, the body temperature dropped to the normal level, with no fever. Tests showed that all indicators had been improved. The subject was discharged on May 13.

After discharge, the patient was kept in touch. In the winter of 2018, the patient’s husband reported that the house where they lived was damp, with a lot of mildew spots on the wall before the disease onset. The same mildew appeared in the very winter, which was suspected to be related to the patient’s infection. On February 28, 2019, we came over to the patient’s house and investigated the environment where she lived. The patient lived on the 10th floor of an 11-floor building. The house faced south, which was, however, not well ventilated and humid. The corner between the bedroom wall and ceiling was covered with mildew spots, and mildew spots were also observed in the cabinet under the windows.


Samples were collected from six mould spots and kept in saline solution, which were inoculated on salicylic glucose agar and cultured at 28°C with 60% relative humidity. After 3 days, DNA was extracted

Figure 2. *A. pullulans* growing on SDA plate.



(A) 9 days. (B) 19 days. (C) 25 days.

Figure 3. ITS sequence alignment of *Aureobasidium pullulans* isolates LiRui, BJ2019 and ATCC 15233.



from 12 yeast-like colonies, followed by identification with ITS1 and ITS4 amplification and sequencing. One colony sample from the wood cabinet (named *BJ2019*) was identified as *Aureobasidium pullulans* (Accession No. MK772062). After 19 days, the *A. pullulans* colony in the Sabouraud Dextrose Agar (SDA) plate turned black (Figure 2). The strain was inoculated in the SDA medium (without NaCl, containing 10% and 15% NaCl, respectively), which was cultured at 30°C and 35°C. The results showed that the strain could grow at 30°C, in 15% NaCl, which however could not grow at 35°C.

The homology was analyzed and compared between the isolated strains and the bone marrow samples, and correlation was confirmed between the broken strain suspension and the patient’s serum agglutination. However, the strain had self-agglutinating phenomenon, which therefore could not be confirmed. Totally 5 gene loci [multilocus analyses of rDNA internal transcribed spacers (ITS), partial large subunit of rDNA (LSU), and partial introns and exons of genes coding β -tubulin (*TUB*), translation elongation factor (*EF1 α*) and elongase (*ELO*)] [8] of the environmental strain *BJ2019*, standard strain *ATCC15233* and bone marrow sample *LiR* were amplified by PCR. Our results showed that only the ITS sequence was successfully amplified in the bone

marrow samples, while the other 4 loci failed the amplification. Aligned *ATCC15233* (Accession NO. MK772064), case sample (*LiR*) and environmental sample (*BJ2019*) were analyzed using the MegAlign 7.01 by the ClustalW method. Our results showed identical ITS sequences for the *LiRui* and *BJ2019* isolates. The bases of *ATCC15233* at 107, 108, 189, 394 and 500 sites were T, C, T, T, and T. *A. pullulans LiRui* and *BJ2019* were C, T, A, C, and C. *ATCC15233* had the A and T bases at the 174 and 511 sites, which were deleted at these sites for the *LiRui* and *BJ2019* (Figure 3). The environmental isolate *BJ2019* was completely identical to the ITS sequence of the patient *LiRui* isolate. It was possible that the patient was infected with *A. pullulans* from the wall of the house, causing a series of infection symptoms mainly due to the repeated fever.

Discussion

The patient underwent 3 months from the disease onset to diagnosis. During this period, the patient was examined and treated in various hospitals, with repeated conditions. High PCT values were detected, which were in accordance with the systemic infection, and the bacterial and fungal infections had been considered. For the diagnosis, routine bacterial culture and fungal culture were performed out of many specimens. Bone marrow DNA was extracted and amplified with the PCR primers of *Leishmania*, *Penicillium marneffeii* and *Histoplasma capsulatum*. Results from the IgG antibody test and rK39 test paper antibody test indicated negative findings.

Under the use of antibiotics and immunomodulators, it is often difficult to obtain infectious pathogens. Gene amplification diagnosis and metagenomic sequencing technology can provide important reference for the diagnosis of infectious diseases. In recent years, the molecular diagnosis has been increasingly applied in the clinical diagnosis of pathogenic microbial infections. Bacterial 16S rDNA and fungal ITS universal primers have been commonly used for identifying the strains. Bone marrow and blood samples have been generally considered to be aseptic body fluids. The positive amplification would be of great reference value for infectious diseases [11]. The ITS in the fungal ribose is conservative, which has been widely used in the identification of the fungal species and the phylogenetic researches [13]. ITS sequence (ITS1-ITS4) amplification products of different fungi vary between 500-800 bp, and the fungal sequences could be identified by comparing the corresponding databases [12]. In the reported case, the bone marrow specimen DNA was amplified and sequenced by the

ITS sequence, and *A. pullulans* was identified according to the WEB Blast and Mycobank databases. *A. pullulans* is a ubiquitous yeast-like fungus in the environment, which could be found in soil, water, air and even in human nail crevices. *A. pullulans* is considered to be an allergen [14], which has been reported to cause asthma [15] and allergic pneumonia [16], as well as fungal dermatitis [17] and fungal keratitis [18]. Moreover, it is also an opportunistic infectious fungus, causing an infective abscess in various organs, systemic disseminated infection and fungal sepsis [19]. Morais OOD reported a case of a patient with infection of the lymphatic system by *A. pullulans* [20]. The latest report on *A. pullulans* infection is a case of co-infection of AIDS patients in 2018 [21]. It is generally believed that systemic infection is associated with immunodeficiency or the use of immunosuppressive agents [22]. Although the DNA fragment amplification of pathogenic bacteria from the bone marrow specimens had certain diagnostic reference value, it was possible that the contaminated specimens may cause false-positive amplification due to the widespread presence of *A. pullulans* in environment. In addition, the disease course of the case was longer than 3 months, during which the repeated fever, and short-term mycotic primary infection or secondary infection could not be judged. The molecular diagnosis of this study combined with epidemiological history and clinical symptoms, and after fungal treatment, the patient recovered. It is confirmed that the method of amplification and sequencing of aseptic body fluid samples such as bone marrow can diagnose the infection of pathogens. Fungal infections usually occur in people with impaired immunities. This patient was pregnant and delivered, one year before the disease onset, living in a poorly ventilated and humid environment, which might induce the immune decline (even though without corresponding evidence). On-site investigation showed that there were many large mildew spots on the walls of the family's two bedrooms, as well as the kitchen cabinets under the floating windows. A strain of *A. pullulans* was isolated and identified from the kitchen cabinet samples. We tried to confirm the homologous relationship between these kitchen cabinet strains. There are many methods to identify the fungal homology [23], including the PFGE, MALDI-TOF, and high-throughput whole-genome sequencing [24], mainly based on the isolated strains, DNA samples obtained from the unmixed cultures. It would be more suitable to use the one-generation sequencing method. However, there are many inhibitory PCR components in the nucleic acids

extracted from the clinical specimens, which are difficult for the successful amplification. Moreover, we tried to confirm the homologous relationship between the cabinet strain and the strain from the patient by sequencing at 5 sites [8]. Our results showed that only the ITS sequence was successfully amplified, while the other bone marrow samples failed the amplification. The sequence was identical to the environmental sample BJ2019, while the sequence of the standard *A. pullulans* strain ATCC15233 was different. The ITS sequence of the fungus isolated from the environment was homologous to that of the patient's bone marrow, which further confirmed that the pathogen causing fever in the patient was *A. pullulans*. There are two varieties of human pathogens [3]. One is *A. pullulans* var. *melanigenum*, which can grow at 35°C and tolerate 10% NaCl (ATCC15233 is the representative strain), and the other is *A. pullulans* var. *pullulans*, which can tolerate 15% NaCl at 30°C. The strain isolated from the kitchen cabinet turned black within 19 days, which could grow at 30°C rather than 35°C. Therefore, the strain should be *A. pullulans* var. *pullulans*.

Conclusion

In this paper, a case of fever of unknown origin was diagnosed by molecular diagnosis. Several clinical results suggest that the patient had an infectious disease. No positive results were obtained by bacterial culture, fungal culture or virus detection. Finally, we amplified the bone marrow samples of patient by using the universal primers of fungus ITS and sequenced the positive sequence, which confirmed that the pathogen of infection was *Aureobasidium pullulans*. A strain of *Aureobasidium pullulans* was also isolated from the living environment of the patient. The ITS sequence of the strain was the same as that of the patient's bone marrow, which confirmed that the infection might come from the wet bedroom where the patient lived. These findings suggest that for cases of unexplained fever caused by rare pathogens, fungal or bacterial universal primer PCR could be conducted to amplify and sequence the sterile body fluid samples, which might contribute to the quick identification of the pathogens.

Acknowledgements

This work was supported by the Shaanxi Science Technology Resources Sharing Platform (No. 2016FWPT-12) and the Scientific Technological Research Projects for Social Development in Shaanxi Province (No. 2016SF-051).

Ethics approval and informed consent

Prior written and informed consent was obtained from the patient and the study was approved by the ethics review board of Shaanxi Provincial Center for Disease Control and Prevention.

References

- Zhai YZ, Chen X, Liu X, Zhang ZQ, Xiao HJ, Liu G (2018) Clinical analysis of 215 consecutive cases with fever of unknown origin: A cohort study. *Medicine (Baltimore)* 97: e10986.
- Mendez-Tovar LJ, Manzano-Gayosso P, Cumplido-Urbe C, Hernandez-Hernandez F, Ramos-Hernandez J, Lopez-Martinez R (2012) Invasive mycosis, immunocompromise and fever of unknown origin. *Rev Med Inst Mex Seguro Soc* 50: 609-614. [Article in Spanish]
- Revankar SG, Sutton DA (2010) Melanized fungi in human disease. *Clin Microbiol Rev* 23: 884-928.
- Oliveira LR, Moraes-Souza H, Maltos AL, Santos KC, Molina RJ, Barata CH (2013) *Aureobasidium pullulans* infection in a patient with chronic lymphocytic leukemia. *Rev Soc Bras Med Trop* 46: 660-662.
- Zhang ZY., Lian CH. (2015). A case of deep skin mycosis caused by *Aureobasidium pullulans*. In Qin WZ., Wen H. (ED.), 2015 National Academic Conference on Integrative Medicine for Dermatovenous Diseases (pp 183), Beijing, China: Chinese society of integrated traditional and Western Medicine.[Article in Chinese]
- Huang YT, Liaw SJ, Liao CH, Yang JL, Lai DM, Lee YC, Hsueh PR (2008) Catheter-related septicemia due to *Aureobasidium pullulans*. *Int J Infect Dis* 12: e137-e139.
- Prasongsuk S, Sullivan RF, Kuhirun M, Eveleigh DE, Punnapayak H (2005) Thailand habitats as sources of pullulan-producing strains of *Aureobasidium pullulans*. *World J Microbiol Biotechnol* 21: 393-398.
- Zalar P, Gostincar C, de Hoog GS, Ursic V, Sudhadham M, Gunde-Cimerman N (2008) Redefinition of *Aureobasidium pullulans* and its varieties. *Studies in mycology* 61: 21-38.
- Costa CHN, Stewart JM, Gomes RBB, Garcez LM, Ramos PKS, Marcelo B, Abhay S, Senarath D, Santos RS, Silva MRB (2002) Asymptomatic human carriers of *Leishmania chagasi*. *Am J Trop Med Hyg* 66: 334.
- Lobuglio KF, Taylor JW (1995) Phylogeny and PCR identification of the human pathogenic fungus *Penicillium marneffeii*. *J Clin Microbiol* 33: 85.
- García-Gudiño I, Yllescas-Medrano E, Maida-Claros R, Soriano-Becerril D, Díaz NF, García-López G, Molina-Hernández A, Flores-Herrera O, Peralta-Pérez MDR (2017) Microbiological comparison of blood culture and amplification of 16S rDNA methods in combination with DGGE for detection of neonatal sepsis in blood samples. *Eur J Pediatr* 177: 1-9.
- White TJ, Bruns T, Lee S, Taylor J (1994) Amplification and direct sequencing of fungal ribosomal RNA genes for phylogenetics. In: Innis MA (ed) PCR Protocols. San Diego: Academic Press. 315–322.
- Zhao Y, Tsang CC, Xiao M, Cheng JW, Xu YC, Lau S, Woo P (2015) Intra-genomic internal transcribed spacer region sequence heterogeneity and molecular diagnosis in clinical microbiology. *Int J Mol Sci* 16: 25067-25079.
- Al-Doory Y. (1984) Airborne fungi. In: Al-Doory Y, Domson JF, eds. Mould Allergy. Philadelphia: Lea & Febiger 27-40p.

15. Niedoszytko M, Chełmińska M, Jassem E, Czestochowska E (2007) Association between sensitization to *Aureobasidium pullulans* (*Pullularia* sp) and severity of asthma. *Ann Allergy Asthma Immunol* 98: 153-156.
16. Engelhart S, Rietschel E, Exner M, Lange L (2009) Childhood hypersensitivity pneumonitis associated with fungal contamination of indoor hydroponics. *Int J Hyg Environ Health* 212: 18-20.
17. Pikazis D, Xynos ID, Xila V, Velegaki A, Aroni K (2010) Extended fungal skin infection due to *Aureobasidium pullulans*. *Clin Exp Dermatol* 34: e892-e894.
18. Viney G, Rohan C, Seema S (2001) *Aureobasidium pullulans* scleritis following keratoplasty: A case report. *Ophthalmic Surg Lasers* 32: 481-482.
19. Njambi S, Huttova M, Kovac M, Freybergh PF, Bauer F, Muli JM (2007) Fungal neuroinfections: rare disease but unacceptably high mortality. *Neuro Endocrinol Lett* 28 Suppl 2: 25-26.
20. Morais OOD, Porto C, Coutinho ASSL, Reis CMS, Teixeira MDM, Gomes CM (2011) Infection of the lymphatic system by *Aureobasidium pullulans* in a patient with erythema nodosum leprosum. *Braz J Infect Dis* 15: 288-292.
21. Mittal J, Szymczak WA, Pirofski LA, Galen BT (2018) Fungemia caused by *Aureobasidium pullulans* in a patient with advanced AIDS: a case report and review of the medical literature. *JMM Case Reports*. 5: e005144.
22. Ibañez Perez R, Chacón J, Fidalgo A, Martín J, Paraiso V, Muñoz-Bellido JL (1997) Peritonitis by *Aureobasidium pullulans* in continuous ambulatory peritoneal dialysis. *Nephrol Dial Transplant* 12: 1544-1545.
23. Zheng B, Yao DT, Ying CM (2011) Research progress of molecular typing methods of fungus. *J. Shanghai Jiao Tong Univ* 31: 1475-1480. [article in Chinese]
24. Ma S, Chao A, Xue W, Shangguan Y (2016) Deep sequencing-based transcriptome analysis of *Aureobasidium pullulans*. *Genomics and Applied Biology* 5: 1-10. [article in Chinese]

Corresponding author

Changhong Liu, PhD

Department of Pathogenic Microbiology Institute, Shaanxi Provincial Center for Disease Control and Prevention, No. 3, Jiandong Street, Xi'an 710054, Shaanxi, China.

Tel: 86-2982229105

Fax: 86-2982229105

Email: sxbio@qq.com

Conflict of interests: No conflict of interests is declared.