

Brief Original Article

Blackleg in inadequately immunized calves and their recovery following antibiotic therapy

Carolina C Guizelini¹, Otávio AC Silvestre², Carlos AN Ramos³, Danilo C Gomes², Ricardo AA Lemos²

¹ Faculdade de Medicina Veterinária e Zootecnia (FAMEZ), Universidade Federal de Mato Grosso do Sul (UFMS), MS, Campo Grande, Brazil

² Laboratório de Anatomia Patológica, Faculdade de Medicina Veterinária e Zootecnia (FAMEZ), Universidade Federal de Mato Grosso do Sul (UFMS), MS, Campo Grande, Brazil

³ Laboratório de Biologia Molecular, Faculdade de Medicina Veterinária e Zootecnia (FAMEZ), Universidade Federal de Mato Grosso do Sul (UFMS), MS, Campo Grande, Brazil

Abstract

Introduction: There is consensus regarding the importance of blackleg vaccination as a preventive measure, and proper immunization protocols are available. However, few studies have evaluated the effectiveness of vaccine protection against *Clostridium chauvoei* and the treatment of the disease in calves exhibiting early or advanced clinical courses. This study describes twelve blackleg cases in unvaccinated calves and in calves that received a single dose of the vaccine. It also reports the recovery of some calves after antibiotic therapy.

Methodology: Two necropsies of cattle dead from blackleg were performed. Fragments of skeletal muscle from these two cattle were immersed in paraffin for multiplex polymerase chain reaction (PCR) analysis.

Results: Twelve calves up to nine months of age developed signs of blackleg and eight died. Ten of those 9-month-old calves had received only the first dose of a blackleg vaccine at 4 months of age, but no booster. The last two affected calves belonged to a herd that had never been vaccinated. Four out of five calves treated with penicillin for 6-7 days recovered from the disease. The diagnosis of blackleg was based on necropsy, histopathological findings and detection of *C. chauvoei* in skeletal muscle samples of two necropsied calves using PCR.

Conclusions: The occurrence of cases only in calves that did not receive a booster dose or were not vaccinated indicated that the vaccine used was effective when performed as recommended by the manufacturer. However, neglecting the booster resulted in casualties due to blackleg.

Key words: *Clostridium chauvoei*; cattle disease; clostridial disease; blackleg; immunization.

J Infect Dev Ctries 2020; 14(7):788-792. doi:10.3855/jidc.12613

(Received 03 March 2020 – Accepted 21 April 2020)

Copyright © 2020 Guizelini *et al.* This is an open-access article distributed under the Creative Commons Attribution License, which permits unrestricted use, distribution, and reproduction in any medium, provided the original work is properly cited.

Introduction

Blackleg is caused by histotoxins of *Clostridium chauvoei*, an anaerobic spore-forming bacterium. It is primarily a disease of cattle with characteristic lesions of hemorrhagic and emphysematous necrotic myositis and myocarditis [1-5]. Vaccination against blackleg is recommended for 3-6-month-old calves, followed by a booster dose within 30 days, and annual revaccination until cattle reach three years of age [6]. However, in large herds held in extensive areas, farming can be a demanding operation in which booster doses may be neglected, increasing the risks of blackleg to occur [5,7].

An alternative vaccination protocol which grants and adequate protection against blackleg is to vaccinate calves at 4 and 8 months of age. In general, the second (booster) dose will coincide with the weaning season [7].

There is common knowledge about the importance of vaccination in protecting cattle from blackleg, and the vaccination protocols available are considered effective [6,8,9]. Nevertheless, few studies evaluate the efficacy of immunization against *C. chauvoei* [4] or the treatment of cattle that show early and advanced clinical signs [10].

This study describes cases of blackleg in unvaccinated calves and calves vaccinated with a single dose. Additionally, we describe the recovery of some of these calves after treatment with penicillin and steroidal anti-inflammatory drugs.

Methodology

The data from the cases were gathered during an on-site visit to the affected property and interviewing the attending veterinarian.

One blackleg affected calf (Calf 1) was referred to the Veterinary Teaching Hospital at the Universidade

Federal de Mato Grosso do Sul (HV-UFMS). Due to poor prognosis, the calf was euthanized and necropsied. Another affected calf (Calf 2) was found dead at the premises and necropsied during a visit to the farm. Thorough necropsies and tissue sampling were performed according to published recommendations [11]. Fragments of several organs from both necropsied calves were sampled and fixed in 10% formalin. They were routinely processed for histopathology and stained with hematoxylin and eosin. Fragments of quadriceps femoris and masseter skeletal muscles were sampled respectively from Calves 1, and 2 from areas of characteristic blackleg lesions. These fragments were immersed in 56°C paraffin to maintain an anaerobic environment [10]; they were then refrigerated at 5°C for 20 days after which were analyzed for *C. chauvoei* and *C. septicum* using multiplex PCR techniques [12].

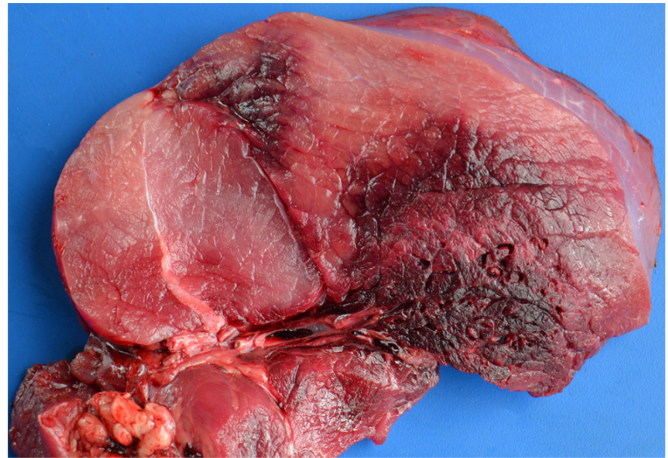
Calves with clinical signs of blackleg were treated with 2-6,000,000 UI/calf of penicillin (Pencivet® Plus, Merck Animal Health, Millsboro, USA) and 0.11 mg/kg of dexamethasone (Azium®, Merck Animal Health, Millsboro, USA).

Results

The cases of blackleg occurred in a farm, in which there 2.339 Nelore calves and 12 dairy calves of Girolando breed. These cattle were maintained in four holdings, identified here as Holdings 1-4 (Table 1). Calves were nine-month-old except for those in Holding 4 that were 5-7-month old. Different erratic vaccination protocols against blackleg were applied to the calves but always using the same commercial polyvalent vaccine consisting of *C. chauvoei*, *C. botulinum*, *C. perfringens*, *C. septicum*, *C. novyi* and *C. sordelii* strains. Except for the calves at the Holding 3, all calves received the first dose of the vaccine at four months of age. The booster dose was scheduled for four months later, at the weaning season; however, this was done only in calves of Holding 2.

Twelve calves were affected by blackleg in Holding 1 and two in Holding 3. No calves were affected in Holdings 2 and 4.

Figure 1. Blackleg in cattle. Skeletal muscle. There are focal extensive dark areas of focal extensive hemorrhagic and emphysematous necrosis.



After the first diagnosis of blackleg, all of the other calves in the four holdings were vaccinated against blackleg.

Five calves affected by blackleg (four in Holding 1 and two in Holding 3) were treated for 6-7 days with penicillin and dexamethasone as described in the Methodology section. Four calves in Holding 1 recovered. As there were 2.531 calves at risk (considering the four holdings together), the morbidity, mortality, and lethality rates were respectively 0.51%, 0.34%, and 66.6%.

Observed clinical signs in blackleg affected cattle included stagger, apathy, stiff limbs with compromised locomotion, evolving to decubitus and death within two days of the onset of the clinical signs; large muscle groups were swollen and crepitating. Two calves were found dead without premonitory signs. One calf (Calf 1) was necropsied at HV-UFMS and another (Calf 2) at the farm.

In the necropsy of Calf 1 the gross lesions in the skeletal muscles were marked and observed on the right quadriceps femoris, semimembranosus, gracilis, popliteal, and diaphragm. Muscle lesions consisted of focal extensive crepitating dark red or black areas permeated by varying-sized gas bubbles, edema, and hemorrhage (Figure 1). Such affected areas exhaled a

Table 1. Calves at risk of contracting blackleg as distributed in their holdings, their vaccination schedules, and the morbidity and mortality per holding.

Holding	Number of calves in the holding	Breed	Vaccination at 4 months of age	Second dose 4 months later	Number of calves affected by blackleg	Number of affected calves that died
1	119	Nelore	Yes	No	12	8
2	600	Nelore	Yes	Yes	None	None
3	12	Girolando	No	No	2	2
4	1,620	Nelore	Yes	No	None	None

strong butyric odor. The thoracic cavity contained a moderate amount of serosanguinous fluid containing floating fibrin clots. The visceral pleura was covered by a fibrin film (Figure 2) that loosely adhered to multiple foci of the visceral to parietal pleura. The pericardial sac (Figure 3) was distended by moderate fluid containing fibrin.

In the necropsy of Calf 2, the muscular lesions were similar but mild affecting skeletal muscles of the dorsal, flank areas, and the masseter. The large muscle groups of the limbs were spared.

Microscopically, the myofibers were hyper eosinophilic and moderately swollen (hyaline necrosis); the perimysium and endomysium were somewhat expanded by a faint eosinophilic material (edema) rich in fibrin (Figure 4). In addition to necrosis, there was extensive hemorrhage, multiple discrete vacuoles (gas bubbles), and a few aggregates of strongly basophilic bacilli. Occasionally, the tunica media and tunica adventitia of arterioles were moderately distended by the deposition of fibrillar, acellular, and highly eosinophilic material (fibrinoid necrosis).

C. chauvoei was identified by PCR analysis from several fragments of quadriceps femoris muscle of Calf 1 and several fragments of masseter muscle of Calf 2.

Discussion

The diagnosis of blackleg was based on the clinical, epidemiological, and anatomopathological findings. Those were similar to characteristic results reported elsewhere for the disease [3,5,6]. The diagnosis was further confirmed by PCR analysis of skeletal muscle

Figure 2. Blackleg in cattle. Thoracic cavity. The right hemithorax is filled with a serosanguinous fluid admixed with fibrin. Fibrin clots are over multiple spots on the pleura. The pericardial sac is distended by fluid and fibrin (arrow).

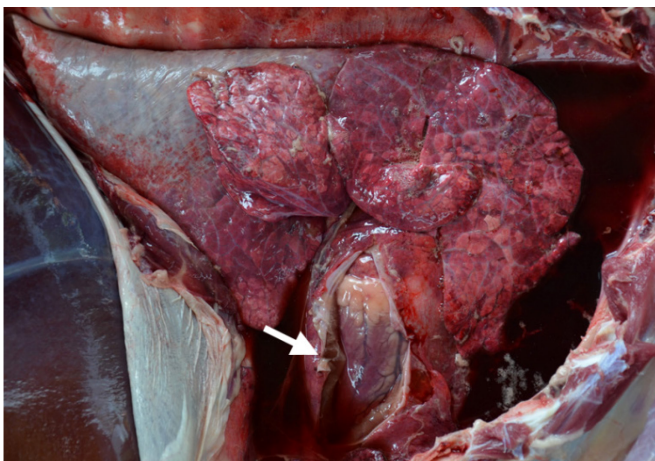
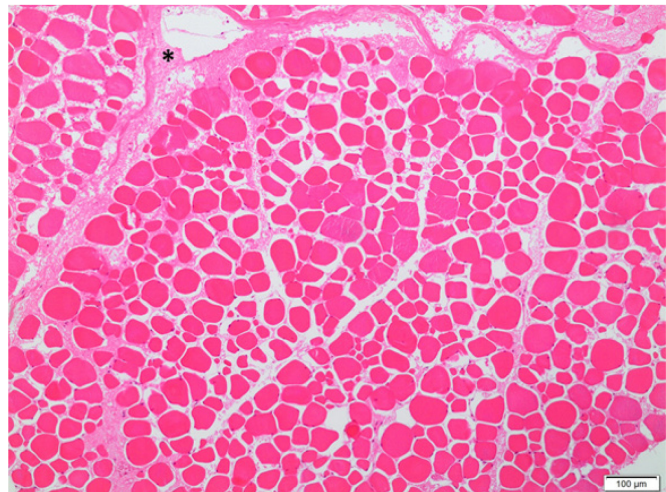


Figure 3. Blackleg lesions in cattle. Big clots of fibrin are on multiple areas of the epicardium, associated with numerous small foci of hemorrhage.

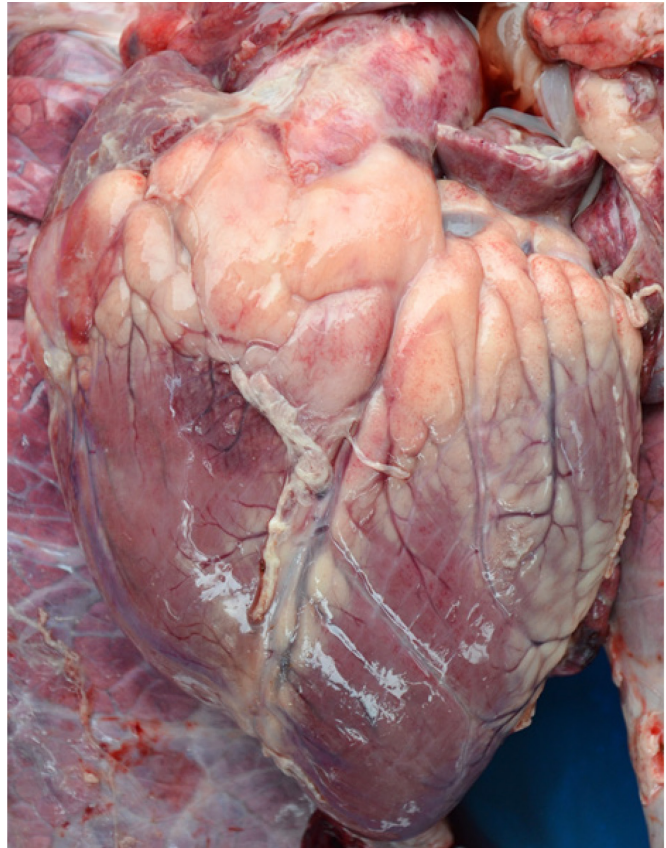

Figure 4. Blackleg in cattle. Skeletal muscle. The myofibers are hyper eosinophilic and moderately swollen (hyaline necrosis). The space between the fibers is somewhat expanded by a faint pink material, which is edema rich in fibrin (asterisk) with some erythrocytes. Hematoxylin and eosin, 10X.



samples from Calves 1 and 2. *C. chauvoei* DNA amplification is an excellent alternative to prove the agent due to the difficulty of its isolation via microbiological culture [4,13].

The characteristic necro-hemorrhagic and emphysematous myositis [9,10] was observed in both necropsied calves; however, they differ in location and severity. In contrast to Calf 1, in which the large muscular groups were severely affected, muscular lesions were mild in Calf 2 and spared the large muscle groups of the limbs. Also, the fibrinous pleuritis and pericarditis observed in Calf 1 were absent in Calf 2. This finding demonstrates the importance of a detailed necropsy for an accurate diagnosis since lesions are not always conspicuous and prone to be neglected. An early diagnosis based upon gross lesions was critical in controlling the disease since it allowed the identification and treatment of sick animals in early clinical stages, resulting in the complete recovery of four calves. A delay in diagnosis is a potential cause of substantial losses, whereas an early diagnosis prompts the adoption of preventive measures and treatment of sick animals [3].

Affected calves were in the age range of blackleg occurrence [10]. Most of the calves were vaccinated with a single dose when 4-month-old, without the recommended booster, four months after that. However, there are pieces of evidence suggesting that a protocol of vaccination at four months of age with a booster at eight months of age induces a satisfactory immunization against blackleg in cattle [7].

In the current study, blackleg occurred only in calves that were not vaccinated with a booster dose, or that were not vaccinated at all. Also, there were no cases of blackleg in calves vaccinated at four and eight months of age, according to a recommended protocol [7]. These data suggest that the vaccine used on this farm is an efficient prophylactic tool when the correct vaccination protocol is applied.

Although vaccination against blackleg is a common practice, there are few studies on vaccine efficacy [14]. In a previous study including 59 cases of the disease [10], only two affected calves had correctly been vaccinated. In one farm, vaccinated and unvaccinated calves were kept in the same pen, and only the latter were stricken by blackleg. This data reinforces the importance of a correct vaccination.

The pathogenesis of blackleg initiate by the ingestion of bacterial spores that are absorbed in the intestine to the bloodstream and distributed to the skeletal musculature; there, they remain latent until there is local hypoxia caused by blunt trauma. The

decreased oxygen level favors spore germination and proliferation, with the production of virulence factors [4]. Considering this, when cattle live in areas where there is disseminated contamination of *C. chauvoei*, vaccination is the only means to prevent the disease [4]. This assertion is reinforced by the occurrence of blackleg in dairy calves that did not have any contact with the sick calves from other holdings.

Five calves were treated, and four recovered. Although, in the majority of cases, blackleg exhibits a lethality rate near 100% [8], such lethality did not occur in the cases of this study. Four calves diagnosed early in the clinical course of blackleg experienced full recoveries, while the one that died despite treatment was diagnosed in an advanced clinical stage, corroborating the assertion that successful treatment depends on an early diagnosis [8].

In our therapy trials, clinical signs continued for up to seven days, and the treatment had to be maintained until complete recovery, to prevent relapses. After curative treatment was achieved in some sick calves, penicillin was administered to all calves in the affected holding. When cases of blackleg occur, this treatment protocol can be put in place at the moment of vaccination because new cases may keep popping up due to spore activation after trauma inflicted on cattle by management during vaccination [3].

Conclusion

A delay in booster vaccination interferes with the development of immunity in early-weaned calves and can result in mortality from *C. chauvoei* infection. Treatment with penicillin and steroidal anti-inflammatory drugs in calves exhibiting early clinical stages of the blackleg are efficient, as was penicillin administration concomitant with revaccination in healthy cattle from affected lots.

Acknowledgements

This study was partially funded by Coordenação de Aperfeiçoamento de Pessoal de Nível Superior - Brasil (CAPES) – Finance Code 001, by Fundação Universidade Federal de Mato Grosso do Sul – UFMS/MEC – Brazil, and by Fundação de Apoio ao Desenvolvimento do Ensino, Ciência e Tecnologia do Estado de Mato Grosso do Sul. One of the authors (Ricardo A. A. Lemos) has a fellowship from Conselho Nacional de Desenvolvimento Científico e Tecnológico (CNPq), Brasil (309074/2018-5).

References

1. Uzal FA, Paramidani M, Assis R, Morris W, Miyakawa MF (2003) Outbreak of clostridial myocarditis in calves. *Vet Rec* 152: 134-136. doi: 10.1136/vr.152.5.134.

2. Useh NM, Adamu S, Ibrahim N, Nok AJ, Esiebo KAN (2010) Outbreaks of blackleg of cattle in northern Nigeria. *Slov Vet Res* 47: 39-44.
3. Groseth PK, Ersdal C, Bjelland AM, Stokstad M (2011) Large outbreak of blackleg in housed cattle. *Vet Rec* 169: 1-2. doi: 10.1136/vr.d4628.
4. Abreu CC, Uzal FA (2016) Blackleg. Clostridial histotoxic infections. In: Uzal FA, Songer JG, Prescott JF, Ropoff MR, editors. *Clostridial diseases of animals*. John Wiley & Sons, Iowa. 231-294. doi: 10.1002/9781118728291.ch19.
5. Ziech RE, Gressler LT, Frey J, Vargas AC (2018) Blackleg in cattle: current understanding and future research needs. *Cienc Rural* 48: 1-10. doi: 10.1590/0103-8478cr20170939.
6. Kriek NPJ, Odendaal MW (2004) *Clostridium chauvoei* infections. In: Coetzer JAW, Tustin RC, editors. *Infectious diseases of livestock*. Oxford University Press, Southern Africa, Cape Town. 1856-1862.
7. Araujo RF, Curci VCLM, Nobrega FLC, Ferreira RMM, Dutra IS (2010) Vaccination protocol and bacterial strain affect the serological response of beef calves against blackleg. *Pesq Vet Bras* 30: 554-558. doi: 10.1590/S0100-736X2010000700008.
8. Constable P, Hinchcliff KW, Done S, Gruenberg W (2007) Blackleg. Diseases associated with bacteria II. In: Constable P, Hinchcliff KW, Done S, Gruenberg W, editors. *Veterinary Medicine - A textbook of the diseases of cattle, horses, sheep, pigs and goats*. Saunders Elsevier, Philadelphia. 828-830.
9. Abreu CC, Edwards EE, Edwards JF, Gibbons PM, Araújo JL, Rech RR, Uzal FA (2017) Blackleg in cattle: a case report of fetal infection and a literature review. *J Vet Diag Invest* 29: 612-621. doi: 10.1177/1040638717713796.
10. Heckler RF, Lemos RAA, Gomes DC, Dutra IS, Silva ROS, Lobato FCF, Ramos CAN, Brumatti RC (2018) Blackleg in cattle in the state of Mato Grosso do Sul, Brazil: 59 cases. *Pesq Vet Bras* 38: 6-14. doi: 10.1590/1678-5150-pvb-4964.
11. Strafuss AC (1988) *Necropsy. Procedures and basic diagnostic methods for practicing veterinarians*. Iowa: Springfield 244p. doi: 10.1111/j.1939-165X.1988.tb00498.x.
12. Assis RA, Lobato FCF, Lobato ZIP, Camargos MF, Nascimento RAP, Vargas APC, Salvarani FM, Uzal FA (2008) Multiplex PCR for identification of *Clostridium chauvoei* and *Clostridium septicum*. *Arq Bras Med Vet e Zootec* 60: 294-298. [Article in Portuguese]. doi: 10.1590/S0102-09352008000200003.
13. Assis RA, Lobato FCF, Serakides R, Santos RL, Dias GRC, Nascimento RAP, Abreu VLV, Parreiras PM, Uzal FA (2005) Immunohistochemical detection of Clostridia species in paraffin-embedded tissues of experimentally inoculated guinea pigs. *Pesq Vet Bras* 25: 4-8. doi: 10.1590/S0100-736X2005000100002.
14. Uzal FA (2012) Evidence-based medicine concerning efficacy of vaccination against *Clostridium chauvoei* infection in cattle. *Vet Clin Food Anim* 28: 71-77. doi: 10.1016/j.cvfa.2011.12.006.

Corresponding author

Professor Dr. Ricardo Antonio Amaral de Lemos
 Laboratório de Anatomia Patológica, Faculdade de Medicina Veterinária e Zootecnia, Universidade Federal de Mato Grosso do Sul, Avenida Senador Filinto Muller 2443, Vila Ipiranga, Campo Grande, MS 79074-460, Brazil
 Tel.: +55 (67) 3345-3615.
 E-mail: ricardo.lemos@ufms.br

Conflict of interests: No conflict of interests is declared.