

Case Report

A case of Actinomycotic mycetoma involving the right foot

Ragini Tilak¹, Sanjay Singh², Atul Garg¹, Jaya Bassi¹, Vijai Tilak³, Anil K. Gulati¹

Departments of Microbiology¹, Dermatology², and Pathology³, Banaras Hindu University, Caranasi 221005, U.P., India

Abstract

A 45-year-old male presented with history of multiple swellings over the foot with sinuses discharging seropurulent pus. *Actinomadura madurae* was demonstrated and identified by microbiological culture from the pus obtained directly of the lesion. This case is reported to emphasize the importance of laboratory diagnosis in the management and assessment of the prognosis of such cases.

Key Words: *Actinomadura madurae*, mycetoma

J Infect Developing Countries 2009; 3(1):71-73.

Received 7 July 2008 - Accepted 16 September 2008

Copyright © 2008 Tilak *et al.* This is an open access article distributed under the Creative Commons Attribution License, which permits unrestricted use, distribution, and reproduction in any medium, provided the original work is properly cited.

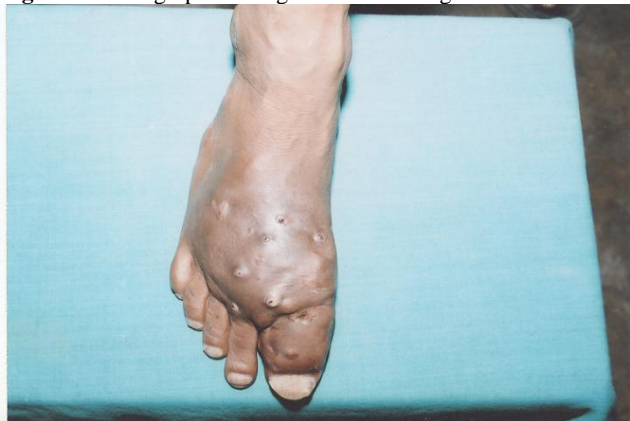Introduction

Mycetoma is a chronic subcutaneous infection caused by actinomycetes or fungi. This infection results in granulomatous inflammatory response in the deep dermis and subcutaneous tissue, which can extend to the underlying bone. Mycetoma is characterized by the formation of grains containing aggregates of the causative organisms that may be discharged onto the skin surface through multiple sinuses. Eumycetoma is more common in northern India [1], while actinomycetoma is common in southern India [2-4]. The tendency of members of the population to walk barefoot, along with predisposing environmental factors for mycetoma including rainfall, temperature, soil and the abundance of thorny sharp vegetable materials which can inoculate etiological agents into the feet, instigate the disease [1-5]. This disease has been reported to respond to sulpha drugs, rifampicin, streptomycin and dapsone.

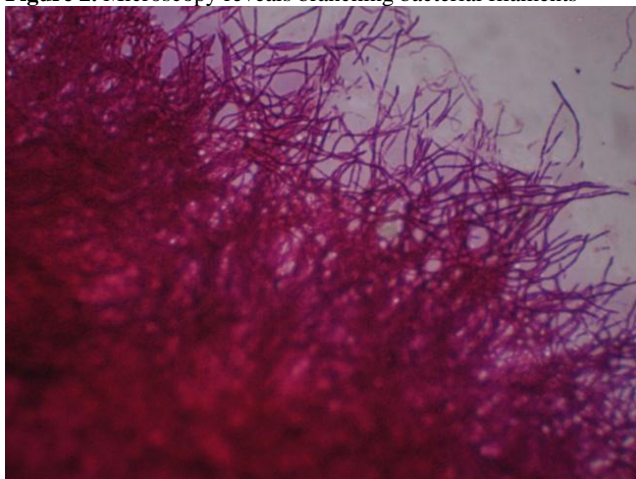
Case Report

A 45-year-old male from eastern Uttar Pradesh was admitted to Sir Sunderlal Hospital, Banaras Hindu University, Varanasi, with history of pain, swelling and discharging sinus in the right foot of fifteen years duration. The initial lesion appeared as a single nodule, which was followed by the

appearance of successive nodules close together. The lesions were distributed mainly on the dorsum surface of the foot. All the nodules showed intermittent discharge for which the patient took an analgesic and antibiotic (Ciprofloxacin). This treatment partially relieved the patient of the discharge; however, the nodules persisted. Over the course of one year, the patient experienced severe pain and swelling at the same site necessitating hospitalization. There was a past history of trauma because the patient had been a football player from 1968 to 1986. On examination, the right foot showed swelling and hardened surface skin with multiple discharging nodules (Figure 1). The regional lymph nodes were not enlarged. Gross examination of the discharge revealed yellow granules. An X-ray of the right foot revealed no bony abnormality. The patient history and physical findings at this point were strongly suggestive of mycetoma. Gram stain revealed gram-positive branching filaments, which were narrow and not fragmenting (0.5-1micrometer) in size. Modified Kinyoun's staining with 1% sulphuric acid was found to be negative. Ziehl Neelsen staining was also negative. Non-acid-fast filamentous branching bacteria were strongly suggestive of actinomycotic mycetoma.

Figure 1. Photograph of the growths on the right foot.

Simultaneously the sample was inoculated on plain Sabouraud's dextrose agar, 10% sheep blood agar and brain heart infusion broth. Sabouraud's dextrose agar was incubated at 25°C and 37°C and the samples were examined daily. Inoculated blood agar plates were incubated under aerobic and anaerobic conditions. On the tenth day of incubation a growth was seen on blood agar, which was incubated aerobically. The colony was glabrous, waxy, heaped and folded in appearance. The colour of the colony was initially white and later changed to a tan colour. As anticipated, Gram stain revealed gram-positive branching filaments from the growth (Figure2).

Figure 2. Microscopy reveals branching bacterial filaments

The isolate was further identified by standard bacteriological methods. Following culture, biochemical studies were conducted, including hydrolysis of casein, tyrosine, xanthine, gelatin, starch, and urea. Acid formation from lactose, xylose,

and cellobiose were performed for definitive identification of these bacteria at species level.

Discussion

Mycetoma is characterized by the formation of grains containing aggregates of the causative organisms that may be discharged onto the skin surface through multiple sinuses. The disease was described in 1842 and initially named madura foot, after the region of Madurai in India where it was first identified. "The draining sinuses with the presence of grains are characteristic of etiologic agents, including a variety of bacteria (actinomycotic mycetoma) or fungi (eumycotic mycetoma)". It usually affects the foot, hand and legs with tissues becoming necrosed and swollen after infection [6-10]. *Actinomadura* genus includes three species, *Actinomadura madurae*, *A. pelletieri* and *A. dassonvillei*. The nomenclature of the *A. dassonvillei* species has now been changed to *Nocardiosis dassonvillei*. *A. madurae* is distinguished from *A. pelletieri* by its ability to produce acid from cellobiose. It is one of the commonest causes of actinomycotic mycetoma characterized by formation of granules containing branched filaments. The growth rate of *Actinomadura* is slow. It grows on routine mycological media and under aerobic conditions [11]. The clinical characteristics are almost the same regardless of whether the disease is caused by actinomycetes or fungus.

Talwar and Sehgal studied 60 clinically suspected cases of mycetoma. Of the 60 suspected cases, 20 were confirmed by culture and histopathological examination. The feet were found to be affected in 70% of these cases (7). Dogra *et al.* [10] reported a case of actinomycotic mycetoma in a young female. Diagnosis was made by Gram staining and confirmed by histopathological examination. In the present study, diagnosis was made by Gram staining and confirmed by culture. We report a case of actinomycotic mycetoma from a tertiary health care centre from northern India. The case is reported owing to its rare occurrence as only a few such mycetoma cases have been reported from northern India. Although actinomycotic mycetoma is less common in northern India than eumycetoma mycetoma, Bakhi and Mathur have reported a rising incidence of actinomycotic mycetoma in western Rajasthan due to changes in climatic conditions. They have observed that the ratio of the prevalence of

maduromycotic mycetoma to the prevalence of actinomycotic mycetoma has decreased from 4:1 to 1.91:1 during the last five years in western Rajasthan [5]. Treatment regimens usually consist of combination therapy. Combination therapy of two or more drugs is often used to prevent resistance to one antibiotic and persistence of the infection. Our patient responded to Dapsone 100 mg 1 tablet OD, Bactrim DS 1 tablet BD and daily Rifampicin 600mg 1 tablet OD for five weeks. Treatment response was assessed after five weeks. The patient showed good

progress, with a fair diminution of local pain and nodule size, and treatment was further continued for five months. The lesions have shown definite regression after six months of therapy. Hence the identification of the causative agent and differentiation of eumycotic mycetoma from actinomycotic mycetoma constitute the major points in application of appropriate antimicrobial therapy. The novelty of this case is its unusual geographic presentation in northern India.

References

1. Singh H (1979) Mycetoma in India. *Indian J Surg*; 41:577-97.
2. Venugopal TV and Venugopal PV (1991) *Actinomadura madurae* causing mycetoma Madras. *Indian J Pathol Microbiol*; 34:119-125.
3. Mathur DR, Joshi KR, Mathur A (1979) An etiological and pathological study of mycetoma in western Rajasthan. *Curr Med Pract* 23:151-161.
4. Venugopal TV and Venugopal PV (1977) Mycetoma in Madras. *Sabouraudia*; 15: 17 -22.
5. Bakshi R and Mathur DR (2008) Incidence and changing pattern of mycetoma in western Rajasthan. *Indian J Pathol Microbiol* 51 (1) 155-56.
6. Maiti P K, Ray A, Banerjee Soma (2000) Bilateral eumycetoma: A rare presentation. Case report. *Indian J Medical Microbiol* 18 (3): 135-36.
7. Talwar P, Sehgal SC (1979) Mycetoma in North India. *Sabouraudia* 17: 287-91.
8. Chakrabarti A and Singh K (1998) Mycetoma in Chandigarh and surrounding areas. *Indian J Medical Microbiol* 16: 64-65.
9. Gupta S K, Shukla VK, Khanna S (1990) Primary actinomycotic mycetoma of the anterior abdominal wall (a case report) *JPGM* 36 (3): 175-7.
10. Dogra A, Minocha YC, Gupta M, Khurana S (2000) Actinomycotic Mycetoma. *IJDVL* 66 (6): 318-319.
11. Rai V M and Balachandran C (2006) Actinomycotic mycetoma of the hand: A rare occurrence. *IJDVL* 72(2): 178.

Corresponding author: Dr. Ragini Tilak

Department of Microbiology, Institute of Medical Sciences
Banaras Hindu University, Varanasi 221005, India

E mail: raginijain29@rediffmail.com

Conflict of interest: No conflict of interest is declared.