

Case Report

Hydatid cyst of the cranial vault

Faten Limaiem¹, Selma Bellil¹, Khadija Bellil¹, Ines Chelly¹, Amina Mekni¹, Jalel Kallel², Slim Haouet¹, Moncef Zitouna¹, Nidhameddine Kchir¹

Department of Pathology¹ and Neurosurgery², La Rabta Hospital Bab Saâdoun 1007 Tunis, Tunisia

Abstract

Only 0.5 to 2% of hydatid cysts are localized in the skeleton and of these, 3 to 4% are found in the skull. In this paper, the authors report a case of primary hydatidosis involving the cranial vault revealed by a bulging mass of the forehead and symptoms of raised intracranial pressure that occurred in a 22-year-old woman who came from a rural area. Through this case and literature review, the authors analyse the epidemiological, clinical and radiological aspects of skull hydatidosis. They conclude that hydatid cyst should be considered in the differential diagnosis of any soft tissue swelling or osteolytic lesion in the scalp of patients living in endemic areas.

Key words: hydatidosis; skull; cranial vault.

J Infect Dev Ctries 2009; 3(10):807-810.

(Received 5 June 2009 – Accepted 6 August 2009)

Copyright © 2009 Limaiem *et al.* This is an open-access article distributed under the Creative Commons Attribution License, which permits unrestricted use, distribution, and reproduction in any medium, provided the original work is properly cited.

Introduction

Osseous hydatidosis is rare, accounting for only 0.5% to 2.5% of human hydatidosis [1]. Most cases have been observed in adults, with the vertebrae and pelvis being the predominant locations [2]. Skull involvement is exceedingly rare, being found in only 3% to 4% of bone hydatidosis [3]. In this paper, we report a case of primary hydatidosis involving the cranial vault revealed by a bulging mass of the forehead and symptoms of raised intracranial pressure.

Case Report

A 22-year-old previously healthy woman, a member of a farming family living in close contact with dogs, presented with a two-month history of holocranial headache and vomiting. One month later, she noticed a bulging mass in her forehead that gradually increased in size. On admission, physical examination showed a soft, painless mass located in the forehead measuring approximately 6 cm x 4 cm. Neurological examination was within normal limits. Analysis of peripheral blood samples showed findings within the normal range, except for the presence of an eosinophilia. Hydatid serologic tests were negative. CT scan (Figures 1 and 2) demonstrated a well-circumscribed hypodense and multiloculated cystic lesion situated in the right

frontal region associated with swelling of soft tissue and osteolysis of the inner and outer table of the adjacent frontal bone. The patient underwent frontal craniectomy with extirpation of the extradural cysts, followed by cranioplasty. Postoperative CT scan revealed no residual cyst. Histopathological examination of the surgical specimen confirmed the diagnosis of hydatid cyst. The early postoperative course was uneventful. Radiological investigations including chest radiograph and abdominal ultrasonography showed no evidence that the hydatid disease involved any other organ system. The patient was discharged seven days after the operation and received albendazole treatment. At the last routine follow-up visit (two years postoperatively), the patient complained of fever, recurrent headaches, and frontal bossing. CT scan demonstrated recurrence of hydatid disease and the patient underwent a second surgical intervention. At present, she is still on follow-up.

Discussion

Hydatidosis is a zoonotic disease that occurs worldwide and is most common in agricultural regions. Human echinococcosis, also known as hydatid disease, results from infestation with the tapeworm *Echinococcus granulosus*, which lives in the intestinal tract of dogs [4]. Other related human

Figure 1. Axial CT scan demonstrating a hypodense multiloculated cystic lesion located in the right frontal region associated with swelling of the adjacent soft tissue and osteolysis of the inner and outer table of the frontal bone.

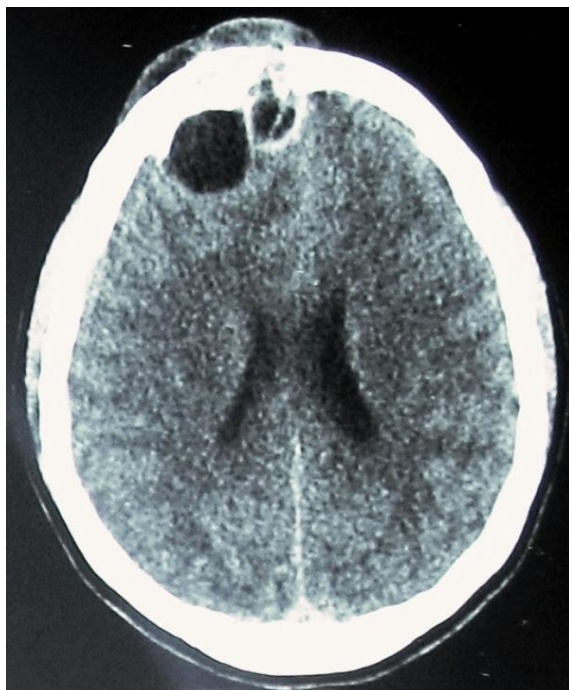
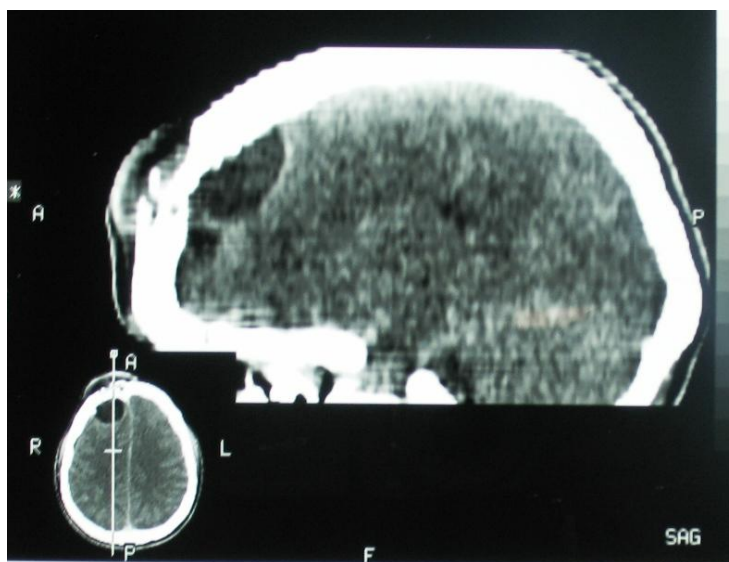


Figure 2. Sagittal CT scan displaying a right frontal hypodense multiloculated cystic lesion associated with swelling of soft tissue and osteolysis of the inner and outer table of the frontal bone.



pathogens are *Echinococcus multilocularis* and *Echinococcus vogeli*. Infection with *E. granulosus* results in the formation of a unilocular hydatid cyst, whereas infection with *E. multilocularis* produces multilocular disease. Primary hydatid disease of bone due to *E. granulosus* occurs when a blood-borne

scolex settles in bone. In bone involvement, pericyst formation does not occur, thereby allowing aggressive proliferation in an irregular branching fashion along the line of least resistance, especially the bone canals. The parasite replaces the osseous tissue between trabeculae due to the slow growth of

multiple vesicles. With time, the parasite reaches and destroys the cortex, with subsequent spread of the disease to surrounding tissues [4,5]. Since its initial description by *Guesnard* in 1836, approximately 89 well-documented cases of skull hydatidosis have been reported in literature to date with the cranial vault (68.5%) being more commonly involved than the skull base [6,7,8]. Cranial hydatidosis is predominantly seen in young adult males [6]. Its symptomatology varies according to cyst location and the direction of growth. As the cyst grows, the bone undergoes pressure atrophy and the inner or outer table of the skull ruptures. The inner table of the skull frequently ruptures and the vesicular larva passes into the epidural space inducing symptoms of increased intracranial pressure. Less frequently, cysts may rupture the outer table of the skull at many spots and involve the scalp to produce prominence on the head [6]. Generally, four syndromes dominate the presenting clinical manifestations of cranial hydatid disease including increased intracranial pressure (48%), skull deformity (48%), cranial nerve palsies (42%), and focal neurologic disturbance (30%) [6]. Our patient presented with symptoms of increased intracranial pressure followed by the appearance of a bulging mass of the forehead. Conventional radiography usually shows a variable-sized ill-delineated osteolysis without osteosclerosis. CT scan and MRI are valuable in the identification of cerebral and bone lesions and are helpful in surgical planning. CT scans obtained before and after contrast medium injection show the multivesicular pattern of the lesion and reveal its endo- and exocranial extensions [2]. On CT scan and MRI, intracranial hydatid cysts appear as solitary, homogeneous, spherical cysts with well-defined borders and without perifocal edema. The density of the cyst fluid is the same as that of cerebro-spinal fluid. The differential diagnosis of intraosseous hydatid cyst may be difficult especially in cases of pure skull involvement. In our case, the association of the intracranial cystic lesion to osteolysis of the inner and outer tables was highly suggestive of hydatid cyst. The peripheral blood and cerebrospinal fluid eosinophilia tests may be helpful for the diagnosis of hydatid disease [9]. Serologic tests are valuable when they are positive but they are usually false negative for osseous hydatidosis [10]. The immunoreaction of the human body is related to the hydatid cyst's integrity, growth vigour, and location. Immunoreaction is heavier in ruptured hydatid cysts and lower when intact. Serological tests are frequently negative when the hydatid cyst is

ageing, calcified, or dead [11]. In our case, analysis of peripheral blood samples showed the presence of an eosinophilia but serological tests were negative. By far, the definite diagnosis of hydatid cyst must depend on pathological examination of the surgical specimen. Total resection of the cyst without rupture via the craniectomy is the recommended treatment; however, extradural hydatid cysts of intraosseous origin may be difficult to excise completely because of their adherence to dura and osseous trabeculae [9,12]. Excision is often incomplete, thus explaining frequent recurrences. Patients with intraosseous hydatid cysts should be treated with albendazole for at least three months and monitored for up to twelve months before they are considered cured [9].

In conclusion, this case report highlights the fact that hydatid cyst should be considered in the differential diagnosis of any soft tissue swelling or osteolytic lesion of the scalp of patients living in endemic areas.

References

1. Zlitni M, Ezzaouia K, Lebib H, Karray M, Kooli M, Mestiri M (2001) Hydatid Cyst of Bone: Diagnosis and Treatment. *World J Surg* 25: 75–82.
2. Ennouri S, Ayadi K, Ben Ali H, Mnif J (2000) Hydatid cyst of the temporal bone. An exceptional location. *AJR* 175: 923-924.
3. Behari S, Banerji D, Phadke RV, Shukla S, Krishnani N, Chhabra DK (1997) Multiple infected extradural parasellar hydatid cysts. *Surg Neurol* 48: 53-57.
4. Hoeprich PD, Jordan MC (1989) *Infectious Diseases*, 4th edition. New York: JB Lippincott. 832.
5. Behari S, Banerji D, Phadke RV, *et al.* (1997) Multiple infected extradural parasellar hydatid cysts. *Surg Neurol* 48: 53–57.
6. Aydin Y, Aydin F, Turec U (1992) Intradiploic and cerebral hydatidosis: a case report and review of literature. *Clinical Neurology and Neurosurgery* 94: 229-233.
7. [Kozlowski K](#), [Campbell J](#), [McAlister W](#) (1991) Rare primary cranial vault and base of the skull tumors in children. Report of 30 cases with a short literature review. [Radiol Med](#) 8: 213-224.
8. Hilmani S, Bertal A, Lakhdar A, Ouboukhlik A, Elkamar A, Elazhari A (2006) Craniocerebral hydatid cyst: case illustration. *J Neurosurg* 105: 77.
9. Erman T, Tuna M, Göçer I, Ildan F, Zeren M, Çetinalp E (2001) Intracranial intraosseous hydatid cyst. Case report and review of the literature. *Neurosurg Focus* 11: 1-3.
10. Arazi M, Erikoglu M, Odev K, Memik R, Ozdemir M (2005) Primary echinococcus infestation of the bone and muscles. *Clin Orthop Relat Res* 432: 234-241.
11. Song XH, Ding LW, Wen H (2007) Bone hydatid disease. *Post grad Med J* 83: 536-542.
12. Canbolat A, Onal C, Kaya U (1994) Intracranial extradural hydatid cysts: report of three cases. *Surg Neurol* 41: 230–234.

Corresponding author

Dr. Faten Limaïem
Department of Pathology, La Rabta Hospital
Bab Saadoun (1007)
Tunis – TUNISIA
Telephone: 00216 96 55 20 57
Email: fatenlimaïem@yahoo.fr

Conflict of Interest: No conflict of interest is declared.