

***Cyclospora cayetanensis*: First report of imported and autochthonous infections in Kuwait**

Jamshaid Iqbal¹, Parsotam R. Hira¹, Faiza Al-Ali², Nabila Khalid¹

¹Department of Microbiology, Faculty of Medicine, Kuwait University, PO Box: 24923, Safat 13110, Kuwait

²Department of Laboratories, Farwania Hospital, PO Box: 2, Safat 13001, Kuwait

Abstract

Introduction: The intestinal coccidian parasites *Cryptosporidium* spp. and *Cyclospora cayetanensis* have emerged as significant human pathogens worldwide. The reports of *Cyclospora cayetanensis* infection in the Middle East are sporadic and no case has been reported from Kuwait.

Methodology: Stool specimens were collected from six individuals presenting with watery diarrhoea of varying degree and severity at the District General hospitals, Kuwait. Four patients were male, two were female and their ages ranged from 5 to 64 years. Three cases were seen among the migrant population from the Indian subcontinent who had recently returned to Kuwait and two cases were seen in the local population with no history of travel abroad. The stool smears were stained with modified acid-fast stain and examined under ultraviolet (UV) fluorescence illumination.

Results: *Cyclospora cayetanensis* oocysts with variable staining characteristics were detected by microscopy. Two of the cases were also associated with other enteric pathogens. Clinical suspicion of *Cyclospora* infection was not recorded for any of the cases. All patients showed remarkable symptomatic and parasitologic improvements upon treatment with trimethoprim/sulfamethoxazole.

Conclusion: *Cyclospora* spp. are important aetiological agents of diarrhoea in the Middle East. An awareness of the parasitic infection and use of appropriate diagnostic modalities are essential to elucidate the clinical and epidemiological significance of the parasitosis in this geographic area.

Key words: Cyclosporiasis; autochthonous; imported; Kuwait

J Infect Dev Ctries 2011; 5(5):383-390.

(Received 07 November 2010 – Accepted 22 December 2010)

Copyright © 2011 Iqbal *et al.* This is an open-access article distributed under the Creative Commons Attribution License, which permits unrestricted use, distribution, and reproduction in any medium, provided the original work is properly cited.

Introduction

Cyclospora cayetanensis is an important emerging cause of diarrhoea worldwide that generally causes mild to moderate self-limiting diarrhoea in immunocompetent hosts and prolonged severe diarrhoea in immunocompromised individuals [1]. It was first described as causing prolonged, watery diarrhoea in humans in Papua New Guinea, by Ashford in 1979 [2]. *C. cayetanensis* infection has been described worldwide but predominates in tropical and subtropical areas, and in urban and rural areas [1,3]. However, prevalence rates of *Cyclospora* are often underestimated because of the low sensitivity of detection methods and the intermittent nature of oocyst shedding. In developed countries, the disease has been associated with cases of traveller's diarrhoea; the parasite is commonly isolated from travellers to Latin America, the Indian subcontinent and Southeast Asia [4-8]. In immunocompetent individuals, very low infection

rates of $\leq 1\%$ have been observed. In immunocompromised persons, prevalences of 0-5.6% have been found.

The prevalence of *C. cayetanensis* is unknown in some developing countries. However, reports of sporadic cases of infection in local residents or foreign visitors reflect the endemicity of infection in these nations. In the Arabian Gulf countries in particular, and in the Middle East in general, the reports of emerging coccidian infections have been sparse [9,10]. The State of Kuwait is in a desert geographic region characterized by long, dry, hot summers and short, relatively warm winters. There has been no report of *C. cayetanensis* infection in Kuwait; however, recently a unique endemicity of *Cryptosporidium* spp., a coccidian infection, in children with predominance of *C. parvum* has been documented [11].

In the present study, we demonstrate that *Cyclospora* spp. are both imported and endemic in

Kuwait. Furthermore, details of six cases are presented to highlight the patterns of infection and transmission of *Cyclospora* infection in Kuwait.

Methodology

Study population and specimen collection

Stool specimens were collected from patients presenting with diarrhoea during the period of September 2007 to May 2010. Those patients passing more than four soft or watery stools per day were recorded as having diarrhoea. The patients were seen at three District General Hospitals and the Mubarak Al-Kabir Teaching Hospital in Kuwait. These hospitals cover a large population living in urban as well as semi-urban areas. Information on the number, consistency and amount of stools passed each day by the patient was recorded. Demographic information, area of residence, socio-economic status, contact with animals, source of drinking water and food were also documented. The study was approved by the Research Ethical Committee of Faculty of Medicine, Kuwait University.

Stool collection and examination

Single faecal samples were collected in a plastic container when the patient presented at the clinic. The specimens were processed immediately for the detection of enteropathogenic bacteria, *Cyclospora* and *Cryptosporidium* oocysts, as well as other protozoan and nematode parasites. Specimen consistency, colour and the presence of worms and mucus or blood were also noted. Direct faecal smears were prepared with a drop of physiological saline, stained with Lugol's iodine and microscopy was performed to detect *Giardia* and other protozoan parasites. All stool samples were processed by the Fecal Parasitic Concentration (FPC) method using the FPC concentrator (Evergreen Scientific, LA, CA, USA) as described by the manufacturer. Briefly, the stool specimen was diluted in 9 mL of 10% formalin, mixed thoroughly, and three drops of 20% Triton X-100 were added to the mixed specimen. The specimen was passed through the strainer and centrifuged at 2,000 rev/minute for 2 to 4 minutes. The sediment smear was examined for coccidian parasites, *Cyclospora* and *Cryptosporidium* oocysts after staining with modified acid-fast stain.

Cyclospora-positive samples were also cultured for enteric bacterial pathogens as described previously [12]. Briefly, the samples were plated on MacConkey agar (MA) (Difco International, Leewardsen, The Netherlands), and *Salmonella*-

Shigella agar (SSA) (Oxoid Limited, Hampshire, UK). MA and SSA were used for isolation of *Escherichia coli*, *Salmonella* spp. and *Shigella* spp., and Campy-blood agar was used for isolation of *Campylobacter jejuni*. Rotavirus was detected by an enzyme-linked immunosorbent assay. During the study period, 50 stool samples from asymptomatic persons were also screened for *Cyclospora* oocysts.

Modified acid-fast staining

Faecal smears were stained with 1% safranin for one minute as described previously [13]. Briefly, the smears were passed through the flame of a Bunsen burner once and then fixed with 3% HCl in methanol (acid-methanol) for 3 to 5 minutes. Methylene blue (1%) was used as a counter-stain. Characteristic oocysts appeared as spherical structures of 8 µm to 10 µm in diameter, with variable acid-fast staining; some stained bright pink and some remain unstained. As a standard test, autofluorescence under ultraviolet (UV) illumination was also used for the diagnosis of *Cyclospora* infection in stool samples.

Results

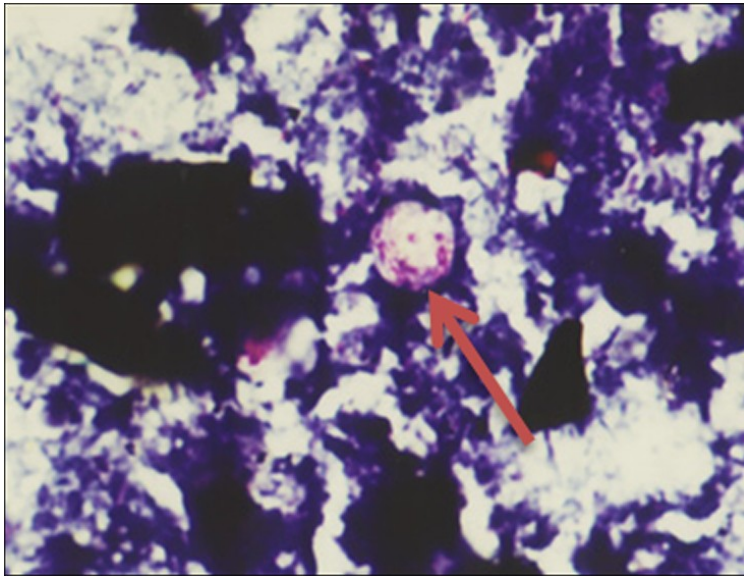
The modified acid-fast staining method showed sufficient colour contrast to permit scanning even at low magnification (Figure 1). During the study period, stool specimens from 1,706 patients with diarrhoea were screened for coccidian parasites, *Cyclospora* and *Cryptosporidium* oocysts. The *Cyclospora* oocysts were detected in only six cases and *Cryptosporidium* oocysts were detected in 23 (1.34%) cases. Three of the six cases had *Cyclospora* infection alone, while in others the infection was associated with one or more enteric pathogens including rotavirus, *Shigella flexneri*, *Giardia duodenalis* and *Entamoeba coli* (Table 1).

No significant difference was recorded in the demographic data among the *Cyclospora*-positive cases. The majority of the population in Kuwait lives in urban areas with a clean piped water supply and has easy access to free-of-charge health facilities. There was no significant association of *Cyclospora*-positive cases and contact with animals.

We present six cases that highlight the problems encountered in a routine laboratory in the diagnosis of *Cyclospora cayentanensis* in patients with diarrhoea to clarify and resolve some of the dilemmas and to elaborate on the clinical and epidemiological significance of the findings (Table 1).

Figure 1. A stool smear stained in modified acid-fast stain showing the size and the staining characteristics of the oocysts (A) and the UV autofluorescence (B) of *Cyclospora cayetanensis*.

1A.



1B.

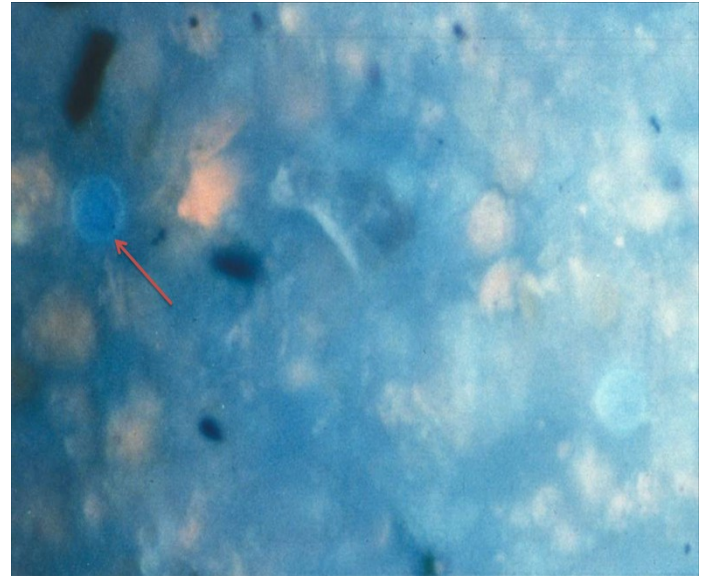
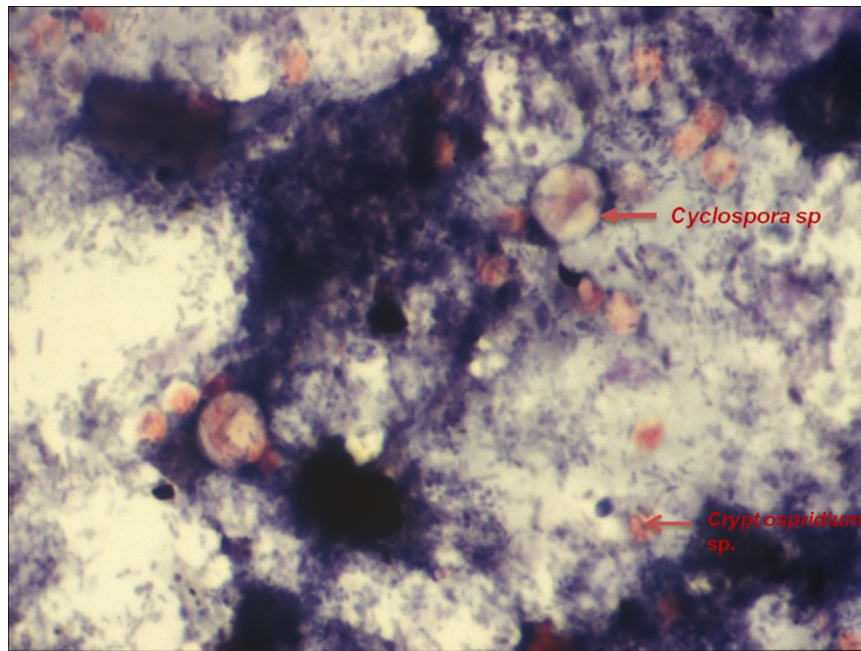


Figure 2. A stool smear stained in modified acid-fast stain showing the size difference and staining characteristics between *Cyclospora cayetanensis* and *Cryptosporidium* spp. in a 5 year-old Kuwaiti child (case # 5).



Case 1

JM, a 36-year-old male ethnic Nepali labourer, presented at the outpatient clinic of Mubarak Al-Kabir hospital with a history of epigastric pain and watery diarrhoea over a period of ten days. Microscopic analysis of the faecal smear stained with acid-fast stain showed numerous spherical double-walled microorganisms 8-11 μm in diameter, some with internal granulation. The organisms appeared dark pink in colour; some cysts were completely stained while others were minimally stained or not stained at all (Fig 1A). UV microscopy showed autofluorescence at 365 nm excitation; typical neon-blue circles representing the oocysts of *Cyclospora* spp. were observed (Fig 1B). The organisms were identified as *Cyclospora cayetanensis*. The patient was treated with Sulfamethoxazole-Trimethoprim (TMP/SMZ) (160/800 mg) twice a day for seven days and he had an uneventful recovery. Following treatment, re-examination of a stool sample showed no organisms. This was the first case of *Cyclospora cayetanensis* infection in Kuwait. This was most probably an imported case as the patient had come to Kuwait recently.

Case 2

RR, a 64-year-old Kuwaiti male, a known case of lymphoma on chemotherapy, complained of nausea and vomiting initially attributed to the drug intake. He complained of diarrhoea, vomiting, and weight loss over a period of two weeks. The stool was watery and he passed more than 6 stools per day. He also had intermittent fever of 38 °C. At the time of admission, his white blood count (WBC) was 12,700 cu mm. The HIV test was non-reactive and serum immunoglobulins were within normal limits. Empirically he was given ampicillin for three days. Other medications prescribed during the hospital stay were loperamide hydrochloride, ranitidine hydrochloride, metronidazole, and piperacillin. Microscopic analysis of the stool smear stained in modified acid-fast stain showed numerous faint pink to red spherical cysts 8-9 μm in diameter while some cysts did not take up the stain. The organisms were identified as *Cyclospora cayetanensis*. Later, UV microscopy showed autofluorescence at 365 nm excitation and the typical neon-blue circles representing the oocysts of *Cyclospora* spp. were observed. The stool culture was positive for *Shigella flexneri* and showed *Entamoeba coli* cysts on direct microscopy of stool smears.

He had no history of recent travel and no other members of the family had any gastro-intestinal symptoms. He used bottled mineral water but had a history of outdoor food intake which included green salads, lamb and poultry.

The patient was treated with TMP/SMZ (160/800 mg) twice a day for two weeks and his immunosuppressive therapy was readjusted to improve his immune status. The severity of his diarrhoea improved and the stool smear became negative both for *Cyclospora* and *Cryptosporidium* spp. This was the first autochthonous case of *Cyclospora cayetanensis* infection detected in Kuwait.

Case 3

FL, a 29-year-old Kuwaiti female, was admitted to District General Hospital with a six-day history of profuse watery diarrhoea and vomiting. She had been to a polyclinic the previous week but the diarrhoea recurred and was now more severe. A stool sample was sent to the laboratory for culture but no pathogens were isolated after 72 hours. Direct smears of the stool and a concentrated sediment stained in the acid-fast stain both showed many oocysts. The oocysts measured approximately 10 μm and showed variable staining characteristics. The oocysts were maintained at room temperature in 2.5% potassium dichromate. Most of the oocysts sporulated by the 10th day showing two sporocysts each containing two sporozoites. There was no history of recent travel.

Case 4

EH, a 42-year-old Kuwaiti male, presented with a 10-day history of profuse watery diarrhoea and an itchy anus. He had a long history of gastrointestinal symptoms, particularly flatulence and dyspepsia. Examination of the stool smear by acid-fast staining showed the *Cyclospora cayetanensis* oocysts measuring 9 -10 μm . The majority of the oocysts, however, did not take up the stain. UV microscopy showed the typical blue autofluorescence of the oocysts at 365 nm excitation. The patient was treated with the standard dose of TMP-SMZ for seven days and there was prompt relief of the symptoms. Subsequent examination of stool during treatment showed a diminution in the number of oocysts and the stool became negative for oocysts after 14 days of treatment. He had made multiple business tours to India and Thailand during the past six months and

Table 1. Summary of social demographics and clinical characteristics of patients infected with *Cyclospora cayetanensis* in Kuwait

Patient data	Case 1	Case 2	Case 3	Case 4	Case 5	Case 6
Male/Female	M	M	F	M	M	F
Age (years)	36	64	29	42	5	25
Infection status*	I	L	L	I	L	I
Duration of diarrhoea (days)	10	14	6	10	5	14
Clinical features						
Fever	-	+	-	-	+	+
Vomiting	-	+	+	-	+	-
Abdominal pain	+	-	-	+	-	-
Associated enteric pathogens [#]	-	s/e	-	-	r/g/c	-

*I, imported; L, local (indigenous)

[#]s, *Shigella flexneri*; e, *Entamoeba coli*; r, Rotavirus; g, *Giardia duodenalis* cysts; c, *Cryptosporidium* spp.

most probably got the infection during his visits to these endemic countries.

Case 5

A five-year-old child was admitted to the paediatric unit of Mubarak Al-Kabir hospital with a five-day history of profuse watery diarrhoea, nausea, vomiting and fever. The child was severely dehydrated. The microscopy of the stool specimen showed numerous spherical cyst-like structures 8-10 µm in diameter. The modified acid-fast staining of the stool smear showed dark pink to red oocysts; some cysts did not take up the stain or were stained partially. The organisms were identified as *Cyclospora cayetanensis*. In addition, a few oocysts between 4 and 6 µm in diameter stained bright pink, with a clear central halo, were also seen. These organisms presented with typical morphology of *Cryptosporidium* spp. (Figure 2) which were also confirmed with a direct fluorescence antibody test for *Cryptosporidium* spp. Confirmation of the diagnosis was established by fluorescent microscopy that showed the typical blue autofluorescence of the oocysts at 365 nm excitation. The stool specimen was also positive for *Giardia* cysts. No enteropathogen was isolated after 72 hours of culture. The specimen was also positive for rotavirus antigen using a sandwich ELISA technique. The HIV test was non-reactive and the serum immunoglobulins were within normal limits. The child was treated with TMP/SMZ (160/800 mg) twice a day for two weeks. Following treatment, re-examination of a stool sample revealed no more organisms and the diarrhoea stopped.

The child and the family did not travel abroad during the last 12 months; however, the family had a domestic helper from Sri Lanka. The stool specimen from the domestic helper showed *Giardia duodenalis* cysts but was negative for *Cyclospora cayetanensis*.

Case 6

ZI, a 25-year-old Indian domestic helper, presented at the outpatient clinic of Mubarak Al-Kabir hospital with a history of nausea and intermittent watery diarrhoea over a period of two weeks. She also complained of a cough and had a fever of 38.4°C. Microscopic analysis of the stool revealed few spherical cystic bodies 8-10 µm in diameter. The stained stool smear showed dark red cystic bodies; some cysts were stained deeply red but a few of the cysts did not stain at all. The organisms showed the typical blue autofluorescence at 365 nm excitation and were identified as *Cyclospora cayetanensis*. The patient was treated with TMP/SMZ (160/800 mg) twice a day for ten days and she had an uneventful recovery. She had recently returned to Kuwait after spending two months in her home country.

Discussion

C. cayetanensis is an obligate intracellular parasite with a life cycle not fully characterised. In immunocompetent individuals, very low infection rates of ≤ 1% have been observed. However, *C. cayetanensis* constitutes a significant cause of chronic and intermittent diarrhoea in

immunocompromised patients, especially those with AIDS.

Occurrence of *C. cayetanensis* outbreaks has mostly been reported in the developed world [14-16], whereas their occurrence in developing countries are limited, which may be due to the indiscriminate use of antibiotics effective against *C. cayetanensis* and the lack of adequate diagnostic capability [17].

This paper reviews the current status of cyclosporiasis in Kuwait and discusses the modes of transmission of *Cyclospora* infection that are essential to understand the surveillance and risk factors for the infection, in order to institute appropriate risk management and prevention of transmission.

It is pertinent to note that *Cyclospora* spp. are perhaps endemic in Kuwait as at least two of the six cases (cases 2 and 3) had no history of recent travel to an endemic country. In contrast, cases 1 and 6 had recently returned from Nepal and India respectively and most probably contracted the infection in their home countries. We could not determine the source and route of transmission of infection in the 5-year-old Kuwaiti child (case 5) as neither he nor his family had travelled abroad in recent months. However, one of their domestic helpers had recently returned from Sri Lanka, an endemic country. Though she had no diarrhoea and her stool specimen was negative for *Cyclospora* and *Cryptosporidium* oocysts, she may have had the infection while she was in her home country. It appears that in endemic areas, persistent exposure may be associated with immunity to illness and asymptomatic excretion [18,19]. *Cyclospora* oocysts in freshly excreted stool are non-infectious and thus direct person-to-person transmission of *Cyclospora* spp is highly unlikely as the oocysts require days to weeks outside the host under favourable environmental conditions to sporulate and thus become infectious [4]. The factors that allow *C. cayetanensis* oocysts to become infectious in the environment and the modes of transmission are not fully understood. However, it is most likely that the asymptomatic domestic helper may have continued to excrete oocysts, which persisted in the environment, became infectious and subsequently transmitted to the child. The infectious oocysts can be transmitted in humans through exposure to faecally contaminated water, food, or soil.

It is essential to distinguish between diarrhoea caused by *Cyclospora* spp. and *Cryptosporidium* spp. Apart from the intrinsic need to contribute to the pool of knowledge, such a diagnosis is necessary as there

is specific chemotherapy available against *Cyclospora cayetanensis* which can alleviate the symptoms promptly and effect a radical medical cure as was demonstrated clearly in all our cases. *Cyclospora* organisms have also been isolated in chronic diarrhoea and this infection should be carefully distinguished from cryptosporidiosis [20,21,22].

It is imperative to underscore that the rudimentary nature of our current diagnostic techniques may in part contribute to the under-recognition of *Cyclospora* spp. Despite their distinct staining characteristics of variable appearance in acid-fast stain (ranging from unstained, pink to dark red), the *Cyclospora* spp. oocysts are often confused with *Cryptosporidium* spp.; however, *Cyclospora* spp. oocysts are larger at 8-11 μm in diameter and their numbers in stool are generally low to moderate compared to *Cryptosporidium* spp. It may be that many reported cases of diarrhoea alleged to be due to *Cryptosporidium* spp. may have actually been due to *Cyclospora* infection because measuring the size of the oocysts is not routinely done in the laboratory. Though the size of the oocysts and the UV autofluorescence may be reliable distinguishing characteristics of *Cyclospora* spp. [2-4], in reality only limited laboratories in many parts of the world have facilities capable of performing such analyses. Thus, lack of UV fluorescence microscopy and more importantly, the ready availability of a micrometer on the bench, are certainly additional limiting factors.

Several studies have reported *Cryptosporidium* infection in the Middle East in general and in the Arabian Gulf countries in particular [9-11]; however, there is limited information on the incidence of *Cyclospora* spp. in Arabian Gulf countries [23,24]. In addition to the limitations of current diagnostic techniques contributing to the under-reporting of the infection, many clinicians are not familiar with this infection and do not request tests for it specifically. In none of our six cases was a clinical suspicion of *Cyclospora* infection recorded. Another limiting factor in the identification of this infection in Kuwait and many parts of the Middle East may be the current health practices prevalent in polyclinics and casualty units in hospital settings. The majority of the cases with diarrhoea report first to a general practitioner at a local polyclinic and are generally treated with TMP/SMX. Neither laboratory stool examination nor acid-fast staining is performed. If the diarrhoea persists, the patient is referred to the casualty unit of a District General Hospital where TMP/SMX may be

repeated and a stool examination may or may not be done. As TMP/SMX is effective against *Cyclospora* spp. a number of cases may have been resolved with this treatment and therefore gone uncharacterised. However, to overcome this, we screen all loose, watery stool specimens with acid-fast staining at Mubarak Al-Kabir Hospital and thus were able to detect these six cases of *Cyclospora* spp. and the many cases of *Cryptosporidium* spp. reported earlier [5-8]. Sporadic cases of infection may be part of widespread outbreaks and should in any case be reported to public health officials. Public health personnel and clinicians should also be aware that stool examination for *Cyclospora* spp. should be specifically requested in case of clinical suspicion of *Cyclospora* infection (protracted or relapsing diarrhoeal episodes) [25].

In conclusion, *Cyclospora cayetanensis* is an important aetiological agent of diarrhoea in the Middle East. However, the poor sensitivity and specificity of diagnostic methods suggest that *Cyclospora* infection and illness have been underestimated. Further studies are needed to confirm the causative association with other diseases and to determine the incidence and epidemiological features of this organism. Furthermore, in the developing world, greater awareness of the parasite and increased familiarity with it or with the disease would improve surveillance programs for the coccidium and would increase the likelihood that future epidemics would be detected.

Acknowledgments

We gratefully thank the staff of the District General Hospital for helpful discussion and review of the manuscript. This work was supported by a Kuwait University Research Administration grant MI 03/03.

References

- Shields JM and Olson BH (2003) *Cyclospora cayetanensis*: a review of an emerging parasitic coccidian. *Int J Parasitol* 33: 371-391.
- Ashford RW (1979) Occurrence of an undescribed coccidian in man in Papua New Guinea. *Ann Trop Med Parasitol* 73: 497-500.
- Ortega YR, Sterling CR, Gilman RH (1998) *Cyclospora cayetanensis*. *Adv Parasitol*. 40: 339-418.
- Mansfield LS and Gajadhar AA (2004) *Cyclospora cayetanensis* a food-and waterborne coccidian parasite. *Vet Parasitol* 126: 73-90.
- Drenaggi D, Cirioni O, Giacometti A, Fiorentini A, Scalise G (1998) Cyclosporiasis in a traveler returning from South America. *J Travel Med* 5: 153-155.
- Bourée P, Lancon A, Bonnot G (2006) Une parasitose émergente: la cyclospore. *Revue à propos de five observations. Antibiotiques* 8: 73-78.
- Puente S, Morente A, García-Benayas T, Subirats M, Gascon J, Gonzalez-Lahoz JM (2006) Cyclosporiasis: a point source outbreak acquired in Guatemala. *J Travel Med* 13: 334-337.
- Ramirez-Olivencia G, Herrero MD, Subirats M, Gonzalez R, Puente S (2008) Brote de *Cyclospora cayetanensis* en viajeros a Cuba. *Enferm Infecc Microbiol Clin* 26: 558-560.
- Al-Braiken FA, Amin A, Beeching NJ, Hommel M, Hart CA (2003) Detection of *Cryptosporidium* amongst diarrhoeic and asymptomatic children in Jeddah, Saudi Arabia. *Ann Trop Med Parasitol* 97: 505-510.
- Bouree P, Lancon A, Bisaro F, Bonnot G (2007) Six human cyclosporiasis: with general review. *J Egypt Soc Parasitol* 37: 349-360.
- Sulaiman IM, Hira PR, Zhou L, Al-Ali FM, Shelahi FA, Shweiki HM, Iqbal JM, Khalid N, Xiao L (2005) Unique endemicity of cryptosporidiosis in Kuwait. *J Clin Microbiol* 43: 2805-2809.
- Albert, MJ, Faruque SM, Faruque AS, Neogi PK, Ansaruzzaman M, Bhuiyan MNA, Alam K, Akbar MS (1995) Controlled study of *Escherichia coli* diarrheal infections in Bangladeshi children. *J Clin Microbiol* 33: 973-7.
- Nimri LF (2003) *Cyclospora cayetanensis* and other intestinal parasites associated with diarrhea in a rural area of Jordan. *Int Microbiol* 6: 131-135.
- Ho AY, López AS, Eberhart MG, Levenson R, Finkel S, da Silva AJ, Roberts JM, Orlandi PA, Johnson CC, Herwaldt BL (2002) Outbreak of cyclosporiasis associated with imported raspberries, Philadelphia, Pennsylvania. *Emerg Infect Dis* 8: 783-788.
- Doller PC, Dietrich K, Filipp N, Brockmann S, Dreweck C, Vonthein R, Wagner-Wiening C, Wiedermann A (2002) Cyclosporiasis outbreak in Germany associated with the consumption of salad. *Emerg Infect Dis* 8: 922-994.
- Hoang LM, Fyfe M, Ong C, Harb J, Champagne S, Dixon B, Isaac-Renton J (2005) Outbreak of cyclosporiasis in British Columbia associated to imported Thai basil. *Epidemiol Infect* 133: 23-37.
- Torres-Slimming PA, Mundaca CC, Moran M, Quispe J, Colina O, Bacon DJ, Lescano AG, Gilman RH, Blazes DL (2006) Outbreak of cyclosporiasis at a naval base in Lima Perú. *Am J Trop Med Hyg* 75: 546-548.
- Ortega YR, Nagle R, Gilman RH, Watanabe J, Miyagui J, Quispe H, Kanagusuku P, Roxas C, Sterling CR (1997a) Pathologic and clinical findings in patients with cyclosporiasis and a description of intracellular parasite life-cycle stages. *J Infect Dis* 176: 1584-1589.
- Bern C, Ortega YR, Checkley W, Roberts JM, Lescano AG, Cabrera L, Verastegui M, Black RE, Sterling C, Gilman RH (2002) Epidemiologic differences between cyclosporiasis and cryptosporidiosis in Peruvian children. *Emerg Infect Dis* 8: 581-585.
- Long EG, Ebrahimzadeh A, White EH, Swisher B, Callaway CS (1990) Alga associated with diarrhea in patient with acquired immunodeficiency syndrome and in travelers. *J Clin Microbiol* 28: 1101-1104.
- Pape JW, Verdier RI, Boncy M, Boncy J, Johnson WD Jr (1994) *Cyclospora* infection in adults infected with HIV clinical manifestations, treatment and prophylaxis. *Ann Intern Med* 121: 654-657.
- Soave R (1996) *Cyclospora*: An overview. *Clin Infect Dis* 23: 429-437.

23. el-Karamany EM, Zaher TI, el-Bahnasawy MM (2005) Role of water in the transmission of cyclosporiasis in Sharkia Governorate, Egypt. *J Egypt Soc Parasitol* 35: 953-62.
24. Chacín-Bonilla L (2010) Epidemiology of *Cyclospora cayetanensis*: A review focusing in endemic areas. *Acta Tropica* 115: 181-193.
25. Herwaldt BL (2000) *Cyclospora cayetanensis*: A review, focusing on the outbreaks of cyclosporiasis in the 1990s. *Clin Inf Dis* 31: 1040-1057

Corresponding author

Jamshaid Iqbal
Department of Microbiology, Faculty of Medicine
Kuwait University
PO Box no. 24923
Safat 13110, Kuwait
Telephone: 965- 24986526
Fax: 965- 25332719
Email: iqbal@hsc.edu.kw

Conflict of interests: No conflict of interests is declared.