

## Outbreak of *Tinea capitis* and *corporis* in a primary school in Antananarivo, Madagascar

Jean-François Carod<sup>1</sup>, Mahery Ratsitorahina<sup>1</sup>, Hasina Raherimandimby<sup>1</sup>, Virginie Hincky Vitrat<sup>1</sup>, Vololomboahangy Ravaolimalala Andrianaja<sup>1</sup>, Nelly Contet-Audonneau<sup>2</sup>

<sup>1</sup>Institut Pasteur de Madagascar, BP 1274 Antananarivo 101, Madagascar

<sup>2</sup>Laboratoire de mycologie, hôpital Fournier, CHU de Nancy, 36, quai de la Bataille, 54035 Nancy cedex France

### Abstract

**Introduction:** *Tinea capitis* is common among schoolchildren in developing countries but underreported in Madagascar. We report the occurrence of an outbreak of gray patch *tinea capitis* due to *Microsporum langeronii* in a public primary school of Antananarivo, the capital city of Madagascar.

**Methodology:** Forty-two children were included, 27 (64%) of them presenting with *tinea capitis* and 32 (76%) with *Tinea corporis*. Patients were treated with griseofulvin 500 mg and Povidone-iodine 4% and followed up for four weeks.

**Results:** Twenty-five (93%) of the 27 children with *tinea capitis* presented a gray patch as the main clinical feature. All these cases were fluorescent under Wood's UV light and positive in cultures for *M. langeronii*. All 27 children reported a contact with infected classmates, and 19 (70%) reported to have infected brothers and sisters at home. After four weeks of treatment, all patients recovered.

**Conclusion:** Appropriate treatment and improved hygienic practices reduced the occurrence of *tinea* in the studied school and no more cases of *tinea capitis* or *corporis* occurred after the outbreak.

**Key words:** *tinea capitis*; *Microsporum audouinii*; dermatophytes; outbreak; Madagascar

*J Infect Dev Ctries* 2011; 5(10):732-736.

(Received 01 March 2011 – Accepted 25 May 2011)

Copyright © 2011 Carod *et al.* This is an open-access article distributed under the Creative Commons Attribution License, which permits unrestricted use, distribution, and reproduction in any medium, provided the original work is properly cited.

### Introduction

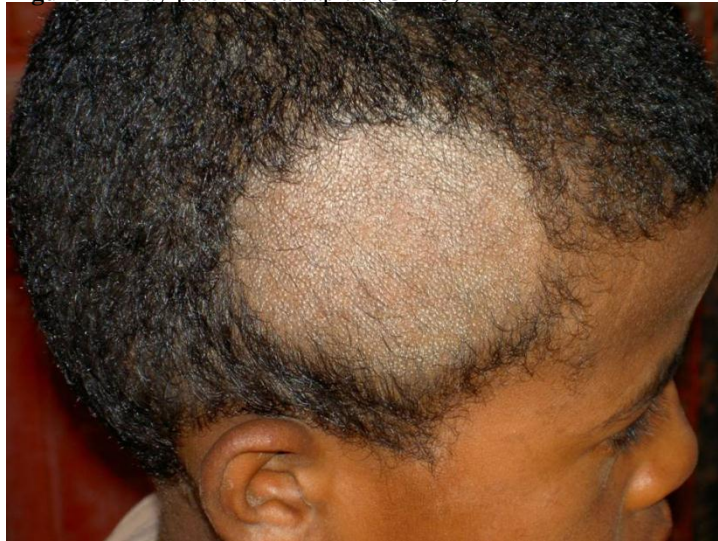*Tinea capitis* is a dermatosis of the scalp due to dermatophytes that can cause hair loss. It is a common infection among schoolchildren in developing countries [1,2]. *Tinea capitis* is caused predominantly by *Trichophyton* or *Microsporum* species. According to their host preference and natural habitat, dermatophytes are also classified as anthropophilic, geophilic and zoophilic. Moreover, the predominant dermatophytes causing *tinea capitis* in a given geographic region can also change over time [2,3]. The incidence of *tinea capitis* in developed countries has clearly declined following improvements in socioeconomic conditions, the introduction of griseofulvin for treatment, and also the introduction of adequate school surveillance programs [1]. In Africa, however, *tinea capitis* continues to be an important public health problem [4-8], where it has been reported to affect 10% to 30% of school-aged children [3]. This condition is still under-described in Madagascar despite its significant prevalence [10].

During a school health inspection, a large outbreak of Gray patch *tinea capitis* was reported. It occurred in East Anosizato public primary school during March 2005 in Antananarivo, Madagascar, and was investigated by a team of Pasteur Institute of Madagascar physicians. The aim of this report is to describe the clinical, epidemiological and biological patterns of this outbreak and to stress the various means that were used to eradicate the disease among the schoolchildren. It is important to illustrate how fast human-to-human transmission can spread and how effective control measures can be implemented.

### Methodology

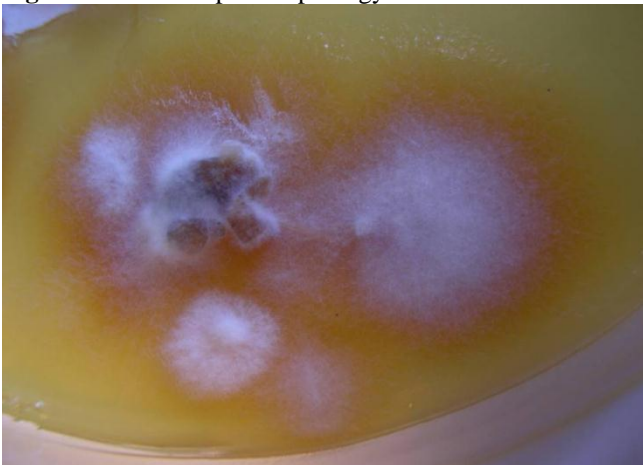We included schoolchildren harbouring dermatophyte infection during an outbreak in March 2005, in the Anosizato Public School, Antananarivo, Madagascar. In total, 42 children out of a total of 723 who were clinically infected with *tinea capitis* (Figure 1) or *corporis* were included. Anosizato district is one of the poorest suburbs of the capital suffering from a lack of food, hygiene, water access,

**Figure 1.** Gray patch tinea capitis (GPTC)



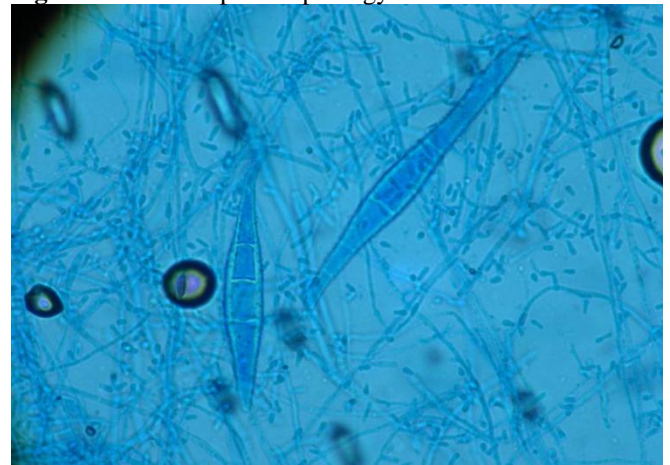
GPTC occurring in a young boy's scalp of Anosizato primary public school, Antananarivo, Madagascar

**Figure 2.** Macroscopic morphology



Three weeks' culture of *Microsporum langeronii* on Sabouraud's Dextrose Agar incubated at 30°C. The colonies are white and flat with a furlike mat having radiating edges (Courtesy of Dr Nelly Contet-Audonneau).

**Figure 3.** Microscopic morphology



To enhance sporulation, a Borelli Medium subculture was processed. Macroconidia are sparsely echinulate and thick walled. Microconidia are unicellular and ovoid (Courtesy of Dr Nelly Contet-Audonneau).

and medical care access. Almost all included children originated from the highlands.

#### Laboratory procedures

Infected hair and scalp scrapings were collected in sampling packets and transferred to the Centre de Biologie Clinique (Institut Pasteur de Madagascar, Antananarivo). Hairs were examined under Wood's ultraviolet light. Direct microscopy slides were prepared by using Potassium Hydroxide (KOH) for scalp scrapings and hair samples were then seeded on two separate plates of Sabouraud's dextrose agar

media containing chloramphenicol, one with and the other without cycloheximide. The agar plates were incubated at a temperature of 27°C for four weeks. Isolated dermatophytes were identified based on growth rate, microscopic morphology of slide cultures, and production and potential diffusion of pigment on Potato dextrose agar, as well as on Baxter media (DIFCO, Nancy, France) and Borelli (Lactrimel) media (Angers, France).

#### Epidemiological investigation

A structured questionnaire was applied to assess the occurrence of well-known risk factors as well as

medication habits. All 42 children were interviewed and the questionnaire was administered in person by Pasteur Institute physicians who completed the questionnaire on their behalf. Analysis of data was done using Epi-Info 6 (CDC, Atlanta, USA) software [5]. Follow-up examinations were performed after four weeks.

#### *Ethical issues*

All samples were used for routine laboratory testing following the school director's request with the parents' oral consent. No further research was performed on the samples. The school director gave oral explanations of the goal of the diagnosis test to both parents and children. She was responsible for treatment information, following drug compliance, and reporting possible adverse effects and hygiene education for the children and their families. All drugs were given to the school director according to a dermatologist's prescription. They were provided free of charge courtesy of a benefactor.

#### **Results**

The 42 children included were aged from 7 to 15 years. The occurrence of tinea capitis (TCA) and tinea corporis (TCO) is summarized in Table 1.

Tinea capitis patterns (n = 27) are displayed in Table 2; their clinical presentation was mostly gray patches (93%). All cases (100%) were fluorescent under Wood's ultraviolet light, ectothrix form at direct examination, and their culture was positive for *Microsporium langeronii* (Figures 2 and 3).

*Microsporium langeronii* (MI) was mostly isolated from scalp alopecia (78%) and may have been involved in tinea corporis: head (34%) and arms (18%) (Table 1).

The questionnaire showed that among the 27 children with TCA, 26 (96%) of the tinea capitis infected children had regular contact with animals (mostly dogs and cats, 62% and 31% respectively). Those animals were located in their homes (62%) or in their neighbours' homes (19%). As for human-to-human transmission risk factors, 27 (100%) of the children had relationships with infected classmates and 19 (70%) reported to have infected brothers and/or sisters at home. Regarding medication, 10 (37%) had already taken medicine prescribed by a doctor while 60% remained untreated. Almost no self-medication was reported (1 case).

All confirmed cases were treated with griseofulvin 500 mg daily for one month and bi-daily topical application of Povidone-iodine 4%. The After

four weeks of treatment, all patients recovered. Since that outbreak, hygiene education has been strengthened among the children's parents and no more cases of tinea capitis occurred within the schoolchildren.

#### **Discussion**

Tinea capitis with gray patch ringworm is common in children and is frequently caused by *Microsporium langeronii* (ML) (anthropophilic species) in Africa [4-8], explaining the recurrence of outbreaks among the poorest countries [2,3,9]. However, very few reports concerning fungi infection in Madagascar and especially dermatophytes have been published [10] even though dermatophyte outbreaks occur frequently in Madagascar primary schools, especially in public primary schools where the children come from the poorest families. We report the occurrence of an outbreak of gray patch tinea capitis due to *Microsporium langeronii* in a public primary school of Antananarivo, including 42 children presenting tinea capitis (mostly gray patch). The cases were mostly related to common anthropophilic tinea capitis associated risk factors such as regular contact with other infected children at school or within the family or the neighbourhood.

One of the main reasons for this outbreak may be related to the lack of hygiene, including very limited water access as stated by the school director. Furthermore, most children suffered from chronic malnutrition which may play a role in the spread of the fungi in relation to the state of relative immunodeficiency [2,9].

In our study, *M. langeronii* was found to be responsible for an outbreak of gray patch tinea capitis (GPTC) among schoolchildren. This pattern is commonly encountered in children in Central Africa [1,7] but could be in contradiction with prior statements regarding Madagascar [10]. In fact, it may not be an actual contradiction since the study by Contet-Audonnet reported cases of tinea capitis in Antsirabe, an isolated town in the Malagasy highlands which is a rather dry and cool area. The fungi species isolated in Antsirabe may be different from those sampled in the capital. Antananarivo is a melting pot of various ethnic groups originating from various biotopes. One of these biotopes is the eastern coast area with equatorial weather similar to that which may be encountered in Central Africa where *M. langeronii* has been frequently reported. Further studies of GPTC in all provinces of Madagascar should be conducted for a better understanding of *M.*

**Table 1.** Patients' infection patterns at Anosizato Public Primary School, March 2005

	<i>n</i>	%
Total schoolchildren	723	100
Tinea capitis or/and corporis infected children	42	5.8%
Tinea capitis infected children	27	3.7%
Tinea corporis infected children	32	4.4%
Tinea capitis and tinea corporis infected children	17	2.3%

**Table 2.** Tinea capitis patterns at Anosizato Public Primary School, March 2005 (n = 27)

	<i>n</i>	%
Clinical feature: Gray Patch	25	93
Wood's light: positive	27	100
Direct examination: ectothrix form	27	100
Culture: Presence of <i>M. langeronii</i>	27	100

*langeronii* distribution and epidemiology in the island. Also, to highlight the risk factors associated with this disease, control groups should be carefully set up.

Self-made treatments of tinea capitis in Madagascar mostly rely on lemon and honey but the efficiency of this home remedy has not been proven. In addition, the cost of topical medication for tinea capitis (azoles) is unaffordable for most of the Malagasy population. In our study, we used Povidone-iodine 4% which is an affordable topical treatment with antifungal efficiency. Oral medication was based on griseofulvin. As indicated above, the medication was effective and all infected children recovered. No mention of any adverse effect has been recorded to date.

The treatment regimen with griseofulvin is standard, but the use of polividone iodine is not internationally recommended. The main reasons for its use were as follows: 1) it contains the spread of the fungi [11] in a context of poor hygiene and decreases any further risk of transmission to schoolmates as well as to relatives; 2) it is recommended by Médecins Sans Frontières (MSF) Practical Guidelines [12]; 3) it is a much more affordable therapeutic alternative than topical azoles. Recent international therapeutic guidelines [13,14] do not take price into consideration, even if it is a fundamental problem in developing countries, a practice which prevents access to basic drugs for the patients. Therefore, new MSF guidelines advise the use of Whitfield ointment twice daily for at least two weeks and if necessary for the entire duration of treatment with griseofulvin [15].

Further hygiene advice was given by the school director to the parents. Additionally, a few months after the investigation, all children were given a daily meal at the school to ensure a minimum food intake according to a national school plan. Since that date, no more cases of tinea capitis have been reported.

Despite this success story where education and hygiene improvement eradicated the fungi in a Malagasy school, the remaining cases of ringworm on the scalp of the children's relatives and friends outside the school may maintain transmission of tinea capitis. Without general improvement of hygiene education and urban development, sustainable control of tinea capitis infections will be difficult to achieve.

### Acknowledgements

We would like to extend our appreciation to Dr Philippe Mauclère, Director of the Pasteur Institute of Madagascar, for his authorization to conduct this study and for financial support. We are grateful to Dr Rahelisoa Ratahijanahary Hantamalala Voahangy, the School Director, for welcoming our team into Anosizato Primary Public school. We also thank Dr Fahafahantsoa Rapelanoro Rabenja for treatment advice and Dr Cecile Mourlan for providing affordable medication.

### References

1. Gupta AK and Summerbell RC (2000) Tinea capitis. *Med Mycol* 38: 255-287.
2. Havlickova B, Czaika VA, Friedrich M (2008) Epidemiological trends in skin mycoses worldwide. *Mycoses* 4: 2-15.
3. Badillet G (1988) Dermatophytes and immigration. *Ann Biol Clin* 46: 37-43.
4. Sidat Mohsin M, Correia D, Buene Titos P (2007) Tinea capitis among children at one suburban primary school in the city of Maputo, Mozambique. *Rev Soc Bras Med Trop* 40: 473-475.
5. Ménan EI, Zongo-Bonou O, Rouet F, Kiki-Barro PC, Yavo W, N'Guessan FN, Koné M (2002) Tinea capitis in schoolchildren from Ivory Coast (western Africa): A 1998-1999 cross-sectional study. *Int J Dermatol* 4: 204-207

6. Schmeller W, Baumgartner S, Dzikus A (1997) Dermatophytomycoses in children in rural Kenya: the impact of primary health care. *Mycoses* 40: 55-63.
7. Testa J, Kaïmba C, Georges A, Delmont J (1992) Epidemiology of Tinea capitis in Bangui (Central African Republic). *Bull Soc Pathol Exot* 85: 395-396.
8. Dupouy-Camet J, Tourte-Schaefer C, Viguie C, Nicolle L, Heyer F, Lapierre J. (1988) Epidemiology of tinea of the scalp in Togo. *Bull Soc Pathol Exot Filiales* 81: 299-310.
9. Seebacher C, Bouchara JP, Mignon B (2008) Updates on the epidemiology of dermatophyte infections. *Mycopathologia* 166: 335-352.
10. Contet-Audonneau N, Grosjean P, Razanakolona LR, Andriantsinjavina T, Rapelanoro R (2006) Tinea capitis in Madagascar: a survey in a primary school in Antsirabe. *Ann Dermatol Venereol* 133: 22-25.
11. Scott EM, Gorman SP, McGrath (1996) An assessment of the fungicidal activity of antimicrobial agents used for hard-surface and skin disinfection. *J Clin Hosp Pharm* 11: 199-205.
12. Médecins Sans Frontières (1993) Essential Drugs - Practical Guidelines, Paris, MSF Edition, 286 p.
13. Meadows-Oliver M (2009) Tinea capitis: diagnostic criteria and treatment options. *Dermatol Nurs* 21: 281-286.
14. Sarabi K and Khachemoune A Tinea capitis (2007): a review. *Dermatol Nurs* 19: 525-530.
15. Médecins Sans Frontières (2010) Clinical guidelines – Diagnosis and treatment manual, Paris, MSF Edition, 322 p.

**Corresponding author**

Jean-François Carod  
23 Rue de la Boussière  
39200 Avignon les Saint Claude  
France  
Telephone: + 33 3 84 41 33 78  
Email: jfcarod@yahoo.es

**Conflict of interests:** No conflict of interests is declared.