

## Case report

# Primary echinococcal cyst in the axillary region

Mustafa Ozsoy<sup>1</sup>, Celalettin Keles<sup>1</sup>, Mumtaz Kahya<sup>1</sup>, Gonul Keles<sup>2</sup>

<sup>1</sup>Department of General Surgery, Manisa State Hospital, Manisa, Turkey

<sup>2</sup>Department of Anaesthesiology, Celal Bayar University, Faculty Of Medicine, Manisa, Turkey

### Abstract

**Introduction:** Human hydatid disease is a parasitic infection caused by the larval form of *Echinococcus granulosus*. It has worldwide distribution and is endemic in many countries, especially the Mediterranean region. It most commonly affects the liver and lungs although multi-organ involvement has been observed in 20-30% of patients.

**Case report:** A 45-year-old woman presented to a gynaecologist because of a mass in the axillary region. Her mother and her two sisters were undergoing treatment for breast cancer. In her examination, a hard, semi-mobile, painless mass was found that was approximately 3 cm in diameter. Axillary ultrasonography showed lymphadenopathy. No abnormality was found in mammographic examination of either breast, or in abdominal ultrasonography and chest X-ray. Occult breast cancer was suspected but when the mass was excised for pathological examination the biopsy showed a hydatid cyst with germinative membranes. Subsequent lung, abdomen and brain tomography scans, whole body bone scintigraphy and hydatid serology, including indirect haemagglutination and enzyme-linked immunosorbent assay, were negative. For these reasons an isolated axillary hydatid cyst was diagnosed.

**Conclusion:** Parasitic cysts should be considered in endemic areas in patients presenting with a soft tissue mass in the axillary region. Imaging methods should be planned to include this possibility.

**Key words:** Hydatid Cyst; Breast Cancer; Axilla

*J Infect Dev Ctries* 2011; 5(11):825-827.

(Received 19 September 2010 - Accepted 12 March 2011)

Copyright © 2011 Ozsoy *et al.* This is an open-access article distributed under the Creative Commons Attribution License, which permits unrestricted use, distribution, and reproduction in any medium, provided the original work is properly cited.

### Introduction

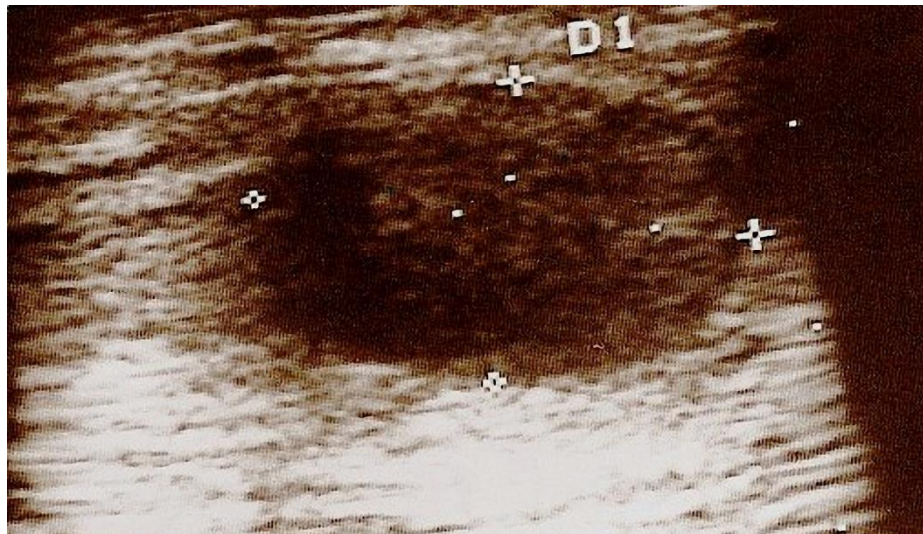
Human hydatid disease is a parasitic infection caused by the larval form of *Echinococcus granulosus*. *E. granulosus* has worldwide distribution and is endemic in many countries, especially the Mediterranean region, Australia, South America, the Middle East, South Africa, and Eastern Europe [1,2]. Turkey is also an endemic area for hydatid diseases [2,3].

According to Barret and Thomas [4], hydatid cysts have a predilection to locate in liver (60%) and lungs (30%). Other organs of the body including brain, heart, bones, muscle, kidney, and pancreas may also be affected. Multi-organ involvement has been reported in 20-30% of hydatid disease cases [5]. Many uncommon locations, such as the axilla, have been reported. Because hydatid cysts are rarely present in the axilla, they can be confused with other diagnoses and treatment can be affected. Here we reported an axillary hydatid cyst which was initially suspected to be occult breast cancer.

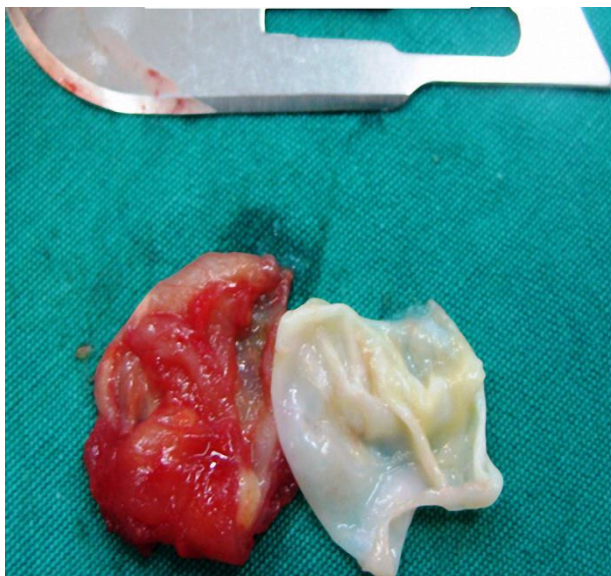### Case report

A 45-year-old woman presented to a gynecologist in August 2009 because of a mass in

the axillary region which could be felt by hand for the past two months. In her examination, a hard, semi-mobile, painless mass was found and she was referred to the general surgery clinic with a suspicion of breast cancer. Although she had no personal history of cancer, her mother and her two sisters were currently having treatment for breast cancer. No abnormality was found in the examination of the patient's two breasts and right axilla. A mass was found in the left axillary region which was hard, painless and adherent to adjacent tissues. No abnormality was found in the mammographic examination of her breasts, or in abdomen ultrasonography and chest X-ray. Axillary ultrasonography showed a mass of approximately 3 cm in diameter and lymphadenopathy was diagnosed because of the differentiation from adjacent tissues and lack of inflammation (Figure 1). The patient underwent surgery under general anaesthesia for sampling of the mass on September 2009. At operation it was confirmed that the mass was adherent to adjacent tissues. A cystic component not visible during preoperative examinations was also observed. The mass was carefully excised for pathological examination with its structure protected by dissection. Analysis of the

**Figure 1.** Preoperative image of hydatid cyst, mimicking lymphadenopathy

biopsy showed a hydatid cyst with germinative membranes. (Figure 2) Tissue samples, prepared for microscopic examination by fixation with 10% formalin, alcohol and immersion in paraffin blocks, showed eosinophilic staining of the lamellar cuticular membrane and cyst wall surrounded by granulomatous inflammation. These findings supported the diagnosis of a hydatid cyst. The patient had an uneventful postoperative period. Lung, abdomen and brain tomography scans, whole body bone scintigraphy and hydatid serology, including indirect haemagglutination and enzyme-linked immunosorbent assay, were all negative. An isolated axillary hydatid cyst was therefore diagnosed. Treatment with albendazole was started when the patient was discharged from the hospital. It has been one year since her surgery and follow-up examinations have shown no relapse.

**Figure 2.** The excised cyst and its germinative membrane

## Discussion

Hydatid cyst disease is still a major health problem in agricultural countries including Turkey [6]. Its prevalence is estimated to be between 2-3 million cases per year [7,8]. The parasite is named *Echinococcus granulosus* and humans can be an incidental intermediary host in the life cycle of the parasite. Although cysts are most commonly located in the liver (50-60%) and the lungs (20-30%), multi-organ involvement is seen in 20-30% of cases [8,9]. The parasites form a cystic mass that grows constantly but slowly. The cyst may be present for many years in the organ in which they are located with no clinical symptoms or signs [10]. Although hydatid cysts are rarely detected in the breast, axillary region and chest wall, the exact incidence of extra hepatic involvement is unclear [11]. There are eight case reports of axillary *Echinococcus granulosus* cysts in the literature to date all from endemic areas and this report is the ninth case [12]. The main complaint of patients, excluding ours, has been pain and a sense of malaise. As in our case, clinical findings and physical examination did not reveal the correct diagnosis. Our initial diagnosis was occult breast carcinoma based on the clinical findings, physical examination and medical history of the patient. As Turkey is an endemic area for hydatid disease, this should be in the differential diagnosis for patients presenting with tissue masses. *Echinococcus granulosus* infection may mimic malignancy because of sudden enlargement of the cyst and the formation of structural deformities in the tissue over time [13, 14]. Unilocular intermediary and hyper intense hydatid cysts have been reported

to be confused with conditions such as sarcoma and conglomerate lymphadenopathies [15]. Clinicians should consider the possibility of hydatid cyst as well as malignancy in axillary soft tissue masses. The presence of a primary axillary hydatid cyst may be explained by hydatid embryos migrating from the liver and the lungs to the axillary region. Secondary progression by spread of scolexes to neighboring tissues following surgical or spontaneous rupture of the hydatid cyst can also occur [16,17]. No additional foci were encountered in postoperative examination supporting migration as the reason for a cyst in this location.

Although imaging methods usually exhibit nonspecific findings, they may be helpful for making the diagnosis. Ultrasonography, computed tomography, and magnetic resonance imaging can image the association of the cyst with neighboring tissues, the internal laminar wall of the cyst, and intraluminal daughter cysts [17]. Serologic tests can confirm that the cyst is hydatid in origin and are also useful for follow-up, although it should be noted that such tests can be false positive in up to 33% of cases [18]. Diagnostic aspiration cytology is also helpful but carries the risk of anaphylaxis and dissemination of the hydatid cyst [19]. The main treatment for hydatidosis is surgery and total cystectomy is recommended for soft tissue hydatidosis. Rupture of the cyst must be avoided to prevent recurrence [20].

## Conclusion

Axillary hydatidosis is a rare and frequently overlooked public health problem. Eradication of the causative agent is important for disease control. In endemic areas, a hydatid cyst may be the diagnosis in a patient presenting with a soft tissue mass in the axillary region and imaging methods should be arranged to investigate this possibility.

## References

- Petersen C and Mills J (1994) Parasitic infections. In: Murray JF and Nadel JA, editors. Textbook of respiratory medicine, Philadelphia, PA: WB Saunders, pp. 1201-1243.
- Doğan R, Yüksel M, Cetin G, Süzer K, Alp M, Kaya S, Unlu M, Moldibi B (1989) Surgical treatment of hydatid cysts of the lung: report on 1055 patients. *Thorax* 44: 192-199.

- Kürkçüoğlu IC, Eroğlu A, Karaoğlanoğlu N, Polat P (2002) Tension pneumothorax cases associated with hydatid cyst rupture. *J Thorac Imaging* 17: 78-80.
- Barret NR and Thomas D (1952) Pulmonary hydatid disease. *Br J Surg* 40: 222-44.
- Bickers WM (1970) Hydatid disease of the female pelvis. *Am J Obstet Gynecol* 107: 477-483.
- Capoglu I, Unuvar N, Erdogan F, Yilmaz O, Caydere M (2002) A hydatid cyst of the thyroid gland. *J Int Med Res* 30: 206-209.
- Budke CM (2006) Global socioeconomic impact of cystic echinococcosis. *Emerg Infect Dis* 12: 296-303.
- Wani RA, Malik AA, Chowdri NA, Wani KA, Naqash SH (2005) Primary extrahepatic abdominal hydatidosis. *Int J Surg* 3: 125-127. Epub 2005 Aug 1.
- Rauhofer U, Prager G, Hörmann M, Auer H, Kaserer K, Niederle B (2003) Cystic echinococcosis of the thyroid gland in children and adults. *Thyroid* 13: 497-502.
- Kireşi DA, Karabacakoglu A, Odev K, Karaköse S (2003) Uncommon locations of hydatid cysts. *Acta Radiol* 44: 622-636.
- Emany H, Asadian D (1976) Unusual Presentation Of Hydatid Disease. *Am J Surg* 132: 403-405.
- Losanoff JE, Richman BW, Jones JW (2004) Primary Hydatid Cyst Of The Axilla. *ANZ J Surg* 74: 393-394.
- Gökçe C, Patiroğlu T, Akşehirli S, Durak AC, Keleştimur F (2003) Hydatid cyst in the thyroid gland diagnosed by fine-needle aspiration biopsy. *Thyroid* 13: 987-989.
- Erkiliç S, Ozsaraç C, Koçer NE, Bayazit YA (2004) Hydatid cyst of the thyroid gland in a child. *Int J Pediatr Otorhinolaryngol* 68: 369-371.
- Unal AE, Ulukent SC, Bayar S, Demirkan A, Akgül H (2001) Primary hydatid cyst of the axillary region: report of a case. *Surg Today* 31: 803-805.
- Sapunar J, Bahamondes L (1995) Hydatidosis of the humerus complicated with fracture, bacterial infection, fistula, and extraosseous localization. *Bol Chil Parasitol* 50: 37-41.
- Prousalidis J, Tzardinoglou K, Sgouradis L, Katsolis C, Aletras H (1998) Uncommon sites of hydatid disease. *World J Surg* 22: 17-22.
- Biava MF, Dao A, Fortier B (2001) Laboratory diagnosis of cystic hydatid disease. *World J Surg* 25: 10-14. 26
- Von Sinner WN, Nyman R, Linjawi T, Ali AM (1995) Fine needle aspiration biopsy of hydatid cysts. *Acta Radiol* 36: 168-72.
- Aydin U, Yazici P, Onen Z, Ozsoy M, Zeytinlu M, Kiliç M, Coker A (2008) The optimal treatment of hydatid cyst of the liver: radical surgery with a significant reduced risk of recurrence. *Turk J Gastroenterol* 19: 33-39.

## Corresponding author

Mustafa Ozsoy, MD  
1819/11 Sok. No: 16/10 İstasyonaltı Mahallesi  
Çiğli, İzmir, 35630, Turkey  
Telephone: +900 236 – 238 02 98  
Fax: +900 236 – 232 17 48  
Email: dr.mustafaoszoy@gmail.com

**Conflict of interests:** No conflict of interests is declared.