

Case Report

Three cases of cutaneous myiasis caused by *Cordylobia rodhaini*

Stefano Veraldi¹, Stefano Maria Serini¹, Luciano Süss²

¹ Department of Pathophysiology and Transplantation, University of Milan, I.R.C.C.S. Foundation, Cà Granda Ospedale Maggiore Policlinico, Milan, Italy

² Postgraduate Course in Tropical Medicine, University of Milan, Milan Italy

Abstract

Cordylobia sp. is a fly belonging to the Calliphoridae family. Three species of *Cordylobia* are known: *C. anthropophaga*, *C. rodhaini* and *C. ruandae*. The *C. rodhaini* Gedoelst 1909 lives in Sub-Saharan Africa, especially in rain forest areas. Usual hosts are rodents and antelopes. Humans are accidentally infested. Myiasis caused by *C. rodhaini* has been very rarely reported in the literature. We present three cases of *C. rodhaini* myiasis acquired in Ethiopia and Uganda.

Key words: cutaneous myiasis; *Cordylobia* sp.; *Cordylobia rodhaini*

J Infect Dev Ctries 2014; 8(2):249-251. doi:10.3855/jidc.3825

(Received 25 May 2013 – Accepted 05 August 2013)

Copyright © 2014 Veraldi *et al.* This is an open-access article distributed under the Creative Commons Attribution License, which permits unrestricted use, distribution, and reproduction in any medium, provided the original work is properly cited.

Introduction

Cordylobia sp. is a fly belonging to the Calliphoridae family. Three species of *Cordylobia* are known: *C. anthropophaga*, *C. rodhaini* and *C. ruandae*. *C. rodhaini* Gedoelst 1909 was first described by Gedoelst in 1905. It was initially named “Lund’s fly”, after the surname of Captain Lund, who is considered the first patient affected by myiasis due to *C. rodhaini*: in fact, a larva was extracted from his arm in Congo [1]. *C. rodhaini* lives in Sub-Saharan Africa, especially in rain forest areas. Usual hosts are rodents such as *Cricetomys gambianus*, the “gambian rat” or “northern giant pouched rat” and small antelopes (*Cephalophus dorsalis*, the “bay duiker” and *Cephalophus grimmi*) [1]. Humans are accidentally infested.

Myiasis caused by the larvae of *C. rodhaini* has been very rarely reported in the literature: to our knowledge, only ten cases were published since 1970 [1-9].

We present three cases of *C. rodhaini* myiasis acquired in Ethiopia (one patient) and Uganda (two patients). All patients were treated at the Department of Pathophysiology and Transplantation, University of Milan, Italy.

Case Reports

We observed three Caucasian patients, a man and two women, aged 59, 58 and 52 years, respectively.

Locations of the lesions were on the right leg for the first patient; on the abdomen, pubis, scrotum and left thigh, for the second patient; in the left shoulder for the third patient. Two patients presented with a lesion each, and a patient with five lesions. Two patients had nodular-ulcerative lesions and one a furuncular lesion (Figure 1-2). Patients’ characteristics are reported in Table 1. In all patients a single third stage larva of *C. rodhaini* was extracted (Figure 3). Diagnosis of third stage larva of *C. rodhaini* was based on the typical random distribution of tiny hooks on the surface of the larva.

Discussion

The life of the adult of *C. rodhaini* is approximately one month [1]. The female lays approximately 500 eggs in dry soil; however, eggs may be laid also on clothing. The eggs hatch 2-4 days later. On contact with the skin of a suitable host, the larvae penetrate. Twelve-15 days later, the larvae develop into second and third stage, during the latter the larvae can reach the length of 1.5 cm. Mature larvae may emerge from the skin spontaneously [6].

All published cases of myiasis due to *C. rodhaini* are related to travellers who visited sub-Saharan Africa: Cameroon [2,4], Kenya [3], Ethiopia [1,6,9] and Ghana [8].

Table 1. Patients' characteristics

Patient	Sex	Age	Lesions localization	Lesions number and morphology	Country of infestation
1	F	52	Right leg	One nodular-ulcerative lesion	Ethiopia
2	M	59	Abdomen, pubis, scrotum, left thigh	Five nodular-ulcerative lesions	Uganda
3	F	58	Left shoulder	One furuncular lesion	Uganda

Figure 1. Patient 1. Nodular-ulcerative lesion at the right leg

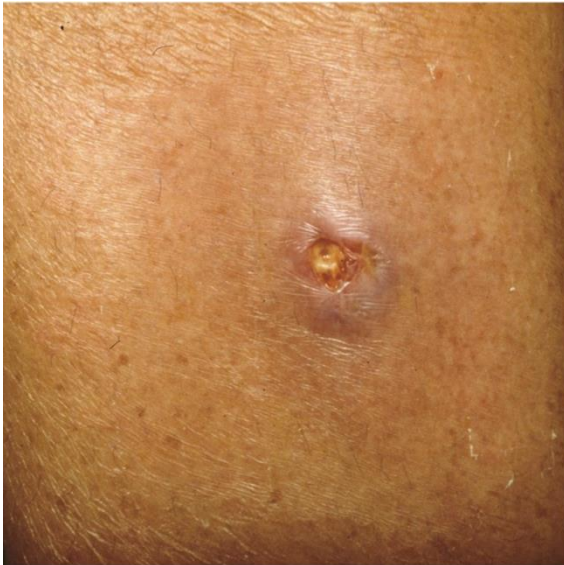

Figure 2. Patient 2. Nodular-ulcerative lesion at the pubis

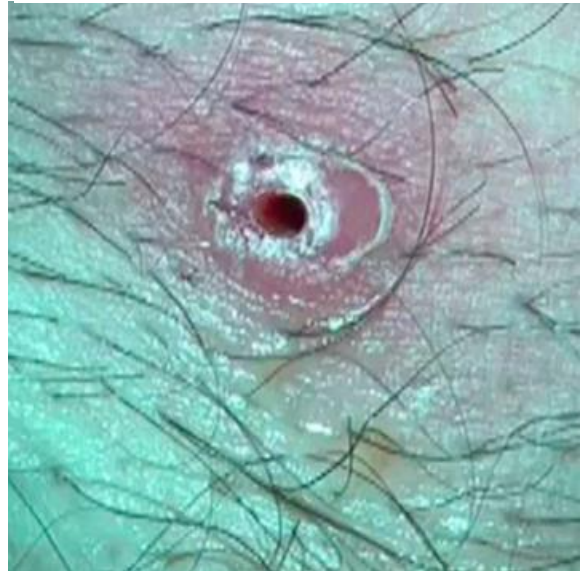
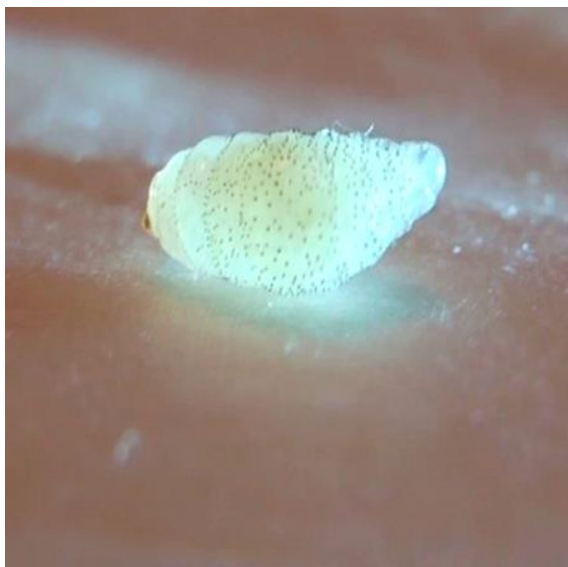

Figure 3. Third stage larva of *Cordylobia rodhaini*



This myiasis is clinically similar to the form caused by *C. anthropophaga* and *Dermatobia hominis*. At first, an inflammatory papule appears; it enlarges becoming a nodule with a central opening, from which a serous fluid oozes. The typical clinical appearance is the same as a nodular-ulcerative lesion or a furuncle, this is where the term “furuncular myiasis” [8] comes from. The myiasis is accompanied by pain [8,9] or burning sensation [1]. The number of the lesions is extremely variable: from one to 15 lesions can be observed on patients. Even a patient with 150 lesions located on the scalp, forehead, neck, chest, limbs, back, pubis, genitalia and buttocks has been reported [1,6]. Systemic symptoms are very rare, although can be sometimes severe, such as fever [1,6] as well as cervical, axillary, trochlear and inguinal lymphadenopathy [6]. Laboratory abnormalities such as neutrophilic leucocytosis are rare [1,6].

As previously mentioned, mature larvae may emerge from the skin spontaneously [6], for this reason often no treatment is necessary. In order to force the larvae to emerge some authors applied petrolatum [7,8]. In our patients, the leakage of the larvae was obtained by means of a gentle manual pressure at the edge of the lesions. A hyperpigmentation may persist on the skin of the affected area for several months [6].

References

1. Pampiglione S, Schiavon S, Candiani G, Fioravanti ML (1991) Osservazioni cliniche e parassitologiche su di un caso di miasi foruncolosa disseminata da *Cordylobia rodhaini* nell'uomo in Etiopia. *Parassitologia* 33: 159-167.
2. Kremer M, Lenys J, Basset M, Rombourg H, Molet B (1970) Deux cas de myiase à *Cordylobia rodhaini* contractée au Cameroun et diagnostiquée en Alsace. *Bull Soc Pathol Exot* 63: 592-596.
3. Scholten TH, Hicks RJ (1973) Myiasis by *Cordylobia rodhaini* contracted in Africa and diagnosed in Canada. *Can J Public Health* 64: 488-489.
4. Hori E, Yamaguchi K, Wada Y, Yamamura H, Kano R, Shinonaga S, Fujino N (1984) Three human cases of myiasis caused by larvae of *Cordylobia* (Calliphoridae) in Cameroon and Côte d'Ivoire, West Africa. *Jpn J Med Zool* 35: 87-90.
5. Hubsch HM, Kalvelage H, Bercher M (1989) Fliegenlarvenbefall der Haut (Cutane Myiasis) durch *Cordylobia rodhaini*. *Akt Dermatol* 15: 243-245.
6. Pampiglione S, Schiavon S, Fioravanti ML (1992) Extensive furuncular myiasis due to *Cordylobia rodhaini* larvae. *Br J Dermatol* 126: 418-419.
7. Geary MJ, Hudson BJ, Russell RC, Hardy A (1999) Exotic myiasis with Lund's fly (*Cordylobia rodhaini*). *Med J Aust* 171: 654-655.
8. Tamir J, Haik J, Schwartz E (2003) Myiasis with Lund's fly (*Cordylobia rodhaini*) in travelers. *J Travel Med* 10: 293-295.
9. Hannam P, Khairnar K, Downey J, Povich J, Ralevski F, Pillai DR (2011) Cutaneous myiasis in traveler returning from Ethiopia. *Emerg Infect Dis* 17: 2385-2386.

Corresponding author

Stefano Veraldi,
Department of Pathophysiology and Transplantation,
University of Milan, I.R.C.C.S. Foundation,
Cà Granda Ospedale Maggiore Policlinico, Milan, Italy
Email: stefano.veraldi@unimi.it

Conflict of interests: No conflict of interests is declared.