

## Case Report

# Mitral valve endocarditis caused by *Pseudomonas aeruginosa*: a case report

Marija Polovina<sup>1</sup>, Tatjana Potpara<sup>1,4</sup>, Ivana Milošević<sup>2,4</sup>, Jelena Stepanović<sup>1,4</sup>, Momčilo Jovanović<sup>3</sup>, Milorad Pavlović<sup>2,4</sup>

<sup>1</sup> Cardiology Clinic, Clinical Center of Serbia, Belgrade, Serbia

<sup>2</sup> Clinic for Infective and Tropical Diseases, Clinical Center of Serbia, Belgrade, Serbia

<sup>3</sup> Clinic for Abdominal Surgery, Clinical Center of Serbia, Belgrade, Serbia

<sup>4</sup> Medical Faculty, University of Belgrade, Belgrade, Serbia

### Abstract

Previously, endocarditis caused by *Pseudomonas aeruginosa* mostly involved right-sided valvular infection and generally carried a good prognosis. Recently, changes have been observed in the occurrence and clinical presentation of pseudomonal endocarditis, with increasing incidence of nosocomial infections and involvement of the aortic and mitral valves. Still, pseudomonal left-sided endocarditis is rare, but is frequently associated with complications and high mortality rates.

A case of a high-risk patient with coronary artery disease and left-ventricular dysfunction, successfully treated for pseudomonal mitral valve endocarditis complicated by splenic abscess formation, is presented here.

**Key words:** endocarditis; mitral valve; *Pseudomonas aeruginosa*; spleen; abscess

*J Infect Dev Ctries* 2014; 8(5):676-679. doi:10.3855/jidc.3816

(Received 22 May 2013 – Accepted 30 December 2013)

Copyright © 2014 Polovina *et al.* This is an open-access article distributed under the Creative Commons Attribution License, which permits unrestricted use, distribution, and reproduction in any medium, provided the original work is properly cited.

### Introduction

*Pseudomonas aeruginosa* endocarditis is uncommon (< 1.8% of cases) [1,2]. Previous reports mostly described right-sided heart involvement in intravenous drug abusers [3]. Recently, a change in the epidemiology and clinical presentation of *P. aeruginosa* infections has been noted, with most cases occurring in hospital settings and affecting the left side of the heart [2,4-8]. The clinical course of left-sided *P. aeruginosa* endocarditis is usually severe and complicated, with high mortality rates despite adequate treatment [4-8].

As an illustration of the changing epidemiology and difficulties in treatment of pseudomonal endocarditis, we report a case of a patient with coronary artery disease and left-ventricular dysfunction, who was successfully treated for pseudomonal mitral valve endocarditis complicated by splenic abscess formation.

### Case Report

A 60-year-old male was admitted to the intensive care unit (ICU) of the Clinical Center of Serbia with an acute anterior myocardial infarction and referred to percutaneous coronary intervention (PCI) with

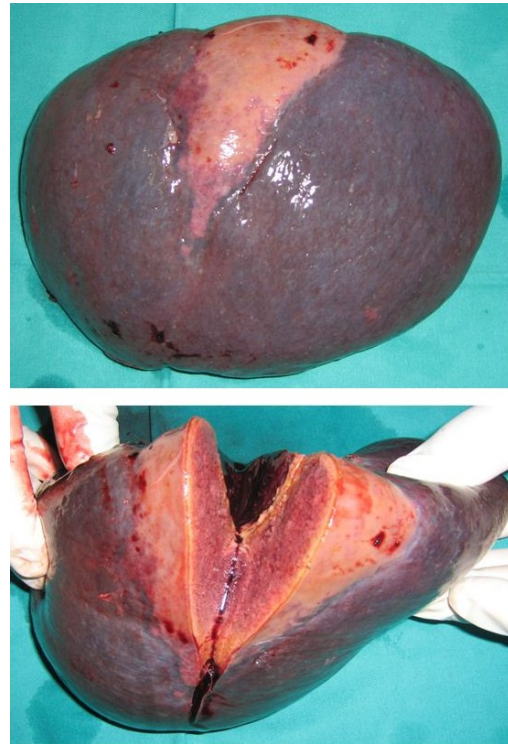
implantation of a drug-eluting stent in an infarct-related artery. Pre-discharge transthoracic echocardiographic examination (TTE) revealed a dilated left ventricle with reduced ejection fraction (35%) and functional mitral regurgitation (MR 3+).

Two weeks later, low-grade fever occurred and continued for three weeks (during which the patient did not consult doctors, nor had any invasive procedures) until the patient's condition exacerbated with the occurrence of high fever (39.9°C) and weakness. On readmission to the ICU, he was febrile (38.4°C), normotensive, with an apical heart murmur (grade 3/6, unchanged compared to previous findings), while liver and spleen were palpable at the costal rib. Abnormalities in laboratory analyses were detected: anemia (85 g/L), leukocytosis ( $15.7 \times 10^9$ ; 89% neutrophils), erythrocyte sedimentation rate 82/h, fibrinogen 9.7 g/L, C-reactive protein (CRP) 181mg/L, and hypoalbuminemia 28 g/L. Three sets of blood cultures were collected within three to six hours, before antibiotics were administered, and then an empirical antibiotic combination of vancomycin (1 g I.V. q12h), ceftriaxone (2 g I.V. q24h), and rifampicin (0.6 g q24h) was instituted in accordance with the epidemiological situation suggestive of a possible

staphylococcal infection acquired during previous cardiac catheterization. TTE on admission was unchanged compared with previous TTE, without visible vegetations or worsening MR. Unfortunately, transesophageal echocardiographic examination (TEE) was not available at the time. Chest radiography showed no signs of pulmonary congestion or inflammation. Repeated abdominal ultrasound and computed tomography (CT) revealed an enlarged liver (174 mm) and spleen (164 mm) without signs of abscess formation. Endocranial CT scan was unremarkable. All three sets of blood cultures came back positive for *P. aeruginosa* susceptible to piperacillin, piperacillin-tazobactam, meropenem, imipenem, ceftriaxone, ceftazidime, cefepime, gentamicin, amikacin, and ciprofloxacin. After six days of empirical antibiotic therapy, treatment with piperacillin-tazobactam (4.5 g I.V. q8h) and amikacin (0.5g I.V. q12h) was started in accordance with the antibiogram. Within several days, the patient became afebrile and remained so until discharge five weeks later. Seven days after discontinuation of a five-week antibiotic course, laboratory findings revealed normal white blood cell count ( $7.4 \times 10^9$ ) and fibrinogen levels (3.7 g/L), while CRP levels decreased (13.6 mg/L). Three sets of blood cultures collected seven days following cessation of antibiotics were sterile. During antibiotic treatment, the patient was repeatedly examined by TTE, including the final examination at the end of the hospital stay, but control findings revealed no signs of new valvular dysfunction suggestive of endocarditis, including development of vegetations. We concluded that the patient had suffered from pseudomonal sepsis without evidence of infectious spread.

Three weeks after discharge, the patient became febrile again. On readmission to the ICU, he was febrile (38.2°C), normotensive, with an aggravated apical heart murmur (grade 4/6) and had signs of heart failure, hepatomegaly, and splenomegaly. Laboratory analyses demonstrated increased markers of inflammation (CRP 269 mg/L, fibrinogen 7.0 g/L, erythrocyte sedimentation rate 74/h, hypoalbuminemia 27 g/L, hemoglobin 67 g/L, and leukocytosis  $12.3 \times 10^9$ ). *P. aeruginosa* susceptible to the same antibiotics was isolated from blood cultures collected on admission, while TTE and TEE revealed multiple small vegetations on the posterior mitral valve leaflet with worsened MR (4+). Previous antibiotic combination (piperacillin-tazobactam 4.5g I.V. q8h and amikacin 0.5 g I.V. q12h) was reinitiated, but the patient remained febrile while four sets of blood

**Figure 1.** Surgically removed spleen with an abscess



cultures were positive for *P. aeruginosa*. Early cardiac surgery was considered, but since the patient was hemodynamically stable, the decision was made to try to establish the control over the infection with antibiotics before referring him to cardiac surgery. Ten days later, the patient complained of a dull pain under the left costal rib. Abdominal CT scan demonstrated an enlarged spleen (190 mm) with multiple hypodense zones suggestive of a splenic abscess. The antibiotic regimen was changed to high doses of meropenem (2 g I.V. q8h), and the patient was referred to the Department of Abdominal Surgery for a splenectomy. Since the patient was treated with aspirin + clopidogrel for a drug-eluting stent implanted less than three months before, clopidogrel was discontinued five days before surgery while aspirin and heparin were continuously administered, with reinstatement of clopidogrel immediately after surgery. The removed spleen weighed 1000 g and revealed well demarcated infarction with an abscess (Figure 1). After abdominal surgery, high-dose meropenem monotherapy (2 g I.V. q8h) was continued for six weeks. The patient became afebrile and blood cultures sterilized. However, TEE revealed persistence of small vegetations on the posterior mitral valve leaflet with MR (4+). The patient was referred to the Department of Cardiac Surgery. Clopidogrel was discontinued for five days

preoperatively, while aspirin and heparin were continuously administered, and successful valve replacement surgery was performed without complications, with reinstatement of clopidogrel after surgery. The patient fully recovered during a six-week postoperative meropenem course (0.5 g I.V. q8h). Laboratory analysis on discharge demonstrated normalization of most inflammatory markers (white blood cell count  $8.6 \times 10^9$ , CRP 5.8 mg/L, fibrinogen 4.2 g/L, erythrocyte sedimentation rate 38/h). Blood cultures remained sterile after cessation of antimicrobials. Twelve months later, he was symptom-free and in good health.

## Discussion

In keeping with reported changes in the epidemiology and clinical presentation of pseudomonal endocarditis [2,4-8], our case describes mitral valve involvement in a high-risk patient with multiple predisposing conditions for nosocomial infection. It is of particular importance that valvular infection was complicated by splenic abscess, which is a rare complication of endocarditis nowadays. A long three-week period of smoldering infection culminating in sepsis in our case is consistent with observations that pseudomonal infection might have a subacute onset [2,5]. An apparently successful treatment during the first hospitalization for febrile state led us to erroneously believe that the patient had been cured. Unfortunately, since TEE was not done during that hospitalization, it could be argued that small valvular vegetations indiscernible by TTE were missed; nevertheless, repeated TTEs performed during the hospital stay showed no signs of new valvular dysfunction suggestive of endocarditis. Importantly, a lengthy five-week antibiotic treatment in our case was insufficient to secure eradication of the infection. However, bloodstream *P. aeruginosa* infections are difficult to eradicate, and relapses after seemingly successful treatments are not infrequent [9].

A consensus on optimal management of *P. aeruginosa* endocarditis has not been reached [2,4]. A combination of antibiotics, typically with antipseudomonal penicillin and an aminoglycoside, is considered a cornerstone of medical therapy; however, different antibiotic combinations or a single antibiotic regimen (e.g. beta-lactam or carbapenem) have also proven successful [2,10]. Our patient was initially treated with a high-dose combination of piperacillin-tazobactam + amikacin. This antibiotic regimen was reinstated when he was hospitalized for the second time with signs of infection, but his continuous febrile

state and the development of splenic abscess were clear indicators that the therapy was inadequate despite evidence of *in vitro* drug susceptibility. The exact mechanism responsible for the observed discrepancy between *in vitro* and *in vivo* antibiotic effectiveness remains elusive, but the emergence of antibiotic resistance during therapy has been described for *P. aeruginosa* [6]. Meropenem was then introduced at the highest recommended dose, considering that high antibiotic concentrations are needed to saturate *P. aeruginosa* glycoalkaloid and secure antibiotic penetration in left-sided endocarditis [11,12].

Although splenic abscess is presently a rare complication of endocarditis (2.4%-5%), it occurs in up to 13% of *P. aeruginosa* valvular infections [4,13,14]. Large, mobile vegetations and failure of vegetations to regress during antimicrobial treatment are predictive of embolism [14]. In the present case, small vegetations on echocardiography were not suggestive of high embolic potential, but embolization could have occurred from larger vegetations before hospitalization. Persistent fever accompanied by abdominal, pleuritic, or shoulder pain should raise suspicions of a splenic abscess [14,15]. Although detectable by abdominal ultrasound, CT, or magnetic resonance, scans are preferable imaging modalities with sensitivities and specificities of 90%-95% for splenic abscesses [14]. As presently illustrated, large or multiple abscesses that respond poorly to antibiotics and pose a threat of splenic rupture are indications for splenectomy [1,14,15], which should be performed before valvular surgery, unless the latter is urgent [1,14].

*P. aeruginosa* endocarditis is rarely cured by antibiotics alone (12%-15% of cases), and an early valve-replacement surgery with a prolonged postoperative antibiotic course is recommended [2,4]. Immediate valvular surgery is indicated for refractory/relapsing bacteremia despite adequate antibiotics, intractable heart failure, or development of an intracardiac abscess [4]. Otherwise, timely surgery reduces the risk of death (~50%) associated with surgical neglect [14,16]. In the present case, early valvular surgery might have prevented the development of the splenic abscess. The patient was referred to cardiac surgery following splenectomy since persistence of vegetations and significant valvular dysfunction required surgical treatment. As ventricular function was compensated and blood cultures sterilized following abdominal surgery, valve replacement was safely delayed to complete a six-



week meropenem therapy and to allow recovery from previous surgery.

Another important issue in our case is perioperative management of dual antiplatelet therapy. According to recommendations [17], we decided to discontinue clopidogrel five days before both surgical interventions to reduce bleeding risk. This approach turned out to be successful, but discontinuation of one antiplatelet agent soon after stent implantation carries a risk of an acute stent thrombosis, particularly with drug-eluting stents.

## Conclusion

The present case illustrates that *P. aeruginosa* is a formidable opponent and a cause of life-threatening infections in susceptible individuals. Left-sided endocarditis due to *P. aeruginosa* carries a higher risk of complications, such as splenic abscess formation, and requires judicious medical management, timely surgery, and a multidisciplinary approach for successful treatment.

## References

- Habib G, Hoen B, Tornos P, Thuny F, Prendergast B, Vilacosta I, Moreillon P, de Jesus Antunes M, Thilen U, Lekakis J, Lengyel M, Müller L, Naber CK, Nihoyannopoulos P, Moritz A, Zamorano JL (2009) Guidelines on the prevention, diagnoses and treatment of infective endocarditis. *Eur Heart J* 30: 2369-2413.
- Morpeth S, Murdoch D, Cabell CH, Karchmer AW, Pappas P, Levine D, Nacinovich F, Tattevin P, Fernández-Hidalgo N, Dickerman S, Bouza E, del Río A, Lejko-Zupanc T, de Oliveira Ramos A, Iarussi D, Klein J, Chirouze C, Bedimo R, Corey GR, Fowler VG Jr (2007) Non-HACEK gram-negative bacillus endocarditis. *Ann Intern Med* 147: 829-835.
- Reyes MP, Palutke WA, Wylin RF (1973) *Pseudomonas* endocarditis in the Detroit Medical center 1969-1972. *Medicine (Baltimore)* 52: 173-194.
- Komshian SV, Tablan OC, Palutke W, Reyes MP (1990) Characteristics of left-sided endocarditis due to *Pseudomonas aeruginosa* in the Detroit Medical Center. *Rev Infect Dis* 12: 693-702.
- Wieland M, Lederman MM, Kline-King C, Keys TF, Lerner PI, Bass SN, Chmielewski R, Banks VD, Ellner JJ (1989) Left-sided endocarditis due to *Pseudomonas aeruginosa*: a report of 10 cases and review of the literature. *Medicine (Baltimore)* 65: 180-189.
- Fichtenbaum CJ, Smith MJ (1992) Treatment of endocarditis due to *Pseudomonas aeruginosa* with imipenem. *Clin Infect Dis* 14: 353-354.
- Dawson NL, Brumble LM, Pritt BS, Yao JD, Echols JD, Alvarez S (2011) Left-sided *Pseudomonas aeruginosa* endocarditis in patients without injection drug use. *Medicine (Baltimore)* 90: 250-255.
- Hassan KS, Al-Riyami D (2012) Infective Endocarditis of the Aortic Valve caused by *Pseudomonas aeruginosa* and Treated Medically in a Patient on Haemodialysis. *Sultan Qaboos Univ Med J* 12: 120-123.
- Osmon S, Ward S, Fraser VJ, Kollef MH (2004) Hospital mortality for patients with bacteremia due to *Staphylococcus aureus* and *Pseudomonas aeruginosa*. *Chest* 125: 607-616.
- Gavin PJ, Suseno MT, Cook FV, Peterson LR, Thomson RB Jr (2003) Left-sided endocarditis caused by *Pseudomonas aeruginosa*: successful treatment with meropenem and tobramycin. *Diag Microbiol Infect Dis* 47: 427-430.
- Costerton J (1984) The etiology and persistence of cryptic bacterial infections: a hypothesis. *Rev Infect Dis* 6: S608-616.
- Bayer AS, Crowel DJ, Yih J, Bradley DW, Norman DC (1988) Comparative pharmacokinetics and pharmacodynamics of amikacin and ceftazidime in tricuspid and aortic vegetations in experimental *Pseudomonas* endocarditis. *J Infect Dis* 158: 355-359.
- Pelletier LL Jr, Petersdorf RG (1977) Infective endocarditis: a review of 125 cases from the University of Washington Hospitals, 1963-72. *Medicine (Baltimore)* 56: 287-313.
- Lester SJ, Wilansky S (2007) Endocarditis and associated complications. *Crit Care Med* 35: S384-391.
- Ferraioli G, Brunetti E, Gulizia R, Mariani G, Marone P, Filice C (2009) Management of splenic abscess: report on 16 cases from a single center. *Int J Infect Dis* 13: 524-530.
- Sexton DJ, Spelman D (2003) Current best practices and guidelines. Assessment and management of complications in infective endocarditis. *Cardiol Clin* 21: 273-282.
- Fitchett D, Eikelboom J, Fremes S, Mazer D, Singh S, Bittira B, Brister S, Graham J, Gupta M, Karkouti K, Lee A, Love M, McArthur R, Peterson M, Verma S, Yau (2009) Dual antiplatelet therapy in patients requiring urgent coronary artery bypass grafting surgery: A position statement of the Canadian Cardiovascular Society. *Can J Cardiol* 25: 683-689.

## Corresponding author

Ivana Milošević  
 Medical Faculty, University of Belgrade, Serbia  
 Clinic for Infectious and Tropical Diseases, Clinical Center of Serbia, Bulevar oslobođenja 16, 11 000 Belgrade, Serbia  
 Phone: +381 11 2683366  
 Email: ivana.milosevic00@gmail.com

**Conflict of interests:** No conflict of interests is declared.