

Case Report

Group G Streptococci in association with brain abscess: a rare occurrence

Parimala Subramani¹, Vidhya Raja¹, Bipinchandra Bhagath Lingaiah¹, Beena Prasavangada Madappa¹, Hariprakash Chakravarthy²

¹ Department of Microbiology, Sri Devaraj Urs Academy of Higher Education and Research, Tamaka, Kolar, India

² Department of Neurosurgery, Sri Devaraj Urs Academy of Higher Education and Research, Tamaka, Kolar, India

Abstract

Brain abscess is a serious life-threatening infection of the brain parenchyma. We are reporting a rare case of brain abscess caused by Group G Streptococcus in a 12 year-old female child who presented with neurological symptoms. She was diagnosed with congenital anomalies of the heart at birth. She was treated with amoxycylav and ciprofloxacin. The child recovered and was discharged uneventfully.

Key words: Brain abscess; Group G streptococcus; congenital heart disease.

J Infect Dev Ctries 2014; 8(11):1488-1490. doi:10.3855/jidc.4423

(Received 18 November 2013 – Accepted 25 April 2014)

Copyright © 2014 Subramani *et al.* This is an open-access article distributed under the Creative Commons Attribution License, which permits unrestricted use, distribution, and reproduction in any medium, provided the original work is properly cited.

Introduction

Brain abscess remains a potentially fatal disease of the central nervous system posing a diagnostic challenge especially in developing countries. It is a focal, intracerebral infection that begins as a localized area of cerebritis and develops into a collection of pus, surrounded by a well vascularised capsule [1]. The most common source could be direct infection from the paranasal sinuses, middle ear or dental infections. Haematogenous spread of infection from a distant extracranial foci is another possible source of infection. The important predisposing factors being otitis media, previous history of craniotomy, and congenital heart disease [2].

Case Report

A 12 year-old female patient presented to the hospital with a history of left-sided weakness and visual disturbances for 5 days, which was followed by generalized weakness. The child's past history revealed that she was diagnosed with congenital anomalies of the heart which included dextrocardia, mitral atresia, ventricular septal defect and patent ductus arteriosus.

On physical examination it was found that the child had a left-sided hemiparesis with no sensory loss. The respiratory system was normal. Laboratory investigations revealed that haemoglobin was 17.7 g/dl, WBC- 8000 cells/mm, ESR 20 mm/hour. A

computer tomography (CT) scan of the brain revealed a lesion in the right thalamus extending to the mid brain. A provisional diagnosis of mid-brain abscess was made. A CT guided aspiration of the abscess was done by the neurosurgeon and the pus sample was sent to microbiology for culture and sensitivity. A magnetic resonance imaging (MRI) scan was also done, which showed that the abscess was localised to the basal ganglion (Figure 1).

On macroscopic examination the aspirate was slightly turbid. The Gram stain showed numerous pus cells with numerous Gram-positive cocci in chains. It was cultured on blood agar, chocolate agar and thioglycollate broth. A pure growth of large beta-hemolytic colonies on blood agar was observed after 48 hours of incubation at 37° C. The smear from the culture showed Gram-positive cocci in chains which was catalase negative, bacitracin sensitive and Christie-Atkins-Munch-Petersen (CAMP) test negative [3]. Grouping of the isolate was done using Strep test Kit (Remel Europe Ltd, Dartford, UK).

Based on the above characteristics, it was identified as Group-G streptococcus (*Streptococcus dysgalactiae* subspecies *Equisimilis*). Anaerobic culture of the sample yielded no growth. The isolate was sensitive to penicillin, ciprofloxacin, cotrimoxazole, erythromycin and gentamycin, amoxycylav.

The child was empirically treated with ceftriaxone and metranidazole initially for three days with no improvement. It was changed to amoxyclav and ciprofloxacin based on the culture and sensitivity report for 3 weeks. She responded well which was evidenced by a reduction in the size of the abscess in the MRI scan following treatment (Figure 2). The child did not have any further neurological deficits and she was discharged uneventfully.

Discussion

We are reporting a rare case of basal gangliar abscess caused by Group-G Streptococcus (*Streptococcus dysgalactiae* subspecies *equisimilis*). Basal gangliar abscesses are rare compared to other locations of the brain [4]. This case report becomes rare, as this is the first case where the etiology for basal gangliar abscess is Group G streptococcus. There are few case reports in which *Streptococcus milleri*, pseudomonas [4], Peptostreptococcus, streptococcus Group F have been isolated from basal gangliar and thalamic abscess [5]. The most common site of brain abscess is the temporal lobe abscess with CSOM as the predisposing factor [6]. The most popular organisms associated with brain abscess are *Streptococcus viridans*, *Streptococcus milleri*, *Staphylococcus aureus*, *Mycobacterium tuberculosis*

and some of the gram-negative bacilli like *Pseudomonas*, *Proteus*, and *Candida* [2].

Group G streptococcus as an etiology in brain abscess is rare. It is a commensal of the throat and vagina in healthy humans [6]. It is known to cause pharyngitis, impetigo, glomerulonephritis, wound infection and cellulitis [6]. It is not a common cause of bacteremia and invasive disease. It has been increasingly implicated to cause opportunistic infections in individuals with underlying medical conditions and has gained importance in recent years [7].

In this case, the child had congenital heart disease (CHD) which is one of the most important predisposing factors. CHD, especially arteriovenous malformations, serves as a focal point for bacteria to settle and become a source of bacteremia [7]. Congenital malformations like patent ductus arteriosus, ventricular septal defect and tetralogy of Fallots allows blood-borne bacteria to bypass the pulmonary capillary bed and reach the brain [8]. The decreased arterial oxygenation and polycythemia in CHD may cause focal areas of ischemia in the brain providing a nidus for bacteria to multiply and form an abscess which could be the probable cause in this case [9].

Figure 1. MRI scan shows a ring enhancing lesion in the thalamic area of the right side of the brain

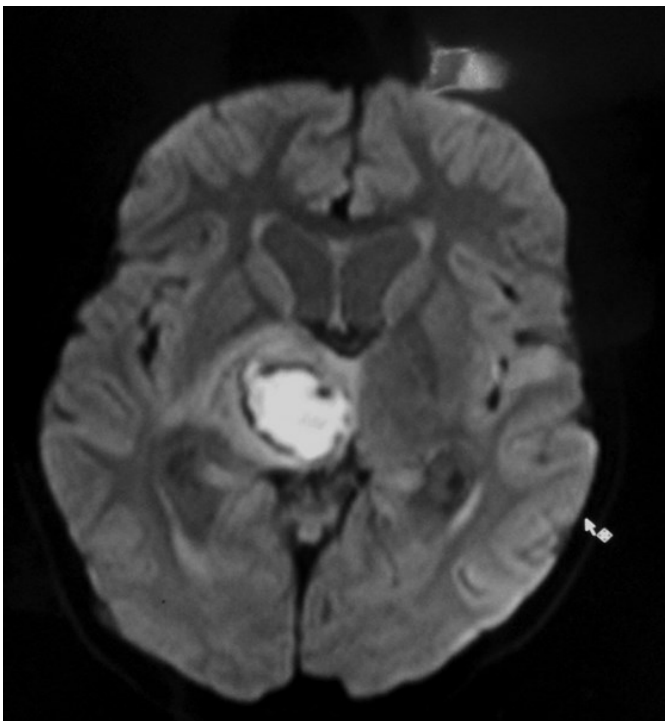
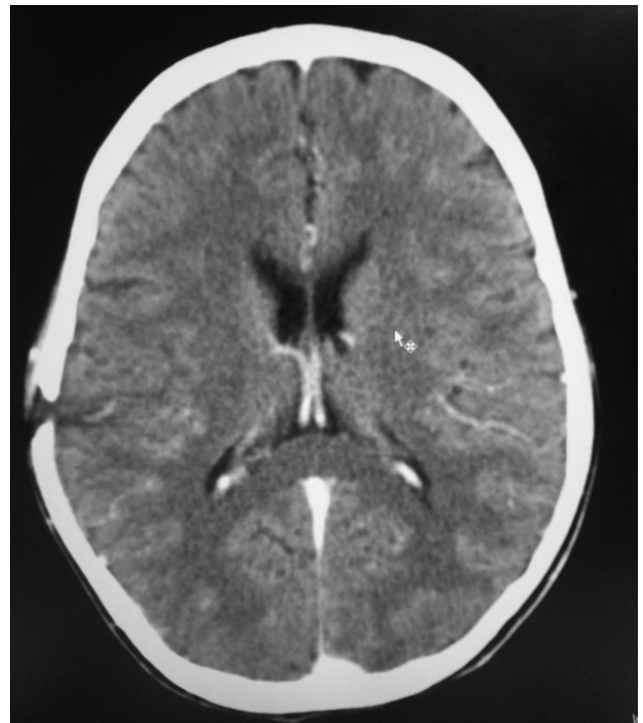


Figure 2. MRI scan shows the reduction of size of the abscess following treatment for three weeks.



Conclusion

Brain abscess has a high mortality and sequelae. It has been cured by antibiotics alone without surgical drainage [10]. For appropriate management of brain abscess, it is important to identify the organism. Microscopy becomes an important tool for diagnosis in emergency. Simple techniques like gram stain and Ziehl-Neelsen stain would help in the proper selection of antibiotics, as it is difficult to distinguish a tubercular abscess clinically and radiologically from a pyogenic abscess [1].

References

- Menon S, Bharadwaj R, Chowdhary A, Kaundinya DV, Palande DA (2008) Current epidemiology of intracranial abscesses: a prospective 5 year study. *J Med Microbiol* 57: 1259-1268.
- Intraparanchymal temporal lobe abscess caused by group F streptococci (2010) *Indian J Pathol Microbiol* 53: 900-901.
- Winn Jr. W, Allen S, Janda W, Koneman E, Procop G, Schreckenbeger P, Woods G (2006) Chapter 13. Gram positive cocci: Part II: Streptococci, Enterococci, and the “Streptococcus-like” bacteria. In: Koneman’s Color Atlas and Textbook of Diagnostic Microbiology, 6th ed. Lippincott Williams and Wilkins, pp.688-689.
- Singh P, Singh AP (2013) Thalamic and gangliar abscesses: A report of two cases: Letter to the editor. *Neurology India* 50: 225-226.
- Lutz TW, Landolt H, Wasner M, Gratzl O (1994) Diagnosis and management of abscesses in the Basal ganglia and Thalamus a survey. *Acta Neurochirurgica* 127: 91-98,
- Kaliyamurthy J, Cuteri V, Jesudasan N, Salman A, Thomas PA, Preziuso S (2011) Post-operative ocular infection due to *Streptococcus dysgalactiae* sub species *equisimilis*. *J Infect Dev Ctries* 5: 742-744. doi:10.3855/jidc.1758
- Rausch J, Foca M (2011) Necrotizing fasciitis in a pediatric patient caused by lancefield group g streptococcus: case report and brief review of the literature. *Case Rep Med* 2011: 671365.
- Lakshmi V, Umabala P, Anuradha K, Padmaja K, Padmasree C, Rajesh A, Purohit AK (2011) Microbiological spectrum of brain abscess at a tertiary care hospital in South India: 24-year data and review. *Patholog Res Int* 2011: 583139.
- Roos KL, Tylae KL (2011) Meningitis, Encephalitis, Brain abscess and Empyema. In: Fauci AS, Kasper DL, Longo DL, Braunwald E, Hauser SL, Jameson JL, Loscalzo J, eds. *Harrisons Principles of Internal Medicine*. 18th ed. NewYork: McGraw-Hill, pp. 3429-3430.
- Synder RD (2007) Chapter 38. Bacterial infections of the nervous system. In: Swaiman eds. *Pediatric Neurology*. 2nd ed. USA: Mosby, pp.628-629.

Corresponding author

Parimala Subramani
 Assistant professor
 Department of Microbiology, Sri Devaraj Urs Academy of Higher Education and Research, Tamaka, Kolar, 563101, Karnataka, India
 Phone: + 91 8152-649210
 Mobile:+ 91 9740189773
 Fax: + 91 152-243006
 Email: mjchand@gmail.com

Conflict of interests: No conflict of interests is declared.