

## Case Report

# Association of tuberculosis and tricuspid valve endocarditis in AIDS patient with Ebstein heart anomaly

Aleksandra Radovanović Spurnić<sup>1</sup>, Bosiljka Vujisić Tešić<sup>2</sup>, Marija Boričić-Kostić<sup>2</sup>, Djordje Jevtović<sup>1</sup>

<sup>1</sup> Clinic for Infectious and Tropical Diseases, Clinical Centre of Serbia, Faculty of Medicine, University of Belgrade, Belgrade, Serbia

<sup>2</sup> Cardiology Clinic, Clinical Center of Serbia, Faculty of Medicine, University of Belgrade, Belgrade, Serbia

### Abstract

A case of tricuspid valve endocarditis in an AIDS patient, an intravenous drug user, initially empirically unsuccessfully treated as a *Staphylococcus aureus* infection, and thereafter turned to be, most likely, of *Mycobacterium tuberculosis* etiology is presented.

**Key words:** AIDS; disseminated tuberculosis; endocarditis; Ebstein heart anomaly.

*J Infect Dev Ctries* 2017; 11(12):967-970. doi:10.3855/jidc.7462

(Received 25 July 2015 – Accepted 26 March 2016)

Copyright © 2017 Radovanović Spurnić *et al.* This is an open-access article distributed under the Creative Commons Attribution License, which permits unrestricted use, distribution, and reproduction in any medium, provided the original work is properly cited.

### Introduction

Tuberculosis (TB) remains one of the world's deadliest communicable diseases [1]. The probability of developing TB is much higher among HIV-positive patients [1].

Tuberculous endocarditis (TBE) is extremely rare and establishing the diagnosis of this disease is rather difficult. Most reports of TBE result from autopsy series [2,3]. As such, in clinical practice the diagnosis is often made by ruling out others.

Only one case of *Mycobacterium tuberculosis* tricuspid valve endocarditis in an AIDS patient has been reported so far [4].

We presented a case report of an AIDS patient with Ebstein heart anomaly, with pulmonary and, very likely, extrapulmonary, disseminated TB, during the antiretroviral therapy (ART). The patient also developed tricuspid valve endocarditis.

### Case Presentation

A 37-year old male, an intravenous drug addict, presented in 1999 as a mild symptomatic HIV infection (CDC group B), however with a very low CD4 cell count (50 cells/ $\mu$ L). He also had a hepatitis C virus (HCV) co-infection. His history revealed heart murmur since childhood. The ART was a dual one, comprising zidovudine and lamivudine. In 2000 it was switched to a combination ART (didanosine, stavudine, and nelfinavir). From 2000 to 2004, during his out-patient

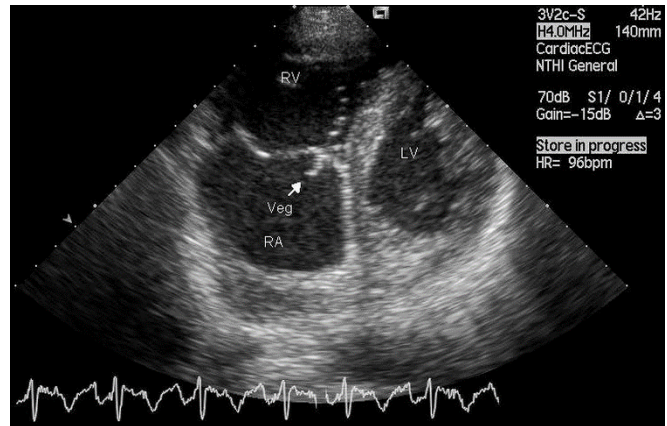
management at the Infectious and Tropical Diseases University Hospital of the Clinical Centre of Serbia, his highly active antiretroviral therapy (HAART) combinations were often changed due to drug shortages. Mainly, those were two nucleoside reverse transcriptase inhibitors (NRTI) and a protease inhibitor (nelfinavir, sakvinavir, indinavir). During 2004 he also took a triple NRTI combination, with good response. Between 2004 and 2007 he maintained undetectable HIV RNA, with the CD4 cell count varying between 235–467 cells/ $\mu$ L. In October 2007 the patient was hospitalized with fever, malaise, and anorexia. Chest X-ray revealed right sided lung infiltrate and pleural effusion, while the differential diagnostic suggested *Staphylococcus aureus* infection and/or TB. This complication appeared during successful HAART, possibly as a clinical manifestation of immune restoration inflammatory syndrome. Along with pleuropneumonia, he had a systolic murmur of 4/6 and his cardio-circulatory function was compensated. Abdominal and heart ultrasonography revealed retroperitoneal lymphadenopathy and Ebstein anomaly, respectively (Figure 1). There was no vegetation. Minor pericardial effusion (up to 5 mm round the whole heart) was observed. Laboratory tests showed mild leukocytosis with polynucleosis. Biomarkers of inflammation were slightly elevated C reactive protein (CRP) 20 mg/L, fibrinogen 4.9 g/L, procalcitonin 0.048 ng/mL, along with a slightly increased activity of serum

transaminase (AST 50, ALT 76 U/L) and preserved liver synthetic function. Microbiological procedures started with the negative blood culture. An empirical antibiotic therapy with vancomycin was introduced i. v. due to suspected *S. aureus* etiology of the disease, commonly seen among injecting drug users. He received vancomycin during the first 5 days of therapy, 1.0 g i. v. twice a day. The second blood culture was obtained during the vancomycin therapy and it was negative again.

His sputum smear was positive for acid-fast bacilli in two independent samples. As there was no treatment response to vancomycin therapy, five days later a triple anti-TB therapy was introduced including isoniazid (INH) 300 mg qd, rifampin (RMP) 600 mg qd, and pyrazinamide (PZA) 800 mg bid. With the introduction of anti-TB therapy, the fever resolved, but after six weeks his temperature rose again. The third blood culture was negative again. After 7 weeks ethambutol (EMB) 800 mg bid was added to the anti-TB regimen.

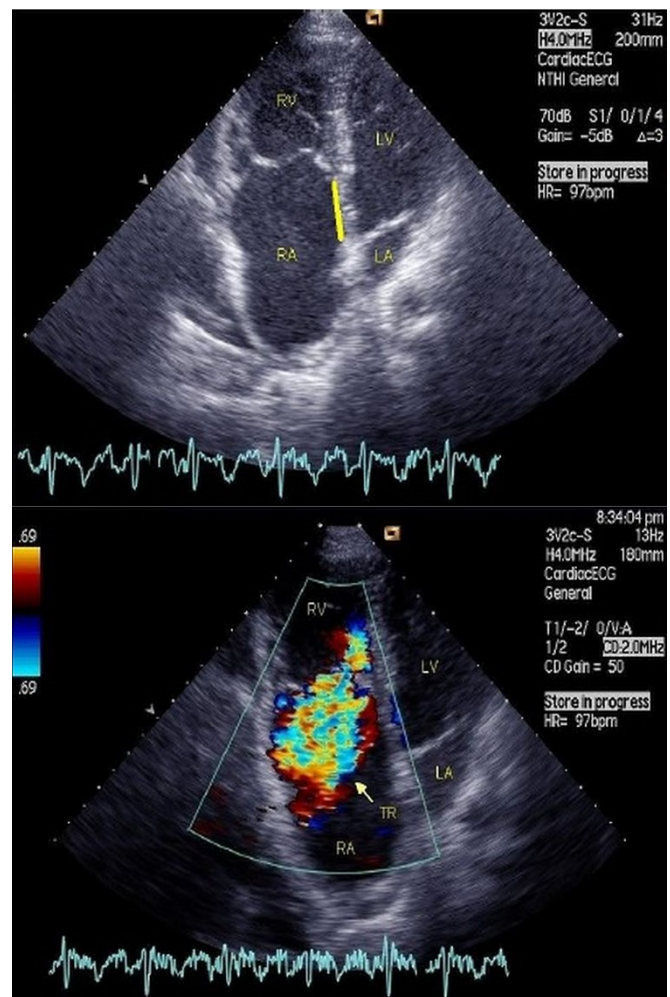
His fever resolved after 8 days of the quadruple anti-TB therapy. Laboratory tests showed mild leukocytosis and slightly increased CRP (36 mg/L), while the erythrocyte sedimentation rate (ESR) and fibrinogen were normal, as well as other clinical biochemistry results. At this stage of treatment, the follow-up echocardiography showed stripe-shaped soft vegetation on the tricuspid valve, 0.8 – 1 cm long (Figure 2). Mycobacterial blood culture was not performed. After the echocardiographic finding confirmed endocarditis, vancomycin 1 g i.v. was reintroduced twice a day and continued for the following 6 weeks [5]. A series of chest X-rays showed gradual regression of pleuropneumonia after quadruple anti-TB therapy and re-administration of vancomycin. His fever resolved and he was discharged from hospital in January 2008, asymptomatic, with normal biomarkers of inflammation. A series of acid-fast bacilli sputum tests were negative in mid-December 2007. At the time of discharge from the hospital a follow-up echocardiography showed unchanged tricuspid valve pathology with a good hemodynamic status. However, the vegetation gradually shrunk until March 2009. The patient was discharged in a good condition and continued therapy at home. His treatment comprised anti-TB drugs (INH+ vit.B6, RMP, PZA and EMB for 2 months, while INH + RMP were administered for 9 months in total). He concomitantly took HAART: abacavir 600 mg, lamivudine 300 mg and efavirenz 900 mg every day. On his regular radiographic and HIV follow-ups the patient remained stable, and accordingly there was no need for cardio-surgical treatment.

**Figure 1.** Echocardiography: Ebstein anomaly with displacement of the tricuspid valve toward the apex of the right ventricle and atrialized right ventricle.



TR: tricuspid regurgitation; RA: right atrium; RV: right ventricle; LV: left ventricle.

**Figure 2.** Echocardiography: The figure of vegetation in right ventricle.



RV: right ventricle; RA: right atrium; LV: left ventricle; Vegetation is indicated by the yellow arrow.

## Discussion

TBE was first reported from autopsy by Laennec in 1826 [6]. TBE is most commonly associated with disseminated TB [7-13]. Only few cases of valvular endocarditis without disseminated TB were reported: several in immunocompetent patients [14-16] but only one in an AIDS patient [4].

There are no published data on valvular pathology among patients with pulmonary TB [16].

Cope *et al.* described a patient with aortic valve endocarditis and disseminated TB. The diagnosis of disseminated TB was made after percutaneous liver biopsy. During the triple therapy (INH, RMP and EMB) in appropriate doses, the patient had paradoxical reaction (PR) [18] and aortic diastolic murmur developed. All the blood cultures were negative. Echocardiography revealed vegetation, while chest-X ray suggested miliary TB. After the quadruple anti-TB therapy (INH, RMP, PZA and EMB) was introduced the disease took a turn for the better [8].

Klinger *et al.* presented an immunocompetent patient with TBE and secondary *S. epidermidis* mitral valve infection [14].

Regarding our patient, the first blood culture was obtained before antibiotic therapy was introduced and it turned to be negative, as well as four consecutive ones, taken whenever he had fever during the therapy. The urine cultures were also negative. The only microbiological confirmation of an opportunistic infection was the isolation of *M. tuberculosis* from the sputum. The initial unsuccessful vancomycin treatment contradicted the *S. aureus* etiology of the disease. During the triple anti-TB therapy, our patient had PR [18] and tricuspid valve endocarditis was diagnosed.

Since no pathogenic bacteria were isolated in the blood culture (mycobacterial blood culture was not performed), and the tricuspid vegetation resolved only at the end of nine months of anti-TB therapy, endocarditis in the context of disseminated TB was most probable [8,18].

The patient was successfully treated with anti-TB drugs along with vancomycin [5], an antibiotic with a narrow antibacterial spectrum, which also suggested that a causative agent other than *S. aureus* was the most likely one, associated with endocarditis, precisely *M. tuberculosis*.

In addition to the lung and pleural involvement, the patient had enlarged retroperitoneal lymph nodes, as a possible sign of disseminated TB, which, in turn, is rather difficult to definitely diagnose without a biopsy and/or a positive blood culture. Although histopathological findings are essential for the

definitive diagnosis the biopsy was not performed due to a difficult access to retroperitoneal lymph nodes, and the patient experienced improvement (after EMB 800 mg bid was added to the anti -TB regimen).

Nevertheless, positive echocardiographic findings of valvular vegetation and positive TB cultures in a patient presenting with clinical signs of endocarditis do suggest TBE [14-17].

Finally, like in our patient, several reports have described successful treatment of TBE only with quadruple anti-TB therapy in appropriate doses [4,14,16,17].

## Conclusions

It is rather difficult to establish the clinical diagnosis of TBE, since it requires both microbiological and valvular pathology confirmation, which are difficult to be obtained simultaneously [16]. TB should be considered in cases of culture negative endocarditis in endemic areas, even in immunocompetent hosts [19,20]. Although diagnostic difficulties were encountered in our patient regarding the definitive diagnosis of disseminated TB, it seems that this was one of the rare cases of endocarditis in the context of disseminated TB and HIV infection [4].

Nevertheless, in HIV-infected patients with endocarditis, *M. tuberculosis* should be included into the differential diagnosis, especially if the initial antibiotic therapy was unsuccessful.

## Authors contribution

A.R.S. - Concept and design; Wrote the article; B.V.T. - Analysis and interpretation; M.B.K. - Data Collection; D.J.- Critical revision of the article; Final approval of the article

## References

1. Zumla A, George A, Sharma V, Herbert RH, of Ilton BM, Oxley A, Oliver M (2015) The WHO 2014 global tuberculosis report—further to go. *Lancet Glob Health* 31 3:e10-12.
2. Suzman S (1943) Tuberculous pericardial effusion. *Br Heart J* 5: 19–23
3. Rumisek JD, Albus RA, Clarke JS (1985) Late *Mycobacterium chelonae* bioprosthetic valve endocarditis: activation of implanted contaminant? *Ann of Thorac Surg* 39:277–279.
4. Fumagalli J, Bonifacio C, Gulotta H, Shinzato R, Troncoso A (2002) Bacterial endocarditis: a role for *Mycobacterium tuberculosis*? *AIDS* 16: 1845–1846.
5. Gillbert DN, Moellering RC, Eliopoulos GM, Saude MA (2008) *The Sanford Guide of Antimicrobial Therapy* 2008, 38th edition. Sperryville USA: Sanford Guide 25p.
6. Laennec RTH (1826) *Traits of Auscultation. JS Clause* 28: 196.

7. Kannangara DW, Salem FA, Rao BS, Thadepalli H (1984) Cardiac tuberculosis: TB of the endocardium. *Am J Med Sci* 287: 45–47.
8. Cope AP, Heber M, Wilkins EG (1990) Valvular tuberculous endocarditis: a case report and review of the literature. *J Infection* 21: 293–296.
9. Laskowski LF, Marr JJ, Spornoga JF, Frank NJ, Barner, HB, Kaiser G, Tyras DH (1977) Fastidious mycobacteria grown from porcine prosthetic-heart-valve cultures. *N Engl J Med* 297: 101-102.
10. Kuritsky JN, Bullen MG, Broome CV, Silcox VA, Good, Wallace RJ (1983) Sternal wound infections and endocarditis due to organisms of the *Mycobacterium fortuitum* complex. *Ann Intern Med* 98: 938–939.
11. Wainwright J (1979) Tuberculous endocarditis: A report of 2 cases. *S Afr Med J* 56: 731–733.
12. Anyanwu CH, Nassau E, Yacoub M (1976) Miliary tuberculosis following homograft valve replacement. *Thorax* 31: 101–106.
13. Yamane H, Fujiwara T, Doko S, Inada H, Nogami A, Masaki H, Yoshida H (1989) Two cases of miliary tuberculosis following prosthetic valve replacement. *Kokyu to Junkan* 37: 803–805.
14. Klingler K, Brändli O, Doerfler M, Schluger N, Rom WN (1998) Valvular endocarditis due to *Mycobacterium tuberculosis*. *Int J Tuberc Lung Dis* 2: 435–437.
15. Sogabe O, Ohya T (2007) A case of tuberculous endocarditis with acute aortic valve insufficiency and annular subvalvular left ventricular aneurysm. *Gen Thorac Cardiovasc Surg* 55: 61–64.
16. Sultan FA, Fatimi S, Jamil B, Moustafa SE, Mookadam F (2010) Tuberculous endocarditis: valvular and right atrial involvement. *Eur J Echocardiogr* 11: 4.
17. Liu A, Nicol E, Hu Y, Coates A (2013) Tuberculosis endocarditis. *Int J Cardiol* 167: 640-645.
18. Breen RAM, Smith CJ, Bettinson H, Dart S, Bannister B, Johnson MA, Lipman MCI (2004) Paradoxical reactions during tuberculosis treatment in patients with and without HIV co-infection. *Thorax* 59: 704–707.
19. Shaikh and Mahmood (2012) Triple valve endocarditis by mycobacterium tuberculosis. A case report. *BMC Infect Dis* 12: 231
20. Yuan, Shi-Min (2015) Mycobacterial endocarditis: a comprehensive review. *Braz J Cardiovasc Surg* 30: 93-103.

### Corresponding author

Aleksandra Radovanović Spurnić  
Hospital for infectious and tropical disease, Clinical Center of Serbia, Faculty of medicine, University of Belgrade  
Bulevar Oslobođenja 16  
11000 Belgrade, Serbia  
Phone: +381 63 77 68 747  
Fax: +381112684071  
E-mail: spurnic@yahoo.com

**Conflict of interests:** No conflict of interests is declared.