

Case Report

A large pulmonary cavity replaced by a tuberculosis granuloma and healed during treatment of a patient with tuberculosis

Ling Chen¹, Jianyong Zhang¹, Hong Zhang^{1,2}

¹ Department of Respiratory Medicine, Affiliated Hospital of Zunyi Medical College, Zunyi, Guizhou, China

² Z-BioMed, Inc., Rockville, Maryland, United States

Abstract

In the early stages of *M. tuberculosis* infection, lung tuberculosis (TB) granulomas are often formed at sites of infection to constrain the infection and can undergo healing in most cases or enlarge as the disease progresses in some cases. We present here an unusual case of TB in which a large previously existing pulmonary cavity was replaced by a TB granuloma and then healed during treatment of a patient with poly-resistant TB. This case indicates that the disease process from TB granuloma formation to pulmonary cavities and progression or healing is more diverse than previously thought and could be reversed. An in-depth understanding of the disease process from initiation and maintenance of the TB granuloma to pulmonary cavities and progression or healing will provide new ways to combat mycobacterial infections.

Key words: disease process; tuberculosis granuloma; pulmonary cavity, poly-resistant tuberculosis.

J Infect Dev Ctries 2018; 12(1):060-062. doi:10.3855/jidc.9719

(Received 28 August 2017 – Accepted 28 November 2017)

Copyright © 2018 Chen *et al.* This is an open-access article distributed under the Creative Commons Attribution License, which permits unrestricted use, distribution, and reproduction in any medium, provided the original work is properly cited.

Introduction

Tuberculosis (TB) is one of the top ten causes of death and a leading cause of death from infectious diseases in the world. Over 95% of 1.8 million TB deaths occurred in low- and middle-income developing countries in 2015 [1]. Latent TB infection affects about one-third of the world's population but only 5-10% of infected people will develop active TB disease over their lifetime, indicating the importance of balanced human immune responses in control of *Mycobacterium tuberculosis* (*Mtb*) infection [2,3]. In the early stages of *Mtb* infection, lung TB granulomas are often formed at sites of infection to constrain the infection and disruption of the TB granuloma structure will lead to the formation of pulmonary cavities and the progression to active TB disease [4-7]. It is generally accepted that the disease process from tuberculosis formation to pulmonary cavities and progression or healing usually follows these steps for the vast majority of *Mtb* cases. However, there is always an exception to every disease process. We report here an unusual case of TB in which a large previously existing pulmonary cavity with a thin wall was replaced by a TB granuloma and healed during treatment of a patient with poly-resistant TB.

Case Report

A 34-year-old Chinese woman with a one-year history of pulmonary TB presented to our hospital with symptoms of cough, blood-streaked sputum, weight loss and fatigue. Her sputum samples revealed the presence of acid-fast bacilli graded as 4+, and pulmonary cavities in the right upper lobe were evident on her previous chest radiography taken three

months earlier. Liver function tests were normal and there was no history of alcohol abuse or viral hepatitis. Test results for human immunodeficiency virus (HIV) and fungal infections (*Aspergillus* and *Candida albicans*) were negative.

She continued her treatment with four first-line anti-tuberculosis drugs (isoniazid, rifampicin, ethambutol, and pyrazinamide) while waiting for the sputum test results. Sputum culture was confirmed to contain a poly-resistant strain of *Mtb* resistant to isoniazid, ethambutol and streptomycin. Computed tomography (CT) scan of the chest confirmed the presence of bilateral multiple infiltrative lesions with a few cavities in the right upper lobe. The largest cavity measured 3.1 cm in diameter with a thin wall (Figure 1A, arrow).

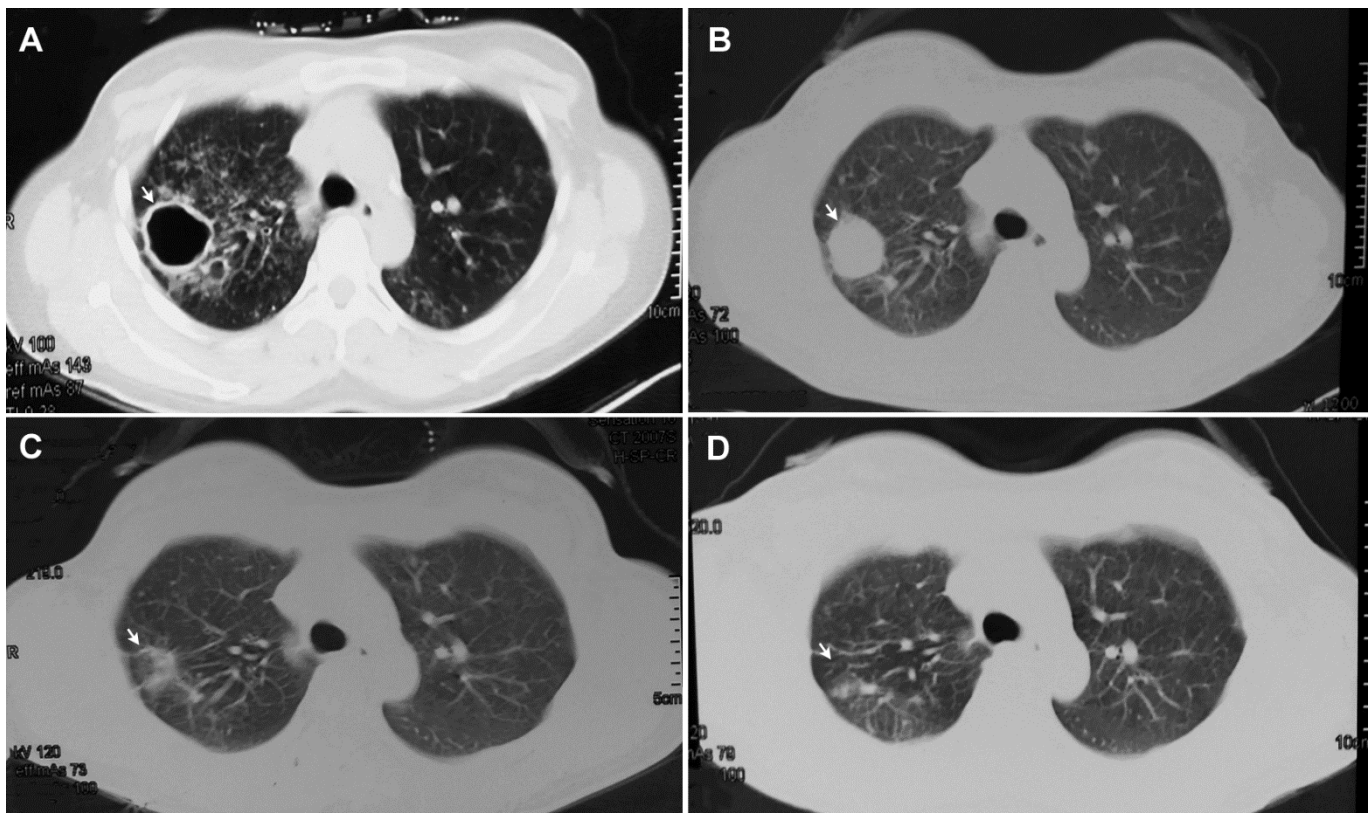
A treatment regimen including first-line (rifampicin and pyrazinamide) and second-line anti-tuberculosis drugs (levofloxacin, amikacin, cycloserine and prothionamide) was initiated. A follow-up chest CT scan performed after five months of anti-tuberculosis therapy revealed that the 3.1 cm pulmonary cavity was filled up by a TB granuloma with a size of 2.8×2.7 cm (Figure 1B, arrow). After 12 months of treatment, her chest CT scan showed that the large TB granuloma decreased in size remarkably (Figure 1C, arrow). Six months after the completion of a 15-month treatment (started in January 2015 and ended in April 2016), CT scan of the chest showed that the TB granuloma was absorbed and turned into fibrosis (Figure 1D, arrow). The patient gained 5 kg of weight and her symptoms abated after the treatment.

Discussion

The human TB granuloma, a hallmark of tuberculosis, is an organized structure that plays a key role in the host immune responses to *Mtb* and pathogen persistence. A TB granuloma has a core of infected macrophages surrounded by foamy macrophages, monocytes and multinucleated giant cells [8]. The development of a caseous TB granuloma has been involved in the progression from latent TB to active disease and transmission, and caseation of human TB granulomas has been correlated with elevated host lipid metabolism in cells surrounding the caseum [9]. The network of factors that regulates the granulomatous inflammation and the host-pathogen interactions within the TB granuloma is complex and it is still unclear how a balanced response determines a protective rather than a destructive process [10,11]. Microarray profiling of caseous TB granulomas showed that many of the genes encoding enzymes involved in the lipid metabolism were differentially upregulated, and some of their encoded proteins were disproportionately abundant in cells surrounding the caseum. Biochemical analysis of the major lipid species within the caseum revealed an abundance of cholesterol esters (CE), cholesterol (CHO), and triacylglycerols (TAG) and also a high level of lactosylceramide (LacCer) [9].

It has been proposed that some *Mtb* cell wall components could stimulate the host's innate immune response to enhance synthesis and/or sequestration of host lipids in the form of lipid droplets inside macrophages, and accumulated foamy macrophages in the macrophage-rich center of the TB granuloma would ultimately die through either apoptosis or necrosis, leading to the buildup of lipids as caseum and finally to cavitation and release of infectious *Mtb* bacilli [9]. Based on this model, the disease process after the initial *Mtb* infection is typically started with the formation of a TB granuloma at sites of infection, proceeds to granuloma liquefaction and cavitation caused by accumulation of caseum in the center of the TB granuloma, and ultimately to transmission of *Mtb* bacilli [11]. However, in few unusual cases, a previously existing pulmonary cavity with a thin wall could be replaced by a TB granuloma and then healed completely during treatment of patients with TB, which suggests that the typical disease process is more diverse than previously thought and could be reversed. Among thousands of TB patients treated at our hospital over the last three years, only three such unusual cases of TB have been identified. In this case report, we described one of the three unusual cases of TB due to the lack of complete CT images for the other two cases, even though the disease process and treatment outcomes were very similar.

Figure 1. Chest CT scan images showing a large pulmonary cavity replaced by a tuberculoma and then healed during treatment of a patient with poly-resistant tuberculosis. (A) A large previously existing pulmonary cavity measured 3.1 cm in diameter (arrow). (B) The large cavity filled up by a large tuberculoma with a size of 2.8×2.7 cm five months after anti-tuberculosis therapy (arrow). (C) A large tuberculoma decreased in size after 12 months of treatment (arrow). (D) A large tuberculoma was absorbed completely and turned into fibrosis six months after the completion of a 15-month treatment (arrow).



Conclusions

This case report shows that a large previously existing pulmonary cavity can be replaced by a TB granuloma and healed during the treatment of a patient with poly-resistant TB, indicating that the disease process from TB granuloma formation to pulmonary cavities and progression or healing is more diverse than previously thought and could be reversed. The fact that a large pulmonary cavity in a patient with poly-resistant TB can be cured with appropriate treatment regimens will help physicians and health care providers around the world, especially those who take care of TB patients in 30 high TB burden developing countries [1], to treat TB patients with similar situations. An in-depth understanding of the mechanism from initiation and maintenance of the TB granuloma to pulmonary cavities and progression or healing will provide new ways to combat mycobacterial infections [11,12].

Acknowledgements

This study was supported by the National Natural Science Foundation of China (81360002 to L.C.). The 2nd 2011 Collaborative Innovation Center for TB Prevention and Cure in Guizhou Province (Incubation Project), and the Key Laboratory of Infectious Diseases & Biosafety (Guizhou Provincial Department of Education, Zunyi Medical University). The sponsors played no role in the collection, analysis, and interpretation of data; in writing the manuscript; and in the decision to submit the article for publication.

References

- World Health Organization (2016) Global tuberculosis report 2016. Available: http://www.who.int/tb/publications/global_report/en/. Accessed 25 August, 2017.
- World Health Organization (2015) Guidelines on the management of latent tuberculosis infection. Available: http://www.who.int/tb/publications/ltbi_document_page/en/. Accessed 25 August, 2017.
- Gideon HP, Phuah J, Myers AJ, Bryson BD, Rodgers MA, Coleman MT, Maiello P, Rutledge T, Marino S, Fortune SM, Kirschner DE, Lin PL, Flynn JL (2015) Variability in tuberculosis granuloma T cell responses exists, but a balance of pro- and anti-inflammatory cytokines is associated with sterilization. *PLoS Pathog* 11: e1004603.
- Lin PL, Ford CB, Coleman MT, Myers AJ, Gawande R, Ioerger T, Sacchetti J, Fortune SM, Flynn JL (2014) Sterilization of granulomas is common in active and latent tuberculosis despite within-host variability in bacterial killing. *Nat Med* 20: 75-79.
- Ulrichs T, Kaufmann SH (2006) New insights into the function of granulomas in human tuberculosis. *J Pathol* 208: 261-269.
- Ulrichs T, Kosmiadi GA, Jörg S, Pradl L, Titukhina M, Mishenko V, Gushina N, Kaufmann SH (2005). Differential organization of the local immune response in patients with active cavitary tuberculosis or with nonprogressive tuberculoma. *J Infect Dis* 192: 89-97.
- Jeong YJ, Lee KS (2008) Pulmonary tuberculosis: up-to-date imaging and management. *AJR Am J Roentgenol* 191: 834-844.
- Russell DG, Cardona PJ, Kim MJ, Allain S, Altare F (2009) Foamy macrophages and the progression of the human tuberculosis granuloma. *Nat Immunol* 10: 943-948.
- Kim MJ, Wainwright HC, Locketz M, Bekker LG, Walther GB, Dittrich C, Visser A, Wang W, Hsu FF, Wiehart U, Tsenova L, Kaplan G, Russell DG (2010) Caseation of human tuberculosis granulomas correlates with elevated host lipid metabolism. *EMBO Mol Med* 2: 258-274.
- Silva Miranda M, Breiman A, Allain S, Deknuydt F, Altare F (2012) The tuberculous granuloma: an unsuccessful host defence mechanism providing a safety shelter for the bacteria? *Clin Dev Immunol* 2012: 139127.
- Kiran D, Podell BK, Chambers M, Basaraba RJ (2016) Host-directed therapy targeting the *Mycobacterium tuberculosis* granuloma: a review. *Semin Immunopathol* 38: 167-183.
- Pai M, Behr MA, Dowdy D, Dheda K, Divangahi M, Boehme CC, Ginsberg A, Swaminathan S, Spigelman M, Getahun H, Menzies D, Raviglione M (2016) Tuberculosis. *Nat Rev Dis Primers* 2: 16076.

Corresponding authors

Ling Chen and Hong Zhang
 Department of Respiratory Medicine, Affiliated Hospital of Zunyi Medical College, 149 Dalian Road, Zunyi, Guizhou 563003, China.
 Phone: +86-851-28609237
 Fax: +86-851-28608239
 Email: lingjuncd@163.com (Ling Chen);
 hzhang@zbiomed.com (Hong Zhang)

Conflict of interests: All authors except HZ report no potential conflicts of interest. H.Z. is employed by and has shares in Z-BioMed, Inc., which is involved in infectious disease research.