

## Case Report

### Moxifloxacin-induced neutropenia in 26-year-old man

Tuğba Kula Atik<sup>1</sup>, Emre Ispir<sup>2</sup>, Aykut Aytekin<sup>3</sup>, Ufuk Turhan<sup>4</sup>, Esmâ Yeniiz<sup>5</sup>, Dilaver Tas<sup>6</sup>, Orhan Bedir<sup>7</sup>

<sup>1</sup> Department of Microbiology, Balıkesir Atatürk City Hospital, Balıkesir, Turkey

<sup>2</sup> Department of Biochemistry, Balıkesir Atatürk City Hospital, Balıkesir, Turkey

<sup>3</sup> Department of Radiology, Balıkesir State Hospital, Balıkesir, Turkey

<sup>4</sup> Department of Pulmonology, Balıkesir State Hospital, Balıkesir, Turkey

<sup>5</sup> Department of Infectious Diseases, Balıkesir State Hospital, Balıkesir, Turkey

<sup>6</sup> Department of Pulmonology, Sultan Abdülhamid Han Training and Research Hospital, Istanbul, Turkey

<sup>7</sup> Department of Microbiology, Gülhane Training and Research Hospital, Ankara, Turkey

#### Abstract

Moxifloxacin is a fourth generation widely used fluoroquinolone antibiotic. There are three cases of moxifloxacin-induced neutropenia reported in the literature and we report the fourth case.

A 26-year-old man with pneumonia was treated with moxifloxacin because of penicillin allergy. On the second day of therapy, leukopenia [White blood cell (WBC) count  $2.7 \times 10^3/\mu\text{L}$ ] and neutropenia (neutrophils  $1.21 \times 10^3/\mu\text{L}$ ) occurred. *Rothia mucilaginosa* was isolated in sputum culture. On the fourth day of hospitalization moxifloxacin treatment was stopped and clarithromycin 500 mg PO twice daily was started. Leukopenia and neutropenia resolved one day after discontinuation of moxifloxacin that WBC and neutrophil count rose  $4.5 \times 10^3/\mu\text{L}$  and  $1.97 \times 10^3/\mu\text{L}$ , respectively. On the sixth day of hospitalization, WBC and neutrophil count was  $4.3 \times 10^3/\mu\text{L}$  and  $2.29 \times 10^3/\mu\text{L}$ , respectively.

The immunomodulatory effects of moxifloxacin may result in the changes of WBC count like leukopenia with neutropenia. Moxifloxacin induced neutropenia may be more common and is an important adverse effect. More observational studies about safety profiles of moxifloxacin are needed.

**Key words:** Fluoroquinolone; moxifloxacin; neutropenia; pneumonia; *Rothia mucilaginosa*.

*J Infect Dev Ctries* 2018; 12(10):922-925. doi:10.3855/jidc.10212

(Received 30 January 2018 – Accepted 14 August 2018)

Copyright © 2018 Kula Atik *et al.* This is an open-access article distributed under the Creative Commons Attribution License, which permits unrestricted use, distribution, and reproduction in any medium, provided the original work is properly cited.

#### Introduction

Moxifloxacin, inhibiting ATP-dependent enzymes topoisomerase II (DNA gyrase) and topoisomerase IV, is a fourth generation widely used fluoroquinolone antibiotic [1,2]. Moxifloxacin with potent activity against gram-positive, gram-negative and atypical bacteria is generally being used for the treatment of community-acquired pneumonia (CAP) and widely used in urinary system, digestive system and other infections [1,3,4]. It is also used in neutropenic patients for the treatment of infections [5]. Common adverse effects are nausea, diarrhea and dizziness. QT prolongation, fatal arrhythmias and liver injury are uncommon adverse effects [4,6].

There are three cases of moxifloxacin-induced neutropenia reported in the literature and we report the fourth case of moxifloxacin-induced neutropenia in a 26-year-old man.

#### Case Presentation

A 26-year-old man was referred to our infectious disease polyclinic from emergency department with complaints of fever, general body pain and expectoration of purulent sputum. The patient had been given paracetamol 500 mg four times a day by emergency department. He had been previously diagnosed with iron-deficiency anemia one month ago in a routine examination and had history of being allergic to penicillin.

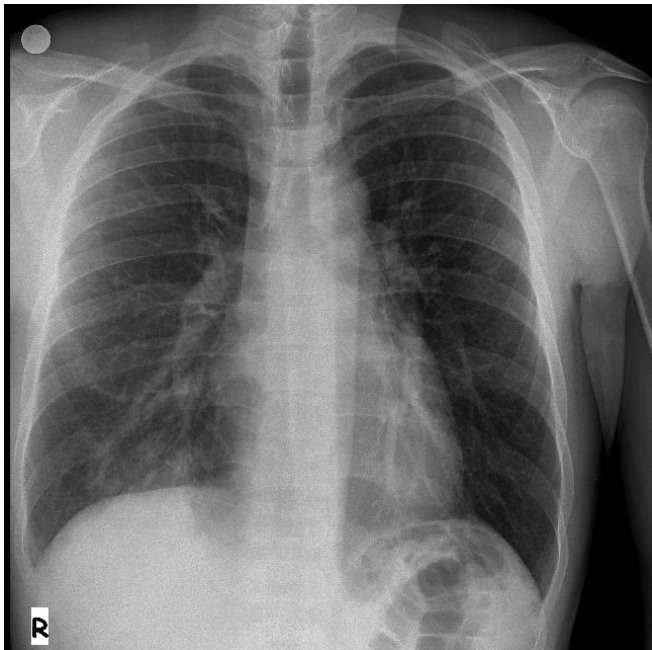
On examination, his temperature was 39.9°C, pulse 100 beats per minute, blood pressure 100/70 mmHg and respirations 20 per minute. Respiratory system examination revealed crackles at the bases of the right lung. The remainder of the examination was normal. Chest X-ray revealed opacities in the right lower zone at paracardiac region (Figure 1).

On admission, laboratory studies revealed a white blood cell count of  $11.7 \times 10^3/\mu\text{L}$ , neutrophils  $9.47 \times 10^3/\mu\text{L}$  (80.9%), C-reactive protein of 83.4 mg/L

(0-5 mg/L), the levels of serum urea, creatinine, AST, ALT were in normal range. Sputum was collected and delivered to the microbiology laboratory for Gram staining and culture. Because of penicillin allergy oral moxifloxacin 400 mg therapy was begun once daily with the diagnosis of community-acquired pneumonia. On the second day of therapy, leukopenia [White blood cell (WBC) count  $2.7 \times 10^3/\mu\text{L}$ ] and neutropenia (neutrophils  $1.21 \times 10^3/\mu\text{L}$ ) occurred. On the fourth day of hospitalization moxifloxacin treatment was stopped and clarithromycin 500 mg PO twice daily was started. Leukopenia and neutropenia resolved one day after discontinuation of moxifloxacin (fifth day of hospitalization) that WBC and neutrophil count rose  $4.5 \times 10^3/\mu\text{L}$  and  $1.97 \times 10^3/\mu\text{L}$ , respectively. On the sixth day of hospitalization, WBC and neutrophil count was  $4.3 \times 10^3/\mu\text{L}$  and  $2.29 \times 10^3/\mu\text{L}$ , respectively (Figure 2).

Gram staining of the sputum revealed a large number of polymorphonuclear leucocytes with abundant gram-positive cocci. *Rothia mucilaginosa* was isolated in sputum culture with Phoenix automated system (BD Diagnostic Systems, USA). For confirmation another sputum culture was obtained. Same gram staining and culture results were determined so *R. mucilaginosa* was considered as the causative agent of the pneumonia.

Figure 1. Patient’s chest x-ray.



Opacities in the right lower zone at paracardiac region. The air in the left upper column is thought to belong to the colon and stomach. This appearance is evaluated physiological. There are no associated findings clinically.

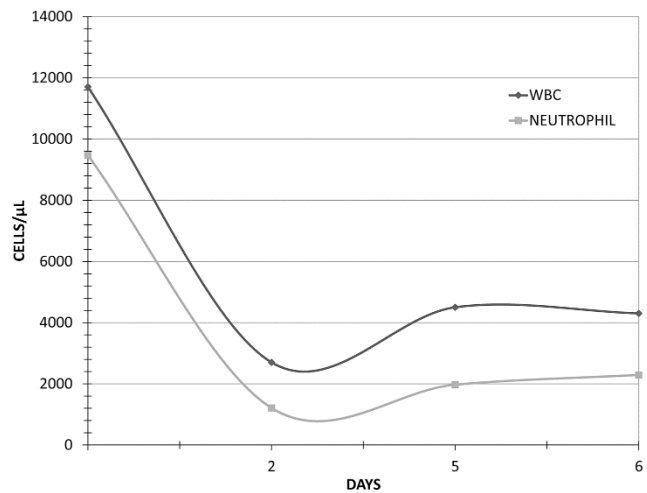
After hospitalization, his chest computed tomography (CT) scan revealed no evidence of underlying chronic lung disease (bronchiectasis, interstitial lung disease etc.). Serologic studies for Cytomegalovirus, Epstein-Barr virus and HIV were negative. Serum IgG, IgM and IgA levels were in normal range. After the resolution of neutropenia and these findings, no other laboratory testing was requested.

Causality assessment of the adverse drug reaction (ADR) was carried out using the World Health Organization-Uppsala Monitoring Centre (WHO-UMC) criteria [7] and Naranjo's Scale [8]. In the present case, neutropenia improved on withdrawal of moxifloxacin and treatment with clarithromycin. Therefore, ADR was probably caused by moxifloxacin (WHO-UMC criteria: Probable/Likely; Naranjo's Score: 7, probable) since there were no other factors that could have caused this ADR. Moxifloxacin was discontinued and clarithromycin was used to treat pneumonia. There is no increase in length of stay so the reaction was a moderate ADR with a severity level 3 according to Modified Hartwig and Siegel scale [9].

## Discussion

There were three cases of moxifloxacin-associated neutropenia. The first case was a cirrhotic patient with cellulitis. Parenteral moxifloxacin 400 mg/day was given to patient on day 2 of hospitalization. One day after the parenteral treatment leukopenia with neutropenia was noted. On day 5, the repeated laboratory tests revealed both worsening leukopenia

Figure 2. White blood cell and neutrophil count of the patient.



Day 2: leukopenia and neutropenia occurred; Day 4: moxifloxacin treatment was stopped and clarithromycin was started; Day 5: leukopenia and neutropenia resolved.

and neutropenia, so moxifloxacin was withdrawn and oral cefixime was started. On the next days both leukopenia and neutropenia improved [6].

The second case was a 32-year-old woman with metastatic breast cancer. She presented to emergency department with fever and cough and there was consolidation in the left inferior lobe on chest computed tomography. Moxifloxacin was started to the patient. The second day of the treatment, laboratory tests revealed leukopenia with neutropenia. On the fourth day of the treatment, leukopenia and neutropenia worsened, so moxifloxacin was withdrawn and oral clarithromycin was started. On the next days both leukopenia and neutropenia improved [2].

The third case was a 76-year-old man with a history of alcohol abuse and homelessness. He was taken to the hospital by his friends because of fever and cough and moxifloxacin 400 mg/day was started for empiric community-acquired pneumonia. Nearly 24 hours after his first dose of moxifloxacin, his WBC decreased by nearly 50% and continued to decrease each day until the moxifloxacin was stopped [4].

In a prospective, multicenter, observational study including hospitalized 2152 patients with the diagnosis of CAP, all patients were treated with moxifloxacin 400 mg once every 24 hours. The side effects of moxifloxacin therapy were diarrhea, nausea, urticaria, dizziness, dysgeusia and headache. No leukopenia and neutropenia was observed [10].

The mechanism of leukopenia and neutropenia induced with moxifloxacin therapy is unclear. Neutropenia occurs usually either from failure of production of neutrophils in the bone marrow or from their peripheral destruction [4]. There are multiple congenital and acquired causes of neutropenia due to infections (especially viral infections), nutritional deficiencies, immune reactions and drug therapy [3]. In our case, we excluded the viral infection, nutritional deficiency and other causes of acute decrease of leukocytes by using laboratory tests and considered the only reason of neutropenia to be an adverse drug reaction.

Drug induced neutropenia is usually immune-mediated. Immune-mediated neutropenia is a rapid onset form, taking a few hours to 1-2 days [3]. Hapten, apoptosis, immune complexes, complement mediated mechanism, direct toxicity of myeloid precursors, dose dependent inhibition of granulopoiesis are the immune-mediated mechanisms of neutropenia [3]. In our case and the other three cases, rapid recovery of leukopenia on the second or third day of moxifloxacin treatment calls into question the direct toxicity of myeloid

precursors and dose dependent inhibition of granulopoiesis.

Moxifloxacin has some immunomodulatory effects on inflammation besides its bactericidal activity. It inhibits the synthesis of inflammatory mediators and the activation of MAP kinase and NF- $\kappa$ B signaling cascades [11]. In the study of Beisswenger *et al.* [12] showed that moxifloxacin treatment resulted in low levels of pro-inflammatory mediators and neutrophils in the lungs of mice infected with *Streptococcus pneumoniae* and *Pseudomonas aeruginosa*. The immunomodulatory effects of moxifloxacin may result in the changes of WBC count like leukopenia with neutropenia at clinically relevant concentrations. Inhibition of the synthesis of inflammatory mediators in human peripheral blood might even change the other types of blood cells [12].

## Conclusions

Moxifloxacin-induced neutropenia may be more common and is an important adverse effect. Clinicians should be aware of this adverse effect and more observational studies about safety profiles of moxifloxacin are needed.

## References

- Zhu L, Wang N, Yang W, Zhang Y, Zhao X, Ji S (2014) Population pharmacokinetics of intravenous moxifloxacin 400 mg once-daily dosage in infected patients. *J Infect Chemother* 20:621-626.
- Berk V, Demiraslan H, Berk E, Karaca H, Inanc M, Bozkurt O, Ozkan M (2013) Moxifloxacin-associated neutropenia. *Scand J Infect Dis* 45:415-416.
- Bhatt V, Saleem A (2004) Drug-induced neutropenia—pathophysiology, clinical features, and management. *Ann Clin Lab Sci* 34:131-137.
- Chen W, Van Buren PN (2017) A case of severe neutropenia from short-term exposure to moxifloxacin. *J Investig Med High Impact Case Rep* 5: 1-4.
- Kern WV, Marchetti O, Drgona L, Akan H, Aoun M, Akova M, de Bock R, Paesmans M, Viscoli C, Calandra T (2013) Oral antibiotics for fever in low-risk neutropenic patients with cancer: a double-blind, randomized, multicenter trial comparing single daily moxifloxacin with twice daily ciprofloxacin plus amoxicillin/clavulanic acid combination therapy—EORTC infectious diseases group trial XV. *J Clin Oncol* 31:1149-1156.
- Chang CM, Lee NY, Lee HC, Lee IW, Wu CJ, Lin YS, Ko WC (2008) Moxifloxacin-associated neutropenia in a cirrhotic elderly woman with lower extremity cellulitis. *Ann Pharmacother* 42:580-583.
- World Health Organization (2016). Causality Assessment of Suspected Adverse Reactions. Available: <http://www.who-umc.org/Graphics/24734.pdf>. Accessed 16 June 2016.

- 8 Naranjo CA, Busto U, Sellers EM, Sandor P, Ruiz I, Roberts EA, Janecek E, Domecq C, Greenblatt DJ (1981) A method for estimating the probability of adverse drug reactions. *Clin Pharmacol Ther* 30:239-245.
- 9 Hartwig SC, Siegel J, Schneider PJ (1992) Preventability and severity assessment in reporting adverse drug reactions. *Am J Hosp Pharm* 49:2229-2232.
- 10 Kuzman I, Bezlepko A, Topuzovska IK, Rókus L, Iudina L, Marschall HP, Petri T (2014) Efficacy and safety of moxifloxacin in community acquired pneumonia: a prospective, multicenter, observational study (CAPRIVI). *BMC Pulm Med* 14:105.
- 11 Werber S, Shalit I, Fabian I, Steuer G, Weiss T, Blau H (2005) Moxifloxacin inhibits cytokine-induced MAP kinase and NF- $\kappa$ B activation as well as nitric oxide synthesis in a human respiratory epithelial cell line. *J Antimicrob Chemother* 55:293-300.
- 12 Beisswenger C, Honecker A, Kamyschnikow A, Bischoff M, Tschernig T, Bals R (2014) Moxifloxacin modulates inflammation during murine pneumonia. *Respir Res* 15:82.

**Corresponding author**

Tuğba KULA ATİK, MD.

Balıkesir Atatürk City Hospital, Department of Microbiology,

Gaziosmanpaşa Street, 10100, Balıkesir, Turkey

Phone:+90-555-7187392

E-mail :tkulaatik@gmail.com

**Conflict of interests:** No conflict of interests is declared.