

Case Report

Nocardia farcinica meningitis in a patient with high-grade astrocytoma

Elahe Nasri^{1,2}, Hamed Fakhim³, Aleksandra Barac^{4,5}, Saber Yousefi⁶, Kouros Aghazade^{7,8}, Darko Boljevic⁹, Massoud Mardani¹

¹ Infectious Diseases and Tropical Medicine Research Center, Shahid Beheshti University of Medical Sciences, Tehran, Iran

² Infectious Diseases and Tropical Medicine Research Center, Isfahan University of Medical Sciences, Isfahan, Iran

³ Department of Medical Parasitology and Mycology, Faculty of Medicine, Urmia University of Medical Sciences, Urmia, Iran

⁴ Clinic for Infectious and Tropical Diseases, Clinical Centre of Serbia, Belgrade, Serbia

⁵ Faculty of Medicine, University of Belgrade, Belgrade, Serbia

⁶ Department of Microbiology and Virology, Faculty of Medicine, Urmia University of Medical Sciences, Urmia, Iran

⁷ Infectious Diseases Research Center, AJA University of Medical Sciences, Tehran, Iran

⁸ Department of Infectious Disease, Faculty of Medicine, AJA University of Medical Sciences, Tehran, Iran

⁹ "Dedinje" Cardiovascular Institute, Belgrade, Serbia, School Of Medicine, University of Belgrade, Belgrade, Serbia

Abstract

We describe a case of 91-year-old male with astrocytoma who developed meningitis caused by *Nocardia farcinica*. He had a past medical history of anaplastic astrocytoma grade III. Endocranial computed tomography (CT) scan revealed mass lesion in the left occipital region associated with perilesional edema, without evidence of midline shift issue. The analyses of cerebrospinal fluid (CSF) revealed neutrophilic pleocytosis, hyperproteinorrachia and hypoglycorrachia. Combined antimicrobial therapy was initiated (vancomycin, meropenem, acyclovir). CSF culture revealed *Nocardia farcinica*. Susceptibility testing revealed intermediate sensitivity to meropenem and antibiotic treatment was switched to trimethoprim-sulfamethoxazole and imipenem. After 7 days of treatment the patient developed progressive dyspnea. The chest CT scan revealed bilateral pleural effusion and alveolar infiltrate mostly in the right lobe. Ceftriaxone was added to the therapy, but the outcome was lethal. *Nocardia* spp. should be considered as differential diagnosis in the patients with brain tumor or meningitis in the setting of immune suppression and corticosteroid use. CSF cultures should be incubated longer with aim to allow fastidious organisms to grow, such as *Nocardia* spp.

Key words: *Nocardia farcinica*; meningitis; brain abscess; astrocytoma.

J Infect Dev Ctries 2019; 13(9):854-857. doi:10.3855/jidc.11582

(Received 19 April 2019 – Accepted 04 June 2019)

Copyright © 2019 Nasri *et al.* This is an open-access article distributed under the Creative Commons Attribution License, which permits unrestricted use, distribution, and reproduction in any medium, provided the original work is properly cited.

Introduction

Nocardia species belongs to actinomycetes, which can be found in the environment, especially water, soil and decaying vegetation [1,2]. These pathogens are usually the opportunistic, but may cause infections in immunocompromised patients [3], or rarely in immunocompetent individuals [4]. The most common portal of entry in the human organism is respiratory tract, which can result in pulmonary nocardiosis, but also could be disseminated further by blood and develop systemic infection [5]. Certain species, especially *Nocardia farcinica*, have a predilection to disseminate from extraneural sites to the central nervous system (CNS) [5]. *Nocardia* brain abscesses account for only about 2% of all brain abscesses [6]. Despite the very low rate of *Nocardia* spp. CNS

infections, their early recognition is important because reported mortality rates range from 30% to 90% [6]. Reported data on antimicrobial resistance of *N. farcinica* showed increased resistance rate for cephalosporins, which could lead to the treatment failure and fatal outcome, as cephalosporins are the recommended as the first therapy option for CNS infections with the unknown origin [7,8-10].

We describe a case of 91-year-old male with astrocytoma who developed meningitis caused by *Nocardia farcinica*.

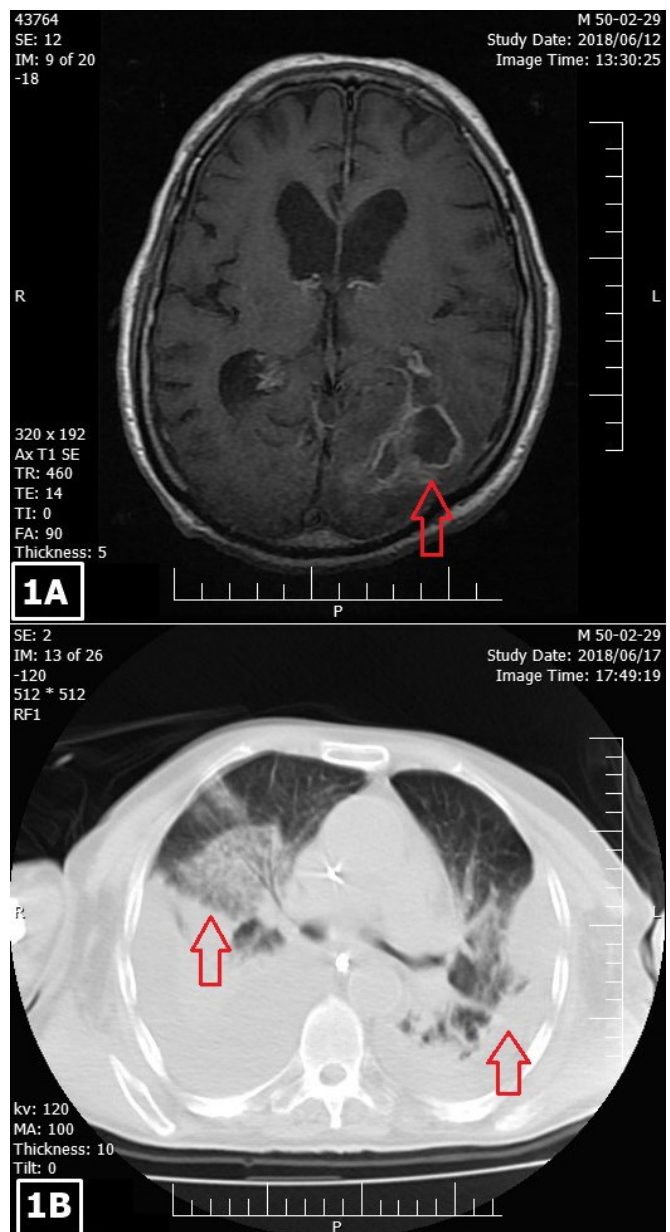
Case Report

A 91-year-old male was admitted to the Department of Infectious Diseases, Mehr hospital, Tehran, Iran with history of dizziness, lethargy, progressive headache,

fever and disorientation (Glasgow Coma Scale/GCS was 13/15) which lasted 7 days. Previously, he has been diagnosed with anaplastic astrocytoma grade III, revealed by biopsy 2 weeks before admission. The patient had no history of trauma, roadside accidents, or any other brain injury. Physical examination revealed abnormal, silent breath on the right base of the lung. Chest examination revealed crepitations on the right base of lung, heart sounds were normal, abdomen was soft and non-tender with no organomegaly. Neurological examination revealed right-sided hemiplegia 3/5 with extensor plantar reflex on the right side. No other symptoms were present such as neck stiffness, photophobia or papilledema. Laboratory findings showed white blood count 29.45 mm^3 ($4\text{-}10 \text{ mm}^3$) with neutrophilia of 93.7%, haemoglobin 10.4 g/dL, and glycaemia 145 mg/dL. Serological analyses for *Mycobacterium tuberculosis*, *Brucella* spp., HIV, HBV and HCV were negative. Chest-X ray revealed opacity in the right base of the lung. Endocranial CT scan revealed mass lesion in the left occipital region associated with perilesional edema, no evidence of midline shift issue. The cerebrospinal fluid (CSF) results revealed increased opening pressure (180 mm/H₂O) (normal range 100-200 mm/H₂O) pleocytosis with predominantly neutrophilic picture ($7441/\text{mm}^3$; 90% neutrophils and 10% lymphocytes), hyperproteinorrachia (76 mg/dL) and hypoglycorrhachia (CSF/plasma glycemia: 18 mg/mL/140 mg/mL). The next parenteral antimicrobial therapy was initiated with vancomycin 30 mg/kg every 12 hours, meropenem 2 gr every 8 hours, acyclovir 10 mg/kg every 8 hours, and dexamethasone 4 mg every 8 hours. Gram-staining and microscopy of CSF revealed Gram-positive branching filaments bacteria. CSF was additionally stained with Kinyoun acid-fast using weak acid (1% sulfuric acid), which revealed a mass of filamentous branching and rod-shaped elements which formed mycelia. The tentative diagnosis of chronic inflammation with nocardiosis was made. CSF was cultured on blood agar, brain heart infusion agar with 5% sheep blood (Oxoid Ltd., Basingstoke, Hampshire, England), chocolate agar (5% carbon dioxide atmosphere) and incubated at 37 °C for 7 days. Tiny, chalky white, and irregular colonies emitting an earthy odor appeared on blood and chocolate agar. Partially acid-fast staining from colonies, showed filamentous branching rods that were initially identified as *Nocardia* spp. The isolate was suspended in tryptic soy broth medium (TSB, Scharlab S.L, Barcelona, Spain) containing 2% peptone, 2% glucose, and 20% glycerol at -80°C for extra analysis and deposited at the

Reference Culture collection in the Cellular and Molecular Research Center (CMRC), Urmia, Iran. Endocranial magnetic resonance imaging (MRI) revealed irregular peripheral enhancing mass lesion in the left occipital region associated with perilesional vasogenic edema and compressive effect on occipital horn of the left lateral ventricle (Figure 1A). The mild intraventricular extension is suggested, associated with hydrocephalus. Findings were highly suggestive to malignant glial neoplasm (GMB, high-grade astrocytoma). Hemoculture was sterile, while culture of

Figure 1. 1A) Endocranial MRI revealed irregular peripheral enhancing mass lesion in the left occipital region (marked with red arrow); 1B) Chest CT scan revealed bilateral pleural effusion and alveolar infiltrate (marked with red arrows).



CSF revealed *Nocardia* spp. Genomic DNA was extracted from 7 days old culture and stored at -20 °C prior to use [11]. Briefly, the PCR amplification of 16S rRNA gene was done using the universal primers 16S-Cont-F (5' GATTAGATACCCTGGTAGT CCAC-3') and 16S-Con t-R (5'-CCCGGGAACGTATTCAC CG-3') [11,12]. Sequence data were adjusted, using Lasergene SeqMan software (DNASStar, Madison, WI, USA) and compared with the GenBank database. The DNA sequence of the 16S rRNA gene matched that of *N. farcinica* by showing a 99% similarity with GenBank CP031418.1. The molecular results confirmed the bacteriological diagnosis of the disease as *Nocardia* meningitis due to *N. farcinica*. Disk diffusion susceptibility testing for imipenem, meropenem, ceftriaxone, amoxicillin-clavulanic acid, trimethoprim-sulfamethoxazole and linezolid was performed in accordance with the Clinical and Laboratory Standards Institute guidelines [10]. Susceptibility testing revealed sensitivity to all tested antibiotics, except meropenem (intermediate), therefore meropenem was stopped and intravenous trimethoprim-sulfamethoxazole (TMP-SMX) was initiated (15 mg/kg/day of the trimethoprim component in three divided doses) together with imipenem (500 mg every 6 hours).

After 10 days of treatment, the patient developed dyspnea, chest X-ray demonstrated diffuse consolidation in the right lung, while the chest CT scan revealed bilateral pleural effusion and alveolar infiltrate mostly in the right lobe (Figure 1B). Ceftriaxone was added to the therapy in dose 2 gr every 12 hours IV. Unfortunately, the patient died after 2 days.

Discussion

In the presented case, CNS nocardiosis was developed in 91-years old person two weeks after subtotal endocranial resection because of high-grade astrocytoma, CSF leukocytosis, and new CNS lesions identified on MRI, which raised concerns of possible metastatic dissemination. There was also concern for CNS infection. This case illustrates that the differential diagnosis for progressive CNS malignancy should include opportunistic infections when presentation of the disease is atypically.

Clinical manifestations of CNS nocardiosis usually result from local effects of granulomas or abscesses in the brain, which are commonly multiple and, less commonly, the spinal cord or meninges [13,14]. CNS nocardiosis is usually misdiagnosed due to coexistence of brain mass or tumor, lack of clinical and laboratory signs of bacterial inflammation, silent invasion, which

all together make diagnosis difficult and cause late initiation of appropriate therapy [5]. Microbiological identification of *Nocardia* is sometimes late due to the slowly growing pattern of this species [12]. CSF cultures should be incubated longer with aim to allow fastidious organisms to grow, such as *Nocardia* spp. *N. farcinica* is more virulent than other members of this species and a few cases reported CNS infection [6]. *N. farcinica* is very pathogenic species and commonly multiresistant to antibiotics [3].

This is the first case report of CNS infection caused by *Nocardia* spp. from Iran, while a few case reports are reported from different regions [3,6,8]. TMP-SMX has been the drug of choice for the treatment of nocardiosis [10]. An empiric regimen for seriously ill patients with brain abscess due to *Nocardia* spp. should include TMP-SMX plus imipenem or meropenem [9,10]. *N. farcinica* is more likely to be resistant to imipenem, ceftriaxone, clarithromycin, tobramycin, and moxifloxacin [9,10].

Conclusion

Nocardia spp. should be considered as a differential diagnosis in the patients with brain tumor, abscess or rarely meningitis in the setting of immune suppression and corticosteroid use, but also in immunocompetent population. CSF cultures should be incubated longer with aim to allow fastidious organisms to grow, such as *Nocardia* spp.

Acknowledgements

This study was financially supported by a grant from the School of Medicine, Urmia University of Medical Sciences, Urmia, Iran (no. 97-06-32-1815) which we gratefully acknowledge. Dr. Aleksandra Barac's scientific work and research is supported by the Project of Ministry of Education, Science and Technology of the Republic of Serbia (No. III45005).

Author's contributions

EN, MM and KA conceptualised this paper, EN collected the data, EN, HF and AB drafted the first manuscript, AB and DB revised final revision of article, SY provided microbiological analysis and all authors provided critical feedback and contributed to the manuscript.

References

1. Haussaire D, Fournier PE, Djiguiba K, Moal V, Legris T, Purgus R, Bismuth J, Elharrar X, Reynaud-Gaubert M, Vacher-Coponat H (2017) Nocardiosis in the south of France over a 10-years period, 2004–2014. *Int J Infect Dis* 57: 13-20.
2. Restrepo A, Clark NM; Infectious Diseases Community of Practice of the American Society of Transplantation (2019) *Nocardia* Infections in solid organ transplantation: Guidelines

- from the Infectious Diseases Community of Practice of the American Society of Transplantation. *Clin Transplant* 28: e13509.
3. Budzik JM, Hosseini M, Mackinnon Jr AC, Taxy JB (2012) Disseminated *Nocardia farcinica*: literature review and fatal outcome in an immunocompetent patient. *Surg Infect* 13: 163-170.
 4. Valdezate S, Garrido N, Carrasco G, Medina-Pascual MJ, Villalón P, Navarro AM, Saéz-Nieto JA (2017) Epidemiology and susceptibility to antimicrobial agents of the main *Nocardia* species in Spain. *J Antimicrob Chemother* 72: 754-761.
 5. Rafiei N, Peri AM, Righi E, Harris P, Paterson DL (2016) Central nervous system nocardiosis in Queensland: A report of 20 cases and review of the literature. *Medicine* 95: e5255.
 6. Galacho-Harriero A, Delgado-López PD, Ortega-Lafont MP, Martín-Alonso J, Castilla-Díez JM, Sánchez-Borge B (2017) *Nocardia farcinica* brain abscess: report of 3 cases. *World Neurosurg* 106: 1053.
 7. Brown JM, Pham KN, McNeil MM, Lasker BA (2004) Rapid identification of *Nocardia farcinica* clinical isolates by a PCR assay targeting a 314-base-pair species-specific DNA fragment. *J Clin Microbiol* 42: 3655-3660.
 8. Torres O, Domingo P, Pericas R, Boiron P, Montiel JA, Vázquez G (2000). Infection caused by *Nocardia farcinica*: case report and review. *Eur J Clin Microbiol Infect Dis* 19: 205-212.
 9. Larruskain J, Idigoras P, Marimón JM, Pérez-Trallero E (2011) Susceptibility of 186 *Nocardia* sp. isolates to 20 antimicrobial agents. *Antimicrob Agents Chemother* 55: 2995-2998.
 10. Schlager R, Fisher MA, Hanson KE (2014) Susceptibility profiles of *Nocardia* isolates based on current taxonomy. *Antimicrob Agents Chemother* 58: 795-800.
 11. Nasri E, Fakhim H, Vaezi A, Khalilzadeh S, Ahangarkani F, Laal Kargar M, Abtahian Z, Badali H (2019) Airway colonization by *Candida* and *Aspergillus* species in Iranian cystic fibrosis patients. *Mycoses* 62: 434-440.
 12. Bittar F, Rolain J-M (2010) Detection and accurate identification of new or emerging bacteria in cystic fibrosis patients. *Clin Microbiol Infect* 16: 809-820.
 13. Delvenne E, Farnir F, Guiot J, Giot JB, Von Frenckell C (2017) Brain abscesses associated with a systemic infection by *Nocardia Farcinica*. *Rev Med Liege* 72: 340-343.
 14. Buelte D, Noth J, Mull M, Sellhaus B, Koch A, Queider M, Hüniger F, Gobelé R (2008) Different manifestations of the cerebral nocardiosis. *Nervenarzt* 79: 1432-1435.

Corresponding author

Massoud Mardani, MD, MPH, FIDSA
Infectious Disease Research Center, Shahid Beheshti University of Medical Sciences, Tehran, Iran
Arabi Ave, Daneshjoo Blvd, Velenjak, Tehran, Iran
Postal Code: 19839-63113
Tel: +98912113267
Fax: +98 21 22 43 34 55
Mail: masoud_mardani@ymail.com

Conflict of interests: No conflict of interests is declared.