

Case Report

Fatal pulmonary infection by trimethoprim-sulfamethoxazole resistant *Nocardia otitidiscaviarum*: report of two cases and review

Rushika Saksena¹, Dabet Rynga¹, Santosh Rajan¹, Rajni Gaind¹, Reetika Dawar², Raman Sardana², Manas Kamal Sen³, Jagdish Chandra Suri³

¹ Department of Microbiology, Vardhman Mahavir Medical College and Safdarjung Hospital, Delhi, India

² Department of Microbiology, Indraprastha Apollo Hospitals, Delhi, India

³ Department of Pulmonary Medicine, Vardhman Mahavir Medical College and Safdarjung Hospital, Delhi, India

Abstract

Introduction: *Nocardia otitidiscaviarum* is a rare cause of human infections, mostly causing cutaneous and lymphocutaneous infections of mild severity. We report two cases of fatal pulmonary infection caused by *Nocardia otitidiscaviarum* in elderly patients.

Methodology: Case 1: A 70-year old woman presented with fever and cough with expectoration for a month. On physical examination, she had tachypnea and inspiratory crepitations in bilateral basal regions. Case 2: A 74-year old man presented with productive cough with foul smelling expectoration, fever and shortness of breath for one week. On examination, he had tachypnea, bilateral wheezing and inspiratory crepitations. In both cases, sputum was sent to microbiology laboratory. On direct microscopy Gram-positive, finely branching filaments were observed which were acid fast with 1% sulphuric acid. Chalky white opaque wrinkled colonies with musty basement type odour were seen on blood agar. Both patients were treated empirically with trimethoprim-sulfamethoxazole for *Nocardia* infection after notification of microscopy findings however both expired on Day 2 and Day 5 of admission, respectively. Both isolates were susceptible to amikacin, linezolid, ciprofloxacin and gentamicin. They were resistant to trimethoprim-sulfamethoxazole, ampicillin, amoxicillin-clavulanic acid, erythromycin, and imipenem. Based on biochemical identification and antimicrobial susceptibility pattern, the organism was identified as *Nocardia otitidiscaviarum*. The identification was confirmed using MALDI-TOF (Vitek MS, Biomerieux, France).

Conclusion: Our report highlights the importance of early identification of *Nocardia* to species level to improve treatment outcomes especially in critically ill patients. Mass spectrometry can become an integral part of diagnostic algorithms for nocardiosis.

Key words: *Nocardia otitidiscaviarum*; pulmonary infection; fatal.

J Infect Dev Ctries 2020; 14(2):214-222. doi:10.3855/jidc.10169

(Received 11 January 2018 – Accepted 14 June 2019)

Copyright © 2020 Saksena *et al.* This is an open-access article distributed under the Creative Commons Attribution License, which permits unrestricted use, distribution, and reproduction in any medium, provided the original work is properly cited.

Introduction

Nocardia spp. are Gram-positive aerobic, branching bacilli, which are variably acid fast [1]. They are commonly found in soil, decomposing vegetation, water and air [1]. Pulmonary nocardiosis is the most common clinical presentation of infection as inhalation is the primary route of bacterial exposure [2]. The most common lung isolates of *Nocardia* have historically belonged to the formerly so-called *Nocardia asteroides* complex [3] subsequently identified mostly as *N. cyriacigeorgica* [4]. In recent reports, commonly isolated species include *N. asteroides*, *N. cyriacigeorgica*, *N. abscessus*, *N. nova*, *N. brasiliensis* and *N. farcinica* while other species are rarely reported [5-7].

Nocardia spp have been reported as a rare cause of infections in India although exact incidence of disease is difficult to estimate due to lack of awareness and

diagnostic facilities. Although a large study from north-west India reported 36 cases of pulmonary nocardiosis over the period of 5 years, species level identification was not performed [8]. Smaller case series of 6 – 8 cases from different regions of India have reported *N. asteroides* and *N. brasiliensis* as the most commonly isolated causes of pulmonary nocardia infections [9-11].

Nocardia otitidiscaviarum has been less frequently reported as a cause of human infections, accounting for only 3-5% of all nocardia infections [3,7]. Recent studies from India have reported sporadic infections with *Nocardia otitidiscaviarum* [10,11]. Solid organ transplant and immunosuppressive therapy were the common risk factors for infection. Most patients were young to middle aged. This report describes two cases of fatal pulmonary infection caused by *Nocardia otitidiscaviarum* in elderly patients.

Case Presentation

Case 1

A 70-year-old lady presented to the emergency referred from another hospital. She had cough with expectoration for the past one month. The expectoration was foul smelling and brownish in colour. She also complained of mild fever present on and off, shortness of breath and chest pain on both sides mostly while coughing for the same duration. The patient had been prescribed some antibiotics by a local physician but there was no improvement in her condition; instead symptoms had worsened over the past month.

She had no past history of tuberculosis, diabetes mellitus, hypertension, bronchial asthma, chronic lung disease, coronary artery disease. There was no history of smoking, alcohol or tobacco intake. She did not have any history of occupational exposure to hay. The patient had no history of steroid intake and was not immunocompromised.

On examination, the patient was conscious, oriented, afebrile but looked sick. Mild pedal edema was present which was pitting in nature. There were no signs of pallor, icterus, cyanosis or clubbing. She had tachypnea with a respiratory rate of 25 breaths per minute. There was decreased air entry in right inter scapular region and occasional crepitations in bilateral basal region (more marked on the left side as compared to the right). Tenderness was present in the right hypochondrium. No abnormality was detected on examination of cardiovascular and central nervous systems. The patient was admitted to the medicine ward and prescribed injection amoxicillin-clavulanate 2g thrice daily and tab azithromycin 500 mg once daily. The patient was then investigated. On chest X-ray, right lung showed consolidation and lower lobe collapse (Figure 1). Complete blood count revealed that her haemoglobin was 13.5 g/L, total leucocyte count was 16,300 cells/mm³ with 93.6% neutrophils, 5.1% lymphocytes, 1.3% monocytes, 1.4% basophils and 0.6% eosinophils. On arterial blood gas analysis, PaO₂ was 55.4 mmHg, PaCO₂ was 43.6 mmHg and blood pH was 7.45. Her liver function and renal function tests were within normal limits.

In view of worsening general condition, the patient was transferred to the pulmonary medicine ICU on day 2 of admission. The antimicrobial treatment was continued. Oxygen therapy was provided through mask (3-4L/hour). Patient was also nebulized with ipratropium bromide, salbutamol and budesonide. Sputum was sent to the microbiology laboratory for investigation. On gram staining, Gram-positive, finely branching beaded filaments were observed (Figure 2).

Modified acid fast staining using 1% H₂SO₄ for decolourization detected acid fast beaded branching filaments (Figure 2). Acid fast staining with 20% H₂SO₄ did not show any acid fast bacilli. The physician was

Figure 1. Patient 1 - Chest X-ray showing right lung consolidation and lower lobe collapse.

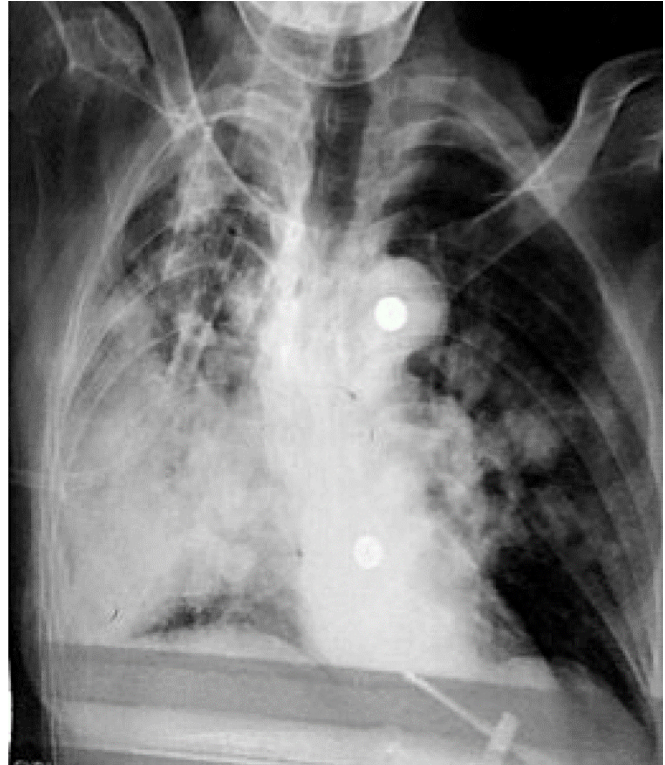
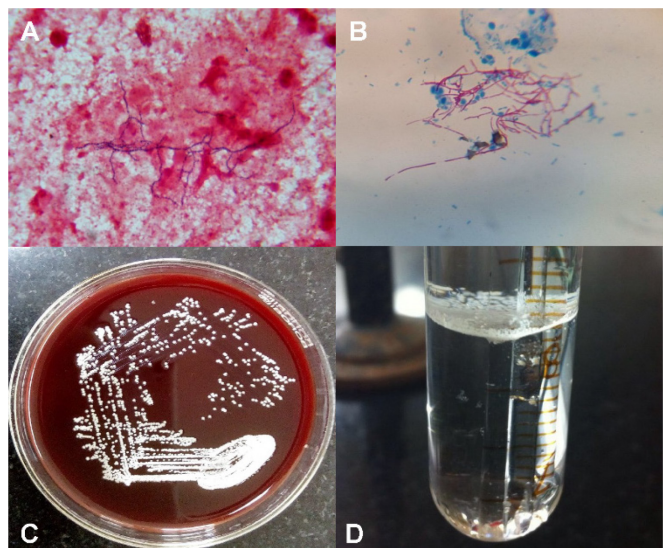


Figure 2. A) Gram stain showing Gram-positive, branching, filamentous bacilli B) Modified Ziehl-Neelsen stain – acid-fast, branching filaments C) Blood agar plate - chalky white wrinkled colonies D) Paraffin Bait Technique - white growth at the junction of paraffin and yeast nitrogen base medium.



notified regarding suspected pulmonary Nocardiosis and tab trimethoprim-sulfamethoxazole (TMP-SMX) 160/800 mg twice daily was added to the treatment. Unfortunately, the patient died the same night after receiving a single dose of TMP-SMX. As divided doses of 5 to 10 mg/kg per day of the trimethoprim component (or 25 to 50 mg/kg per day of sulfamethoxazole) are recommended to produce sulfonamide serum concentrations between 100 and 150 µg/mL [2], the prescribed dose may have been inadequate for treatment.

Sputum was inoculated on 5% sheep blood agar and MacConkey agar and incubated at 37 ± 2°C. On blood agar after overnight incubation chalky white dry opaque wrinkled colonies 1-2 mm in size with clear margin and musty basement type odour were observed (Figure 2). No growth was seen on MacConkey agar. On Gram staining, gram positive branching filaments were seen and modified Ziehl Neelsen (ZN) staining confirmed these were acid fast bacilli.

Case 2

A 74-year-old man presented to the outpatient department with productive cough, fever and shortness of breath for past one week. Sputum was foul smelling and dark yellow in colour. The above symptoms had been present on and off since last 18 months, but became severe since past 1 week. The patient had taken some medication over the past year for the symptoms with no apparent improvement. He could not recall the exact medication he had taken and no prescriptions were available with him. He had history of pulmonary tuberculosis over ten years ago and had been declared cured after taking antitubercular drugs for six months. There was no history of diabetes mellitus, hypertension, bronchial asthma, chronic lung disease or coronary artery disease. He gave history of smoking and alcohol

consumption off and on. There was no history of intake of steroid intake or immunosuppressed state.

On examination, the patient was conscious but disoriented. He was febrile and sick looking. He had tachypnea with a respiratory rate of 40 breaths per minute. On auscultation, bilateral wheezing and inspiratory crepitations were present. The patient was admitted in the department of pulmonary medicine and investigated. On chest X-ray, fibronectrotic changes in both lungs were detected. Complete blood count showed a total leucocyte count of 16,500 cells/mm³ with 94.6% neutrophils, 4.3% lymphocytes, 1.1% monocytes, 1.2% basophils and 0.2% eosinophils. On arterial blood gas analysis, PaO₂ was 56.2 mmHg, PaCO₂ was 42.4 mmHg and blood pH was 7.5. His liver and renal function tests were within normal limits.

The patient was prescribed *i. v.* meropenem 2 g thrice daily and *i. v.* colistin 2.5mg/kg/day in two divided doses as antibacterial therapy. He was also prescribed injection enoxaparin, oxygen by mask (3-4 litres/hour) and nebulized with ipratropium bromide, salbutamol and budesonide. On sputum microscopy by Gram staining, fine branching, gram positive filaments were observed (Figure 2). On modified ZN staining with 1% H₂SO₄, thin branching acid fast filaments were seen (Figure 2). The physician added tab TMP-SMX 160/800 mg thrice daily to the treatment after notification of the microscopy findings. After overnight incubation at 35 ± 2°C, on blood agar, chalky white dry wrinkled colonies, 1-2 mm in size were observed (Figure 2). Gram staining and modified acid fast staining, confirmed the growth of acid fast branching filaments morphologically resembling *Nocardia* spp. Despite appropriate antimicrobial treatment of 8mg/kg/d of trimethoprim (and 40 mg/kg/d of sulfamethoxazole), patient expired on the fifth day of admission.

Table 1. Scheme for identification of *Nocardia otitidiscaviarum* from clinical specimen.

Test	Finding
Gram staining	Gram-positive, finely branching beaded filaments
Ziehl-Neelsen staining with 1% H ₂ SO ₄	Acid-fast beaded branching filaments
Culture characteristics on sheep blood agar	Chalky white dry opaque wrinkled colonies 1-2 mm in size with clear margin and musty basement type odor
Paraffin bait technique	White growth at the junction of the paraffin and the yeast nitrogen base medium
Biochemical reactions	Reduction of nitrate; hydrolysis of xanthine, hypoxanthine and urea, and the inability to hydrolyse casein and tyrosine
Antibiotic susceptibility testing [1]	Susceptible to kanamycin, gentamicin, amikacin, trimethoprim-sulfamethoxazole, and ciprofloxacin; resistant to ceftriaxone, ampicillin, amoxicillin-clavulanic acid, carbenicillin, and imipenem (often resistant to all β-lactam antibiotics)
Mass spectrometry, 16s rRNA sequencing	For confirmation of species

Identification of species

Nocardia have the capability of utilizing paraffin as the sole source of carbon and therefore paraffin baiting technique was used to isolate suspected *Nocardia* spp. from the sample (Figure 2). A white growth was seen at the junction of the paraffin and the yeast nitrogen base medium and confirmed that the organism was *Nocardia* spp. The isolates reduced nitrate, hydrolysed urea and did not hydrolyse tyrosine. The scheme for identification of *Nocardia otitidiscaviarum* has been detailed in Table 1.

Antibiotic susceptibility testing was performed by Kirby Bauer disk diffusion method. Inoculum was prepared as previously described [12]. Isolates were subcultured on sheep blood agar to ensure purity. They were subsequently subcultured in Mueller-Hinton Broth (MHB) and incubated at $35 \pm 2^\circ\text{C}$ for 2-4 days in ambient air. The MHB tubes were periodically vortexed at high speed for 2 to 3 min to achieve a uniform suspension of the organisms, and vortexing was repeated prior to optical density determinations. After obtaining a turbidity equivalent to 0.5-1.0 McFarland, the suspension from MHB was uniformly swabbed onto a Mueller-Hinton agar plate and the following drugs were applied for susceptibility testing. The antibiotics used are described in Table 2. – amikacin, amoxicillin-clavulanic acid, ciprofloxacin, erythromycin, gentamicin, imipenem, linezolid and TMP-SMX [12]. Plates were incubated at $35 \pm 2^\circ\text{C}$ for 3 days and read after every 24 hours. For each antibiotic disk, the final diameter of the inhibition zone was recorded and compared with breakpoints described in Table 2 [13,14]. Both isolates were sensitive to amikacin, linezolid, ciprofloxacin and gentamicin. They were resistant to ampicillin, amoxicillin-clavulanic acid, erythromycin, TMP-SMX and imipenem. Based on biochemical identification and antimicrobial susceptibility pattern, the organism was identified as

Nocardia otitidiscaviarum [1]. The identification was confirmed using Vitek MS (Biomérieux, Marcy-l'Étoile, France), a matrix assisted laser desorption ionization-time of flight mass spectrometry (MALDI-TOF) system.

Discussion

Nocardiosis is an acute or chronic infection caused by members of genus *Nocardia*. Human infection with *Nocardia* spp. can result due to inhalation of mycelial fragments in case of pulmonary nocardiosis or contact with the bacteria via a cut or abraded skin (cutaneous nocardiosis-cellulitis, ulcers), and the infection can then disseminate to the brain, kidneys, joints, heart and bones [15]. Pulmonary disease is the most common manifestation of nocardia infection [1]. Extrapulmonary manifestations occur in 50% of cases with pulmonary disease and include spread to pleura, pericardium, mediastinum and superior vena cava [16].

N. otitidiscaviarum was first recognized from a Sumatran cavy or guinea pig with ear disease by Snijders in 1924 [17]. Reports of human infections first appeared in 1960s and first case of systemic infection was reported in 1974 [3]. In large studies, it was noted that *N. otitidiscaviarum* is isolated rarely, constituting about 3-5% of all *Nocardia* infections [3,7]. Reduced pathogenicity, lower prevalence in soil and incomplete identification up to species level have been postulated as various reasons for this low incidence [18]. In the present report, the species was determined based on biochemical identification and antimicrobial susceptibility pattern identification [1] and confirmed by mass spectroscopy (MALDI-TOF).

N. otitidiscaviarum has been reported to cause pulmonary, cutaneous, lymphocutaneous and disseminated infections involving brain, bones and liver in both immunocompromised and immunocompetent patients [18].

Table 2. Antibiotic disks used for antibiotic susceptibility testing and interpretation thresholds.

Antibiotic	Dose/disk (μg)	Interpretation threshold (mm)*	
		S	R
Ampicillin	10	≥ 21	< 16
Amoxicillin/clavulanic acid	20/10	≥ 23	< 16
Imipenem	10	≥ 24	< 17
Gentamicin	15	≥ 18	< 16
Amikacin	30	≥ 17	< 15
Erythromycin	15IU	≥ 22	< 17
Linezolid	30	≥ 28	< 24
Trimethoprim/sulphamethoxazole	1.25/23.75	≥ 16	< 10
Ciprofloxacin	5	≥ 25	< 22

*This table is adapted from guidelines of the Antibiogram Committee of the French Society of Microbiology (CA-SFM) devoted to Gram-positive bacteria [13].

Table 3. Studies reviewed, including patient characteristics, antimicrobial therapy and drug susceptibility profile.

Reference	Year	Age/sex	Associated risk factors	Immune status/ immunosuppressive therapy	Drug susceptibility	Treatment	Outcome
Princess <i>et al.</i> [19]	2018	51/M	Bronchial asthma	On corticosteroids	Resistant to TMP-SMX, amoxicillin-clavulanate; Susceptible to amikacin, ciprofloxacin, linezolid, imipenem, and ceftriaxone	Azithromycin + Doxycycline → Imipenem + TMP-SMX	Died
Savitha <i>et al.</i> [20]	2017	65/M	None	Immunocompetent	Resistant to amoxicillin-clavulanate; Susceptible to TMP-SMX, ceftriaxone, imipenem, linezolid	TMP-SMX	Recovered
Candel <i>et al.</i> [21]	2017	79/M	COPD	On corticosteroids	Resistant to TMP-SMX; Susceptible to aminoglycosides, beta-lactams and carbapenems	Levofloxacin + Vancomycin + Tobramycin	Died
Liu <i>et al.</i> [22]	2017	58/M	Cotton farmer, Hepatitis B Carrier	Immunocompetent	Not performed	TMP-SMX → Imipenem + Amikacin + TMP-SMX	Died
Sadamatsu <i>et al.</i> [23]	2017	72/F	Influenza A, Bronchial Asthma	On Inhaled corticosteroids	Resistant to ceftriaxone; Susceptible to TMP-SMX, minocycline, levofloxacin, imipenem	TMP-SMX + Minoocycline	Recovered
Deepa <i>et al.</i> [24]	2016	14/F	Rheumatic heart diseases	Immunocompromised	Resistant to amoxicillin-clavulanate, cefotaxime, ceftriaxone; Susceptible to gentamicin, ciprofloxacin, amikacin, TMP-SMX, tetracycline, imipenem	Ceftriaxone	Died
Mahgoub <i>et al.</i> [25]	2016	41/F	Bronchial asthma	Immunocompetent	Resistance to azithromycin, erythromycin, ceftazidime, penicillin, rifampin, and TMP-SMX; Susceptible to amikacin, cefditoren, ciprofloxacin, meropenem and streptomycin	TMP-SMX + Amikacin → Ceftriaxone + amikacin + ciprofloxacin	Recovered
Huang <i>et al.</i> [26]	2015	42/M	Alcoholic liver disease	On corticosteroids	Not performed	Piperacillin-tazobactam + vancomycin → meropenem + TMP-SMX + amikacin	Recovered
Ramamoorthi <i>et al.</i> [27]	2011	36/F	Farmer	Immunocompetent	Not performed	TMP-SMX	Recovered
Betran <i>et al.</i> [28]	2010	57/M	Diabetes mellitus, thrombocytopenia	On corticosteroids	Resistant to imipenem, amoxicillin-clavulanate, cefotaxime, tobramycin, ciprofloxacin; Susceptible to amikacin, gentamycin and TMP-SMX	TMP-SMX	Recovered
Peleaz <i>et al.</i> [29]	2009	85/F	Hypertension, coronary disease, COPD	On corticosteroids	Resistant to penicillin, ampicillin, vancomycin, erythromycin; Susceptible to TMP-SMX, imipenem, linezolid, gentamicin, amikacin, ciprofloxacin	TMP-SMX + imipenem → Linezolid	Died
Chawla <i>et al.</i> – 4 cases [10]	2009	1-23/M 2 – 17/M 3 – 62/F 4 – 36/M	Case 1 and 2 -Post renal transplant Case 3 and 4 – Pulmonary TB	Case 1 and 2 on Immunosuppressive therapy	All were susceptible to TMP-SMX	TMP-SMX + cefepime + amikacin	Recovered

Table 3 (continued). Studies reviewed, including patient characteristics, antimicrobial therapy and drug susceptibility profile.

Reference	Year	Age/sex	Associated risk factors	Immune status/ immunosuppressive therapy	Drug susceptibility	Treatment	Outcome
Dikensoy <i>et al.</i> [30]	2004	65 /M	Farmer	Immunocompetent	Susceptible to TMP-SMX, amikacin and tobramycin	Amikacin + TMP-SMX → TMP-SMX	Recovered
Yoshida <i>et al.</i> [31]	2004	69/M	Rheumatoid vasculitis	On Corticosteroids	Resistant to ampicillin, piperacillin, cefazolin, cefmetazole, imipenem, minocycline, vancomycin, TMP-SMX, erythromycin; Susceptible to gentamicin, levofloxacin	Imipenem + TMP-SMX → TMP-SMX + Gentamicin + Levofloxacin	Recovered
Tone <i>et al.</i> [32]	2002	66/F	Bronchial asthma	Immunocompetent	Not performed	TMP-SMX → Clarithromycin	Recovered
Sudou <i>et al.</i> [33]	2001	35/M	Cushing's disease	Immunocompromised	Not performed	TMP-SMX + Panipenem/betamipron	Recovered
Mari <i>et al.</i> [34]	2001	32/M	AIDS	Immunocompromised	Not performed	Antitubercular therapy	Recovered
Matsuo <i>et al.</i> [35]	2000	74/M	Farmer, smoking	Immunocompetent	Resistant to TMP-SMX, penicillin, piperacillin, imipenem, ceftazidime; Susceptible to amikacin minocycline, clarothromycin	TMP+ SMX → Clarithromycin + amikacin	Recovered
Taniguchi <i>et al.</i> [36]	1998	76/M	Tuberculosis	Immunocompetent	Resistant to imipenem, cloxacillin, cefazolin, cefmetazole, ofloxacin, fosfomycin; Susceptible to minocycline, TMP-SMX, tobramycin, clindamycin, kanamycin, netilmicin	Imipenem + minocycline → TMP+SMX	Recovered
Sandre <i>et al.</i> [37]	1997	59/M	HIV	Immunocompromised	Resistant to cefotaxime, tobramycin, gentamicin, Minocycline, erythromycin; Susceptible to TMP-SMX, amikacin	TMP-SMX + amikacin + cefotaxime	Recovered

The risk factors described for infections include smoking, sickle cell anemia, diabetes mellitus, chronic obstructive pulmonary disease, renal insufficiency, mixed connective tissue disorder, cirrhosis, human immunodeficiency virus (HIV) infection, malignancies, long-term corticosteroid therapy, and bone marrow or solid organ transplant [18]. The mean age of the patients has been reported as 56.61 ± 18.58 years [18].

The Pubmed and Google scholar database was searched with '*Nocardia otitidiscaviarum*', 'lung infection', 'pulmonary' and 'pneumonia' and 23 cases have been reported [19-37], which are presented in Table 3. Sixteen cases were male and seven were female patients. The median age at the time of presentation was 58 years (range 14-85 years). Nine of the twenty-three reported cases had associated chronic pulmonary diseases including bronchial asthma, chronic obstructive pulmonary disease (COPD), tuberculosis at the time of infection [19,20, 23,25,29,30,31,37]. Thirteen of these twenty-three cases were reported in immunocompromised patients. Corticosteroid therapy was identified as a risk factor for *N. otitidiscaviarum* in seven of the thirteen

immunocompromised cases [19,20,23,26,28,29,31]. In the other six reports, post-renal transplant [10], Cushing's disease [33], HIV- AIDS (acquired immunodeficiency syndrome) [34,37] and rheumatic heart disease [29] were identified as the cause of immunodeficiency. The remaining cases were reported in immunocompetent patients. Four of these otherwise healthy patients were engaged in farming where inhalation of dust and hay were postulated as a source of infection [22,27,30,35]. Only in a single case reported by Savitha *et al.* no associated risk factors like immunocompromised state, underlying lung disease or farming was observed [20].

Our patients were elderly, both over 70 years of age and a review of literature suggests that elderly patients were most commonly affected with *N. otitidiscaviarum* (Table 3). However, they did not suffer from any immunosuppressive disorders, underlying lung disease and gave no history of steroid intake. Both patients had normal renal and liver functions. Most cases of *N. otitidiscaviarum* recover after long term treatment (6-12 months) but there have been reports of mortality especially in case of severe and disseminated disease

[19,20,22,24,29]. Only five of the fifteen pulmonary cases reviewed were fatal including four patients who were immunocompromised. Both our patients had chronic illnesses where diagnosis of nocardiosis had been missed on previous examinations. On presentation to our hospital, the infection was severe and rapidly fatal within the first week of hospitalization. Only one case of fatal *N. otitidiscaviarum* in an immunocompetent patient from China has been reported so far [22].

In our patients, TMP-SMX was prescribed as empirical treatment for nocardiosis pending susceptibility testing. Both isolates later tested resistant to TMP-SMX and the patients expired before the change in treatment could be effected. Sulphonamides have been regarded as the drug of choice for *Nocardia* infections for more than 50 years and treatment is effective in most cases [1]. However, definitive treatment should be guided by antimicrobial susceptibility testing, especially for *N. otitidiscaviarum* as most studies have reported isolates which are resistant to beta-lactam drugs like ampicillin, amoxicillin-clavulanic acid, and imipenem and inconsistent susceptibility to sulphonamides is being increasingly reported (Table 3) [2,18,22]. We found resistance to TMP-SMX in seven of the seventeen (41.2%) cases where antibiotic susceptibility had been performed. Studies have suggested a combination of sulphonamides and amikacin with a carbapenem or a 3rd generation cephalosporin as optimum therapy for severe or disseminated infections with *N. otitidiscaviarum* [38,39]. CLSI recommends broth microdilution as a preferred method for susceptibility testing for *Nocardia* spp. [40] which is difficult to standardize and perform in routine diagnostic microbiology labs. In only fourteen of the twenty reports of pulmonary *N. otitidiscaviarum*, antimicrobial susceptibility had been performed. Therefore, it is imperative that species level identification is performed to guide the treatment protocol. Mass spectrometry or MALDI-TOF can provide rapid identification of the isolate. Studies evaluating the use of MALDI-TOF for routine identification of *Nocardia* spp. from clinical isolates have yielded accurate species-level identification up to 94-95% as compared with DNA sequence analysis using 16S rRNA and secA1 genes [41,42]. Identification of *Nocardia* spp. using MALDI-TOF was also found to be highly reproducible with 99% of replicates correctly identified using multiple kit lots, instruments, analysts, and sites [43].

Thus, antibiotic treatment can be modified in patients with severe disease or with poor response to

sulphonamides. We suggest that mass spectroscopy should be included in modern diagnostic algorithms in suspected *Nocardia* infections especially in critical patients.

Conclusion

N. otitidiscaviarum is a rarely isolated organism of low pathogenicity. However, it has been reported to cause severe pulmonary and disseminated infections which can be fatal. It also shows variable susceptibility to trimethoprim-sulfamethoxazole, the treatment of choice for nocardiosis [2]. Our report highlights the importance of early diagnosis of *Nocardia* species in order to improve outcomes especially in critically ill patients. Mass spectrometry can be an integral part of diagnostic algorithms for species level identification of *Nocardia* infections.

Authors' contributions

RS, DR and SR isolated and identified the organism, performed the antimicrobial susceptibility testing. RS and SR collected the data from the patient's medical records. RG was involved in supervision of the laboratory tests and crucially revised the manuscript. RD and RS confirmed the identification of isolate by MALDI-TOF. RS conducted the literature review and drafted the manuscript. MKS and JCS clinically managed the patients and revised the manuscript. All authors have read and approved the manuscript.

References

- 1 Brown-Elliott BA, Brown JM, Conville PS, Wallace RJ Jr (2006) Clinical and laboratory features of the *Nocardia* spp. based on current molecular taxonomy. *Clin Microbiol Rev* 19: 259-282.
- 2 Wilson JW (2012) Nocardiosis: Updates and clinical overview. Concise review for Clinicians. *Mayo Clin Proc* 87 Suppl 4: 403-407.
- 3 Beaman BL, Burnside J, Edwards B, Causey W (1976) Nocardial infections in the United States, 1972-1974. *J Infect Dis* 134: 286-289.
- 4 Conville PS, Witebsky FG (2007). Organisms designated as *Nocardia asteroides* drug pattern type VI are members of the species *Nocardia cyriacigeorgica*. *J Clin Microbiol* 45: 2257-2259.
- 5 Paige EK, Spelman D (2018) Nocardiosis: 7-year experience at an Australian tertiary hospital. *Intern Med J* 49: 373-379
- 6 Mazzaferri F, Cordioli M, Segato E, Adami I, Maccacaro L, Sette P, Cazzadori A, Concia E, Azzini AM (2018) Nocardia infection over 5 years (2011-2015) in an Italian tertiary care hospital. *New Microbiol* 41: 136-140.
- 7 Saubolle, M. A., & Sussland, D (2003) Nocardiosis: review of clinical and laboratory experience. *J Clin Microbiol* 41: 4497-4501.
- 8 Singh A, Chhina D, Soni RK, Kakkar C, Sidhu US (2016) Clinical spectrum and outcome of pulmonary nocardiosis: 5-year experience. *Lung India* 33: 398-403.

- 9 Dawar R, Girotra R, Quadri S, Mendiratta L, Rani H, Imdadi F, Bansal A, Sardana R. (2016) Epidemiology of Nocardiosis - A six years study from Northern India. *J Microbiol Infect Dis* 6: 60-64.
- 10 Chawla K, Mukhopadhyay C, Payyanur P, Bairy I (2009) Pulmonary nocardiosis from a tertiary care hospital in Southern India. *Trop Doct* 39: 163–165.
- 11 Shivaprakash MR, Rao P, Mandal J, Biswal M, Gupta S, Ray P, Chakrabarti A (2007) Nocardiosis in a tertiary care hospital in North India and review of patients reported from India. *Mycopathologia* 163: 267–274.
- 12 Ambaye A, Kohner PC, Wollan PC, Roberts KL, Roberts GD, Cockerill FR 3rd (1997) Comparison of agar dilution, broth microdilution, disk diffusion, E-test, and BACTEC radiometric methods for antimicrobial susceptibility testing of clinical isolates of the *Nocardia* asteroid complex. *J Clin Microbiol* 35: 847-852.
- 13 Antibiogram committee of the Societe Francasise de Microbiologie (2013) Recommendations 2013. Available: https://www.resapath.anses.fr/resapath_uploadfiles/files/Documents/2013_CASFM.pdf. Accessed 23 February 2019.
- 14 Lebeaux D, Bergeron E, Berthet J, Djadi-Prat J, Mounice D, Boiron P, Lortholary O, Rodriguez-Nava V (2018) Antibiotic susceptibility testing and species identification of *Nocardia* isolates: a retrospective analysis of data from a French expert laboratory, 2010-2015. *Clin Microbiol Infect* 25 Suppl 4: 489-495.
- 15 Ambrosioni J, Lew D, Garbino J (2010) Nocardiosis updated clinical review and experience at a tertiary center. *Infection* 38: 89–97.
- 16 Filice GA (2001) Nocardiosis. In: Niederman MS, Sarosi GA, Glassroth J, editors. *Respiratory infections*, 2nd edition. Philadelphia: Lippincott Williams & Wilkins. 457-466.
- 17 Snijders EP (1924) Report of the scientific part of the meetings of the Sumatra's Eastkurst department. *Medicine. Timesheet. Ned. Indië*. 64: 75-77. [Article in Dutch]
- 18 Jiang Y, Huang A, Fang Q (2016) Disseminated nocardiosis caused by *Nocardia otitidiscaviarum* in an immunocompetent host: A case report and literature review. *Exp Ther Med* 12 Suppl 5: 3339-3346.
- 19 Princess I, Ebenezer R, Ramakrishnan N, Nandini S (2018) Pulmonary nocardiosis and scrub typhus in an immunocompromised host. *J Glob Infect Dis* 10: 108.
- 20 Candel FJ, González J, Matesanz M, Gray R, Cías R, Candel L, Pontes JA, Roca-Arbonés V, Picazo JJ (2005) Bacteremic infection by *Nocardia otitidiscaviarum*: review of a case. *An Med Interna* 22: 489-492.
- 21 Thirouvengadame S, Muthusamy S, Balaji VK, Easow JM (2017) Unfolding of a clinically suspected case of pulmonary tuberculosis. *J Clin Diagn Res* 1: DD01-DD03
- 22 Liu C, Feng M, Zhu J, Tao Y, Kang M, Chen L (2017) Severe pneumonia due to *Nocardia otitidiscaviarum* identified by mass spectroscopy in a cotton farmer: A case report and literature review. *Medicine* 96 Suppl 13: e6526.
- 23 Sadamatsu H, Takahashi K, Tashiro H, Komiya K, Nakamura T, Sueoka-Aragane N (2017) Successful treatment of pulmonary nocardiosis with fluoroquinolone in bronchial asthma and bronchiectasis. *Respirol Case Reports* 5 Suppl 3: e00229.
- 24 Deepa R, Banu ST, Jayalakshmi G, Parveen JD (2016) Pleuropulmonary nocardiosis due to *Nocardia otitidiscaviarum* in a debilitated host. *Indian J Pathol Microbiol* 59: 240–242.
- 25 Mahgoub A, Gumaa SA, Joseph MR, Saleh MS, Elsheikh AH, Elkhailifa AI, Elhaj E, Salih RRM, Hamid ME (2016) Pulmonary nocardiosis caused by *Nocardia otitidiscaviarum* in an adult asthmatic female patient: The presence of acid-fast branching filaments is always significant. *S Afr Med J* 107: 43–45.
- 26 Huang CH, Hsueh PR, Chen YH (2015) *Empyema thoracis* due to *Nocardia otitidiscaviarum*. *J Microbiol Immunol Infect* 48: 580–581.
- 27 Ramamoorthi K, Pruthvi BC, Rao NR, Belle J, Chawla K (2011) Pulmonary nocardiosis due to *Nocardia otitidiscaviarum* in an immunocompetent host – a rare case report. *Asian Pac J Trop Med* 4: 414–416.
- 28 Betrán A, Villuendas MC, Rezusta, Moles B, Rubio MC, Revillo MJ, Boiron P, Bello S, Rodríguez-Nava V (2010) Cavitory pneumonia caused by *Nocardia otitidiscaviarum*. *Brazilian J Microbiol.* 41: 329-332.
- 29 Pelaez AI, Garcia-Suarez Mdel M, Manteca A, Melon O, Aranaz C, Cimadevilla R, Mendez FJ, Vasquez F (2009) A fatal case of *Nocardia otitidiscaviarum* pulmonary infection and brain abscess: Taxonomic characterization by molecular techniques. *Ann Clin Microbiol Antimicrob* 8: 11.
- 30 Dikensoy O, Filiz A, Bayram N, Balci I, Zer Y, Celik G, Ekinci E (2004) First report of pulmonary *Nocardia otitidiscaviarum* infection in an immunocompetent patient from Turkey. *Int J Clin Pract* 58: 210–213.
- 31 Yoshida K, Bandoh S, Fujita J, Tokuda M (2004) Pyothorax caused by *Nocardia otitidiscaviarum* in a Patient with rheumatoid vasculitis. *Intern Med* 43: 615–619.
- 32 Tone A, Matsuo K, Watanabe Y, Tamaoki A, Hiraki S (2002) Pulmonary *Nocardia otitidiscaviarum* infection in a patient with bronchiectasia. *Nihon Naika Gakkai Zasshi.* 91: 3037-3039.
- 33 Sudou A, Hashimoto T, Nakamura H, Yagyuu H, Sarashina G, Hatao E, Tuchida F, Adachi H, Kishi K, Matuoka T (2001) Pulmonary *Nocardia otitidiscaviarum* infection in a patient with Cushing's disease. *Nihon Kokyuki Gakkai Zasshi.* 39 Suppl 3: 210-214.
- 34 Mari B, Montón C, Mariscal D, Luján M, Sala M, Domingo C (2001) Pulmonary nocardiosis: Clinical experience in ten cases. *Respiration* 68: 382–388.
- 35 Matsuo K, Takeuchi M, Kawata N, Nabe M, Okamoto M, Tada S, Yamadori I, Kataoka M, Harada M (2000) Pulmonary *Nocardia otitidiscaviarum* infection in an immunocompetent host. *Nihon Kokyuki Gakkai Zasshi.* 38 Suppl 11: 844-849.
- 36 Taniguchi H, Mukae H, Ashitani J-I, Ihi T, Sakamoto A, Kohno S, Matsukura S (1998) Pulmonary *Nocardia otitidiscaviarum* infection in a patient with chronic respiratory infection. *Intern Med* 37: 872–876.
- 37 Sandre RM, Summerbell RC (1997). Disseminated *Nocardia otitidiscaviarum* in a patient with AIDS. *Can J Infect Dis* 8: 347-350.
- 38 Yildiz O, Doganay M (2006) Actinomycoses and *Nocardia* pulmonary infections. *Curr Opin Pulm Med* 12: 228–234.
- 39 Kim J, Kang M, Kim J, Jung S, Park J, Lee D, Yoon H (2016) A case of *Nocardia farcinica* pneumonia and mediastinitis in an immunocompetent patient. *Tuberc Respir Dis* 79: 101–103.
- 40 Brown BA, Wallace RJ Jr (1992) Broth microdilution MIC test for *Nocardia* spp. In: Isenberg HD, editor. *Clinical microbiology procedures handbook*. Washington, D.C: American Society for Microbiology. 5.12. 1–9.
- 41 Girard V, Mailler S, Polsinelli S, Jacob, Saccomani MC, Celliere B, Monnin V, van Belkum A, Hagen F, Meis JF,

- Durand G. (2016) Routine identification of *Nocardia* species by Maldi-Tof mass spectrometry. *Diagn Microbiol Infect Dis* 87: 7-10.
- 42 Marín M, Ruiz A, Iglesias C, Quiroga L, Cercenado E, Martín-Rabadán P, Bouza E, Rodríguez-Sánchez B (2018) Identification of *Nocardia* species from clinical isolates using MALDI-TOF mass spectrometry. 24: 1342.e5-1342.e8.
- 43 Body BA, Beard MA, Slechta ES, Hanson KE, Barker AP, Babady NE, McMillen T, Tang Y-W, Brown-Elliott BA, Iakhiaeva E, Vasireddy R, Vasireddy S, Smith T, Wallace RJ, Jr, Turner S, Curtis L, Butler-Wu S, Rychert J (2018) Evaluation of the Vitek MS v3.0 matrix-assisted laser desorption ionization–time of flight mass spectrometry system for identification of *Mycobacterium* and *Nocardia* species. *J Clin Microbiol* 56: e00237-218.

Corresponding author

Dr Rajni Gaiind
Professor, Department of Microbiology
Room No – 508, Fifth Floor, Vardhman Mahavir Medical College
and Safdarjung Hospital,
New Delhi, India – 110029.
Tel: +919810528344
Fax: +9111-26163072
Email: rgaiind5@hotmail.com

Conflict of interests: No conflict of interests is declared.