

Brief Original Article

High-resolution computed tomography enhances the diagnosis and follow-up of influenza A (H1N1) virus-associated pneumonia

Cristina AP Fontes¹, Alair Augusto SMD dos Santos¹, Solange A de Oliveira²

¹ Department of Radiology, Federal Fluminense University, Niterói, RJ, Brazil

² Department of Clinical Medicine – Infectious and Parasitic Diseases, Graduate Program in Medical Sciences, UFF, Niterói, RJ, Brazil

Abstract

Introduction: We present the findings on high-resolution computed tomography (HRCT) of influenza A (H1N1) virus-associated pneumonia of 140 patients with acute and post-acute pneumonia, totaling 189 exams in a retrospective observational study evaluating the importance of HRCT as a diagnostic imaging method in the acute phase and in the follow-up of pneumonia.

Methodology: We performed a retrospective observational study evaluating the HRCT findings of 140 adult patients with confirmed diagnosis of influenza A (H1N1) pneumonia and without other associated infectious processes. Chest X-ray exams were also performed in these patients. **Results:** The main HRCT findings of lung involvement were airspace consolidation (57 cases), ground-glass opacities (40 cases) and an association of both aspects (43 cases), with a predominantly bilateral and peripheral distribution.

Conclusions: HRCT is able to distinguish small lesions, such as small areas of consolidation or ground glass opacities, with little increase in lung attenuation, when chest X-rays was normal, allowing a prompt diagnosis and treatment after imaging.

Key words: Influenza A (H1N1); HRCT; end expiration HRCT; pneumonia; air trapping.

J Infect Dev Ctries 2020; 14(3):317-320. doi:10.3855/jidc.11665

(Received 17 May 2019 – Accepted 03 February 2020)

Copyright © 2020 Fontes *et al.* This is an open-access article distributed under the Creative Commons Attribution License, which permits unrestricted use, distribution, and reproduction in any medium, provided the original work is properly cited.

Introduction

Influenza A virus in its pandemic form, i.e. influenza A (H1N1) pdm09, has a highly transmissible, mutant, and lethal capacity, which is threatening the world population with high mortality rates. An estimated 284 000 deaths have occurred worldwide from H1N1 virus infections since 2009 when virus first emerged [1]. The leading cause of death has been influenza virus pneumonia and overlapping bacterial infections, leading to acute respiratory syndrome.

In adult patients with suspected H1N1 encountered at our service, chest and sinus X-ray are ordered by the medical emergency team for investigation of flu symptoms. Chest high resolution computed tomography (HRCT) is performed after chest X-ray or when physical examination findings show changes in pulmonary auscultation. The most common lung findings on HRCT have been bilateral multifocal ground glass opacities or areas of alveolar consolidation, or both, consistent with previous reports [2-4].

This study aimed to evaluate HRCT as a diagnostic imaging method in the acute phase and follow-up of

influenza A (H1N1) virus-associated pneumonia from the results of examinations performed for patients encountered at our service.

Methodology

We retrospectively reviewed the medical records of all patients with signs and symptoms suggesting the acute phase of the influenza A (H1N1) virus infection, confirmed with the real-time polymerase chain reaction of collected nasal swabs at emergency service in Niterói, Rio de Janeiro, Brazil. All HRCT examinations were performed in the radiology department by the hospital medical team without intravenous administration of iodinated contrast media. HRCT scans were obtained at end inspiration following the routine protocol of chest examinations for the lungs and mediastinum, and at end inspiration following a specific protocol for further investigation of the pulmonary parenchyma, and at end expiration in lucid patients. End expiration HRCT scans were used to investigate the distal small airways. Patients admitted to the intensive care unit (ICU) also underwent HRCT examination in the radiology department.

Our evaluation of HRCT findings of influenza A (H1N1) virus-associated pneumonia was focused on pulmonary parenchymal abnormalities. All scans were reviewed by two radiologists experienced in thoracic radiology. Pulmonary lesions are described using terminologies in the Glossary of Terms for Thoracic Imaging [5].

The study was approved by the Ethics Committee of Hospital Universitário Antônio Pedro and Universidade Federal Fluminense, approval number CMM HUAP 15811. Given the observational nature of the study, no complex statistical methods were used. Only a descriptive analysis was performed, and results are expressed in the paper as counts and percentages.

Results

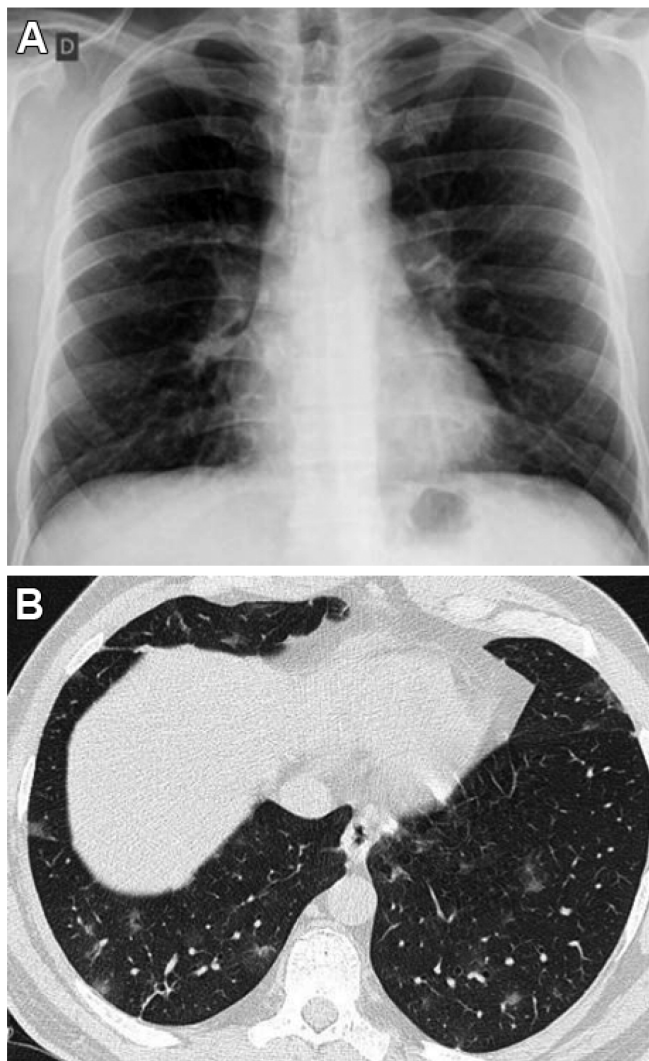
We included 140 patients diagnosed with influenza A (H1N1) virus-associated pneumonia using a total of 189 chest HRCT examinations. The patients included 71 men and 69 women, with a mean age of 48.2 years (range 19 to 94 years). For patients with a worsening clinical condition (19.3%), follow-up examinations were also performed, as requested by the medical team, to look for overlapping bacterial lung infections.

Comorbidities included the human immunodeficiency virus infection/acquired immunodeficiency syndrome, systemic lupus erythematosus, polymyositis, heart disease (cardiac valve disease, chronic atrial fibrillation, systemic arterial hypertension), chronic obstructive pulmonary disease, idiopathic pulmonary fibrosis, obesity, cancer in the past, and also smoking.

Air trapping was observed on end expiration HRCT scans in six patients, two of whom had comorbidities. The two patients who died were older adults (aged 92 and 94 years) with comorbidities (idiopathic pulmonary fibrosis and history of breast cancer and obesity).

The main HRCT findings of lung involvement were airspace consolidation (57 cases), ground-glass opacities (40 cases) and a combination of both (43 cases), with a predominantly peripheral distribution. In 21 cases of ground glass opacities, no abnormalities

Figure 1. Same-day chest X-ray and HRCT scan of an adult patient. In (A) showing normal chest X-ray findings and in (B) scattered ground glass opacities in the lower lobes on HRCT.



were detected on chest X-ray. Table 1 shows the principal HRCT findings of the pulmonary parenchymal involvement.

In the 21 cases of acute phase of pneumonia with normal findings on chest X-ray, pulmonary lesions with ground glass opacities, with or without small areas of consolidation, were observed on HRCT. Figure 1

Table 1. Main high-resolution computed tomography findings of lung involvement in influenza A (H1N1)-associated pneumonia confirmed with reverse-transcriptase polymerase chain reaction.

	Lung involvement on HRCT (no. of cases)	
Lesion areas	Multifocal (129)	Focal (11)
Laterality	Bilateral (134)	Unilateral (6)
Distribution	Central (5)	Peripheral (87)
Affected zones (as per division of the lung into thirds)	Markedly in the lower third (44)	Diffuse (48) Random (96)

For patients who underwent more than one HRCT examinations, the HRCT scan revealing the worst condition was selected; in the study of the areas affected by lesions, we divided the lung into thirds in the coronal plane, according to other authors. HRCT (high-resolution computed tomography).

illustrates the chest X-ray and HRCT scan of a patient, on the same day.

Other associated findings observed on follow-up HRCT were the crazy-paving pattern, parenchymal bands, peribular thickening, interlobular septal thickening, pleural effusion, and consolidation with volume loss; however, these findings are not specific to influenza A (H1N1) virus-associated pneumonia. HRCT clearly showed the pathological findings in the pulmonary parenchyma, which translate into diffuse alveolar damage [2,4,6].

Discussion

Technological advances in CT have revolutionized diagnostic imaging, allowing monitoring of medical conditions at various levels [7]. CT equipment is available in most hospitals and offers fast and easy operation. We believe that chest CT or HRCT, rather than chest X-ray, should be performed in patients with a suspected pulmonary infectious process, despite the exposure to ionizing radiation. However, attention should be paid to over-ordering of CT examinations and the presence of pregnancy.

In this pandemic influenza A(H1N1) virus infection, age has had a great influence on the individual risk, with a higher incidence in young adults and higher lethality in older adults or patients with comorbidities. Comorbidities, including chronic diseases, as well as pregnancy and puerperium may increase the risk of influenza-related complications, such as myocarditis, pericarditis, bronchiolitis, encephalitis, and bacterial infection. Signs and symptoms may vary with the age and clinical condition, and other autoimmune processes may be involved as well [8].

Morens *et al.* [9], in a recent article on the lessons learned from the 1918 influenza pandemic and the possible threat of another pandemic, raised the possibility that patients could suddenly need intensive care because of pulmonary complications. This finding was consistent with our small series, as clinical worsening of patients was accompanied by worsening of pulmonary findings on HRCT. This observation led us to conclude that many requests for chest X-ray should have been replaced by requests for HRCT because of its higher ability to display the lesions, thus allowing immediate and appropriate treatment with antivirals. Treatment of patients with influenza incurs a high cost, particularly when there are associated comorbidities [10], and the indication of CT examination can help reduce it.

Ensuring access to hospital admission when indicated is also a factor that can change the morbidity and mortality rates of this infection.

Conclusion

In conclusion, chest X-ray is non-specific for influenza A (H1N1) virus-associated pneumonia, while HRCT is able to distinguish small lesions, such as small areas of consolidation or ground glass opacities, with little increase in lung attenuation, allowing a prompt diagnosis and treatment after imaging. This would also prevent virus transmission by these patients. HRCT is the best imaging method to demonstrate lung changes in the different phases of this pneumonia, and its indication should be prioritized in patients with comorbidities.

We believe that one of the many factors to consider in this scenario is the development of an effective vaccine that can be readily available at a reasonable cost in the several countries affected.

Acknowledgements

We thank all residents and physicians at our hospital, the emergency department and ICU team members who have been involved in the care of patients with influenza from the time of diagnosis to the final follow-up, particularly MD. Alexandre Limpas Cunha.

This work was conducted at the Federal Fluminense University, Antônio Pedro University Hospital.

References

1. Dawood FS, Iuliano AD, Reed C, Meltzer MI, Shay DK, Cheng PY, PY, Bandaranayake D, Breiman RF, Brooks WA, Buchy P, Feikin DR, Fowler KB, Gordon A, Hien NT, Horby P, Huang QS, Katz MA, Krishnan A, Lal R, Montgomery JM, Mølbak K, Pebody R, Presanis AM, Razuri H, Steens A, Tinoco YO, Wallinga J, Yu H, Vong S, Bresee J, Widdowson MA (2012) Estimated global mortality associated with the first 12 months of 2009 pandemic influenza A H1N1 virus circulation: a modelling study. *Lancet Infect Dis* 12: 687-695.
2. Marchiori E, Zanetti G, Hochhegger B, Rodrigues RS, Fontes CAP, Nobre LF, Mançano AD, Meirelles G, Irion KL (2010) High-resolution computed tomography findings from adult patients with Influenza A (H1N1) virus-associated pneumonia. *Eur J Radiol* 74: 93-98.
3. Marchiori E, Zanetti G, Fontes CAP, Santos MLO, Valiante PM, Mano CM, Teixeira GHC, Hochhegger B (2011) Influenza A (H1N1) virus-associated pneumonia: High-resolution computed tomography-pathologic correlation. *Eur J Radiol* 80: e500-504.
4. Li P, Zhang JF, Xia XD, Su DJ, Liu BL, Zhao DL, Liu Y, Zhao D-H (2012) Serial evaluation of high-resolution CT findings in patients with pneumonia in novel swine-origin influenza A (H1N1) virus infection. *Br J Radiol* 85: 729-753.
5. Hansell DM, Bankier AA, MacMahon H, McLoud TC, Müller NL, Remy J (2008) Fleischner Society: glossary of terms for thoracic imaging. *Radiology* 246: 697-722.

6. Tanaka N, Emoto T, Suda H, Kunihiro Y, Matsunaga N, Hasegawa S, Ichiyama T (2012) High-resolution computed tomography findings of influenza virus pneumonia: a comparative study between seasonal and novel (H1N1) influenza virus pneumonia. *Jpn J Radiol* 30: 154-161.
7. Rubin GD (2014) Computed tomography: revolutionizing the practice of medicine for 40 years. *Radiology*. 273 Suppl 2: 45-75.
8. Azambuja MI (2008) Connections: can the 20th century coronary heart disease epidemic reveal something about the 1918 influenza lethality? *Braz J Med Biol Res* 41: 1-4.
9. Morens DM, Taubenberger JK (2018) Influenza cataclysm, 1918. *N Engl J Med* 379: 2285-2287.
10. Koul PA, Bhavsar A, Mir H, Simmerman M, Khanna H (2019) Epidemiology and costs of severe acute respiratory infection

and influenza hospitalizations in adults with diabetes in India. *J Infect Dev Ctries*. 13: 204-211. doi: 10.3855/jidc.10903.

Corresponding author

Cristina Asvolinsque Pantaleão Fontes
Federal Fluminense University
Antônio Pedro University Hospital
Rua Mem de Sá 169/1101
24220-261 - Niterói, RJ
Brazil
Tel: +55-21-26299077
Fax: +55-21-26299076
Email: cfontes@id.uff.br; cristinasvolinsque@gmail.com

Conflict of interests: No conflict of interests is declared.