

Case Report

Purpureocillium lilacinum as unusual cause of pulmonary infection in immunocompromised hosts

Manuel Alejandro Salazar-González¹, Jorge Rafael Violante-Cumpa¹, Christian Gerardo Alfaro-Rivera², Hiram Villanueva-Lozano³, Rogelio de Jesús Treviño-Rangel³, Gloria María González³

¹ Department of Internal Medicine. Hospital Universitario Dr. José Eleuterio González, Universidad Autónoma de Nuevo León. Monterrey, México

² Department of Infectious Diseases. Hospital Universitario Dr. José Eleuterio González, Universidad Autónoma de Nuevo León. Monterrey, Nuevo León, México

³ Department of Microbiology. Facultad de Medicina, Universidad Autónoma de Nuevo León. Monterrey, Nuevo León, México

Abstract

Purpureocillium lilacinum (*P. lilacinum*) is an emergent pathogenic mold that presents more commonly as an ocular infection, cutaneous and/or subcutaneous infections in patients that are usually immunocompromised. A pulmonary presentation is rare, the clinical presentation is fever and cough with radiographic presentation as pleural effusion, single-lung consolidation, and cavitary pulmonary disease. We present a case of a patient with hematologic malignancy with febrile neutropenia; after receiving chemotherapy, the patient developed a pulmonary infection with multiple bilateral consolidations shown in the thoracic computed tomography scan. Fever persisted in spite of the use of wide-spectrum antibiotics and amphotericin. Bronchoalveolar lavage was performed and the samples were cultured, isolating in the Sabouraud Dextros Agar a filamentous fungi growth with purple colonies that were identified morphologically as *P. lilacinum* and later it was confirmed by molecular methods. Once the infectious agent was identified, we continued amphotericin and oral voriconazole was added to the treatment with complete resolution of the infection. The report aims to create awareness of this emerging infectious disease, as there is little information concerning the treatment and the prognosis of patients infected by *P. lilacinum* with a pulmonary presentation.

Key words: *purpureocillium lilacinum*; fungal infection; mycology; pneumonia; immunocompromised host; infectious diseases.

J Infect Dev Ctries 2020; 14(4):415-419. doi:10.3855/jidc.12235

(Received 20 November 2019 – Accepted 19 February 2020)

Copyright © 2020 Salazar-González *et al.* This is an open-access article distributed under the Creative Commons Attribution License, which permits unrestricted use, distribution, and reproduction in any medium, provided the original work is properly cited.

Introduction

Purpureocillium lilacinum (*P. lilacinum*), previously known as *Paecilomyces lilacinus* is an emerging pathogenic mold found worldwide in soil, decaying vegetation, nematodes and as a contaminant in laboratory air. This agent is known to cause predominantly ocular and subcutaneous infection, and in rare cases, there have been reports of pulmonary infections [1-2]. We present the first case of bilateral pneumonia due to *P. lilacinum* in a hospitalized immunocompromised patient and a review of the literature. The first aim of this report is to describe the clinical evolution, treatment options and prognosis of this emerging infectious disease.

Case Report

A 51-year-old female with no relevant medical history was admitted to the Emergency Department (ED) with a history of 6 months with malaise and

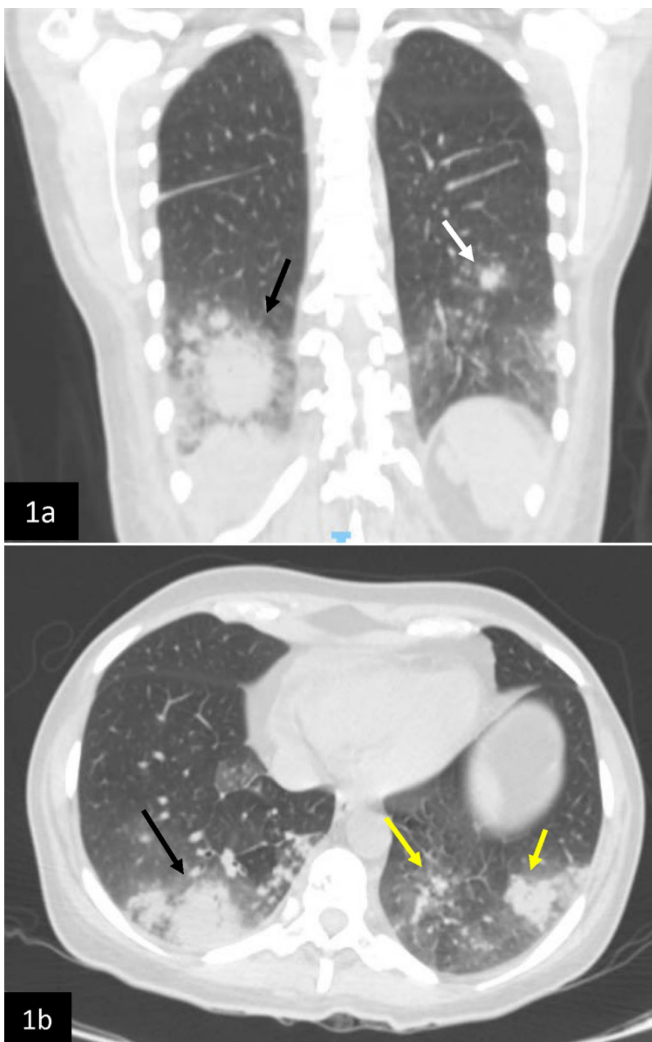
dyspnea. At physical examination, the patient presented general paleness and no other relevant data. Vital signs were stable with blood pressure 110/70 mmHg, heart rate 74 beats per minute, respiratory rate 14 breaths per minute and temperature of 36.2 degrees Celsius (°C). Laboratory tests showed hemoglobin of 4.68 g/dL, white blood count of 1.68 K/ μ L, with neutropenia of 0.618 K/ μ L, and thrombocytopenia of 23.4 K/ μ L. Peripheral smear showed the presence of blasts, therefore a bone marrow aspirate was performed confirming the diagnosis of acute myeloid leukemia (FAB M4) by cytogenetics and cytometry evaluation.

The patient was admitted to the internal medicine ward for the administration of chemotherapy consisting of cytarabine and mitoxantrone 150 mg and 20 mg once daily (QD) for 5 days, respectively. Prophylactic itraconazole, acyclovir, and levofloxacin were initiated on admission due to severe neutropenia which persisted throughout the hospitalization; the patient also required

multiple transfusions of packed red cells along with two platelet apheresis due to persistent pancytopenia. On day fifth, the patient presented a fever of 38.6°C which did not respond to acetaminophen, dyspnea, and non-productive cough; thus imipenem 500 mg every 6 hours was started. Because of the new-onset fever, a chest X-ray and a sinus computed tomography (CT) scan was taken. Sinus CT scan was unremarkable but the chest X-ray showed a right lung infiltrate. A thorax CT scan was performed reporting bilateral lung infiltrates in the right lower lobe with the presence of a ground-glass opacity surrounding a pulmonary nodule (halo sign) and in the left lung two smaller consolidations in the

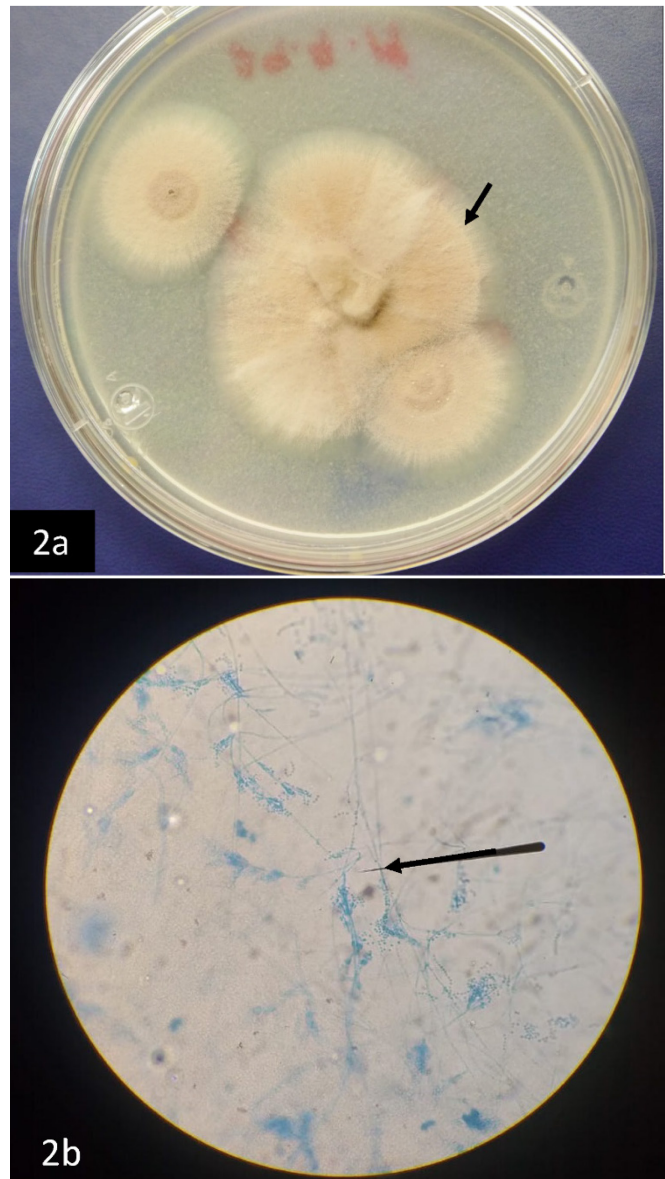
lower lobe (Figure 1a and Figure 1b). Based on the image and the clinical presentation we added intravenous vancomycin 1g twice daily (BID) and amphotericin B (AMB) deoxycholate 50 mg QD to the treatment because of the suspicion of invasive pulmonary aspergillosis. Fever persisted (38-39°C) in spite of the wide spectrum treatment, thus we performed a bronchoscopy with bronchoalveolar lavage (BAL) and samples were taken for cultures of bacteria, fungi, mycobacteria, diverse cytology, and GeneXpert MTB/RIF.

Figure 1. Chest CT scan.



1a. Black arrow indicates a lung consolidation with halo sign in the posterior segment of right lower lobe typically seen in fungi and mycobacterial infections and the white arrow indicates a consolidation in the left lung (coronal thorax CT view); 1b. Black arrow indicates a big consolidation in the posterior segment of right lower lobe typically seen in fungi and mycobacterial infections and the yellow arrows indicates smaller consolidations in the left lung (axial thorax CT view).

Figure 2. Macro-view and microscopic view of *P. lilacinum* culture.



2a. Black arrow is showing a macro-view of violet-colored colonies; 2b. Black arrow indicating the chains of elliptical conidia with divergent branches characteristic of *Purpureocillium lilacinum*.

The patient persisted with fever but with no deterioration in her clinical status. Cultures growth were negative except for the Sabouraud dextrose agar which presented a filamentous fungi growth with a light purple coloration at the center of the colony (Figure 2a), and a microscopic view of phalids with elongated necks bearing divergent branches of elliptic conidia (Figure 2b). The fungus was identified morphologically as *Purpureocillium lilacinum* (*P. lilacinum*) and its identity was confirmed by molecular methods. Genomic DNA of the fungus was extracted by the use of a commercial kit (Quick-DNA™Fungal/Bacterial MiniprepKit - Zymo Research, Irvine CA, USA) and the non-coding fungal region ITS was amplified and sequenced by the Sanger method. BLAST sequence analysis led to the identification of *P. lilacinum* (GenBank accession number: MN396442). Antifungal susceptibility of the isolate was determined by the broth microdilution method in accordance with the CLSI document M38-3rd Edition [1], obtaining the following results: AMB = 8 µg/mL and voriconazole = 1 µg/mL. Antibacterial agents were suspended and voriconazole (4mg/kg BID) was added to the AMB treatment with eventual resolution of fever and improvement of the respiratory symptoms. We continued the treatment in the hospital for 21 days and finally, the patient was discharged asymptomatic with oral voriconazole for 6

weeks and follow-up in the hematology and infectious diseases clinic.

Discussion

P. lilacinum, previously known as *Paecilomyces lilacinus*, is a saprophytic and filamentous mold that exists in soil and decaying vegetation, it can produce conidia and spores in human tissue and is usually not a pathogenic mold [2]; however, in recent decades it has become an emergent pathogen causing of infection mainly in immunocompromised hosts. There are risk factors associated with acquiring this infection, for example, patients receiving antibacterial treatment, oncological chemotherapy, primary or acquired immunodeficiency, bone marrow and solid organ transplantation [3,4].

P. lilacinum is an agent that cause hyalohyphomycosis, with a variety of clinical presentations, the most common correspond to oculomycosis and cutaneous infections, the most frequent ocular manifestations are keratitis and endophthalmitis, these are usually associated with intraocular lens implantation, non-surgical trauma with or without a foreign body, use of contact lenses and ophthalmic surgery. Cutaneous and subcutaneous infections come in a wide variety of presentations, consisting of solitary or disseminated skin eruptions,

Table 1. Summary of cases reported with pulmonary *P. lilacinum* infection.

Case	Reference	Country	Age/ Gender	Clinical Presentation	Predisposing Factor(s)	Diagnostic method	Treatment	Outcome
1	Fenech and Mallia 1972 [7]	Malta	20/M	Pleuritic Pain, Pleural Effusion, No Evidence of Dissemination	Inhalation of clover dust	Pleural effusion culture	Amphotericin	Recovered
2	Mormede <i>et al.</i> 1984 [8]	France	58/F	Pleural Effusion, Diffuse Reticonodular Lesion	Interstitial lung disease, Corticosteroids	Pleural effusion culture	Antibiotics, antiinflammatory, no antifungal given	Died of hepatic complications
3	Liu <i>et al.</i> 1998 [9]	United States	Not available	Lung Disseminated	Acute lymphoblastic, leukemia	Lung biopsy culture	Not available	Recovered
4	Ono <i>et al.</i> 1999 [10]	Japan	57/M	Lung Abscess	Not available	Not available	Lobectomy	Recovered
5	Mullane K <i>et al.</i> 2007 [11]	United States	60/M	Lung Consolidation, Nodules on CT Scan	Multiple Myeloma	BAL culture	Posaconazole	Recovered
6	Khan Z <i>et al.</i> 2012 [6]	Kuwait	80/F	Fever, Cavitory Pulmonary Disease	Asthma, diabetes, rheumatoid arthritis	GenBank of BAL culture	Voriconazole	Death not related
7	Peghin M. <i>et al.</i> 2013 [12]	Spain	34/M	Nodules on CT Scan	Histiocytosis, Bilateral Lung Transplant	Lung biopsy culture	Voriconazole + n-LAB	Death related
8	Hobson <i>et al.</i> 2013 [13]	United States	48/M	Neutropenic Fever, Lung Consolidation	Acute Lymphoblastic Leukemia	BAL culture	Posaconazole	Recovered
9	Tzaikou <i>et al.</i> 2019 [14]	Australia	72/M	Neutropenic Fever, Cavitory Pulmonary Disease	Myeloid Leukemia, Chemotherapy	Sputum and biopsy culture	Lobectomy	Not specified
10	Actual case	Mexico	51/F	Neutropenic Fever, Bilateral Lung Consolidation Angioinvasive- Halo sign	Myeloid Leukemia, Chemotherapy	GenBank of BAL culture	Voriconazole	Recovered

CT: computed tomography; F: female; M: male; BAL: bronchoalveolar lavage; n-LAB: nebulized liposomal amphotericin; COPD: chronic obstructive pulmonary disease.

macules, vesicles, papules, nodules with necrotic center and soft-tissue infections [4].

A wide variety of unusual clinical manifestations have been associated with *P. lilacinum*, there are reports of onychomycosis, sinusitis, osteomyelitis and pulmonary involvement. Pulmonary infections by *P. lilacinum* are unusual with few cases reported in the literature in both immunocompromised and immunocompetent hosts. The most frequent clinical manifestations are malaise, fever, cough, pleuritic pain and dyspnea. There are a variety of radiographic presentations reported in the literature including lung nodules, cavitary pulmonary disease, pleural effusion, lung abscess, solitary pulmonary lesion and lung consolidation [5,6]. However, there are no reported cases of bilateral lung consolidation.

At the moment of writing this paper (written in English) 9 cases have been reported in the literature describing pulmonary infections secondary to *P. lilacinum*: they are described in Table 1, with the respective thorax CT scan findings and the diagnosis methods [6-14]; all cases described in Table 1 show the pulmonary infection with morphologic criteria and positive cultures (sputum, BAL and biopsy): Only Khan *et al.* [6] and our case confirmed the diagnosis using the criteria previously explained and adding genotypic identification (GenBank) to give additional information about the causative pathogen.

The mean age of presentation in patients with pulmonary infection due to *P. lilacinum* was 48 years old (20-80 years old), with a predominance of the male gender (60%), the most frequent predisposing factor was hematologic malignancies (50%), the most frequent clinical presentation was fever (40%), there were a variety of radiographic presentations; unilateral lung consolidation (20%), cavitary pulmonary disease (20%) and nodules on the thorax CT scan (20%) were the most reported signs, while the most frequent outcome was a recovery from the pulmonary infection (60%) with voriconazole and posaconazole as primary therapy.

Diagnosis of *P. lilacinum* can be challenging because of the similarity on morphology when compared with *Aspergillus* and other agents of hyalohyphomycosis; thus, several diagnostic tools are available to aid in the correct identification of this pathogenic mold, *P. lilacinum* grows rapidly on Sabouraud glucose agar, giving rise to a white colony and gradually becomes lilac or vinaceous in color; additionally, at microscope the mold can be characterized by septate, branching hyaline hyphae with phialides tapering at its distal end [2,15]. Using

genotypic identifications alongside cultures can boost the identification of fungal pathogens, the internal transcribed spacers (ITS1 and ITS2) regions of the ribosomal RNA gene cluster are molecular markers that help in the estimation of phylogenetic relationship between species: it is a well-defined barcode that has the highest probability of successful identification for the broadest range of fungi, not just *P. lilacinum*, making it a great diagnosis test [16,17].

Systemic treatment is important in patients with pulmonary involvement, *P. lilacinum* has been reported to show reduced susceptibility to AMB, echinocandins and itraconazole, but it showed good susceptibility against voriconazole and posaconazole. There are reports that voriconazole has been used to treat *P. lilacinum* successfully in a wide variety of clinical presentations (including pulmonary involvement) thus being first-choice treatment [18]. In our case, the initiation of voriconazole was accompanied by a fast recovery of symptoms.

No information about the use of primary prophylaxis was found in the cases of *P. lilacinum* with pulmonary involvement described in Table 1, except for the case of Mullane K. *et al.* [11] that used fluconazole in a patient with multiple myeloma disorder that underwent an autologous hematopoietic stem cell transplant. In our case we can hypothesize the presentation of this breakthrough fungal infection is due to multiple reasons. In Mexico itraconazole is exclusively available as capsules which has reduced bioavailability, measurement of serum level concentrations is not obtainable so we were unable to know if therapeutic concentrations were reached and finally the activity of itraconazole against this fungal pathogen is limited [18], all of which could have contributed to acquiring the infection in this patient.

In our review of the literature and to the best of our knowledge, we described a new radiographic presentation in a patient infected by *P. lilacinum* and we indicated in the largest list of patients with pulmonary *P. lilacinum* infection the general characteristics of these patients in hope of helping our colleagues to promptly identify and treat this infection. The relevance of this case is to remark the challenge of *P. lilacinum* as a cause of pulmonary infection due to the similarities on the clinical and radiographic presentations with other opportunistic and more common infections such as *Candida* and *Aspergillus*, because of the different effectiveness of antifungal therapies, thus remarking the importance of prompt identification of the pathogenic agent to initiate the most effective therapy.

References

1. CLSI. Reference Method for Broth Dilution Antifungal Susceptibility of Filamentous Fungi. 3rd ed. CLSI standard M38. Wayne, PA: Clinical and Laboratory Standards Institute; 2017.
2. Chen, WC, Lin SR, Hung SJ (2019). Successful Treatment of Recurrent Cutaneous *Purpureocillium lilacinum* (*Paecilomyces lilacinus*) Infection with Posaconazole and Surgical Debridement. *Acta Derm Venereol* 13: 1313-1314.
3. Luangsa-ard J, Houbraken J, van Doorn T, Hong SB, Borman AM, Hywel-Jones NL, Samson RA (2011) *Purpureocillium*, a new genus for the medically important *Paecilomyces lilacinus*. *FEMS Microbiol Lett* 32: 141–149.
4. Pastor FJ, Guarro J (2006) Clinical manifestations, treatment and outcome of *Paecilomyces lilacinus* infections. *Clin Microbiol Infect* 12: 948–960.
5. Gutiérrez F, Masiá M, Ramos J, Elía M, Mellado E, Cuenca-Estrella M (2005) Pulmonary mycetoma caused by an atypical isolate of *Paecilomyces* species in an immunocompetent individual: case report and literature review of *Paecilomyces* lung infections. *Eur J Clin Microbiol & Infect Dis* 24: 607–611.
6. Khan Z, Ahmad S, Al-ghimlas F, Al-mutairi S, Joseph L, Chandy R, Sutton DA (2012) *Purpureocillium lilacinum* as a Cause of Cavitary Pulmonary Disease: a New Clinical Presentation and Observations on Atypical Morphologic Characteristics of the Isolate. *J Clin Microbiol* 50(5): 1800-4
7. Fenech FF, Mallia CP (1972) Pleural effusion caused by *Penicillium lilacinum*. *Br J Dis Chest* 66: 284-90.
8. Mormede M, Texier J, Gomez F, Couprie B, Fourche J, Martigne C (1984) Isolation of *Paecilomyces* (*P. lilacinus*) from pleural effusion. *Med Maladies Infect* 14: 76 –78.
9. Liu K, Howell DN, Perfect JR, Schell WA (1998) Morphologic criteria for the preliminary identification of *Fusarium*, *Paecilomyces*, and *Acremonium* species by histopathology. *Am J Clin Pathol* 109: 45–54.
10. Ono N, Sato K, Yokomise H, Tamura K (1999) Lung abscess caused by *Paecilomyces lilacinus*. *Respiration* 66: 85–87.
11. Mullane K, Toor AA, Kalnicky C, Rodriguez T, Klein J, Stiff P (2007) Posaconazole salvage therapy allows successful allogeneic hematopoietic stem cell transplantation in patients with refractory invasive mold infections. *Transpl Infect Dis* 9: 89–96.
12. Peghin M, Monforte V, Martin-Gomez MT, Ruiz-Camps I, Berastegui C, Saez B, Riera J, Solé J, Gavaldá J, Roman, A (2016) Epidemiology of invasive respiratory disease caused by emerging non-*Aspergillus* molds in lung transplant recipients. *Transpl Infect Dis* 18: 70–78.
13. Hobson S, Epelbaum O, Leytin A (2013) *Paecilomyces lilacinus* Pneumonia in a Neutropenic Patient—An Emerging Threat? *Chest*, 144(4) Suppl: 248A.
14. Tzaikou G, Cameron R (2019). *Purpureocillium lilacinum* infection of the lung in an immunosuppressed patient – a case report. *Pathology*, 51(S1): S102.
15. Saberhagen C, Klotz SA, Bartholomew W, Drews D, Dixon A (1997) Infection Due to *Paecilomyces lilacinus*: A Challenging Clinical Identification. *Clin Infect Dis* 25: 1411–3.
16. Schoch CL, Seifert KA, Huhndorf S, Robert V, Spouge JL, Levesque CA, Chen W (2012). Nuclear ribosomal internal transcribed spacer (ITS) region as a universal DNA barcode marker for Fungi. *Proc Natl Acad U S A* 109: 6241–6246.
17. Edger PP, Tang M, Bird KA, Mayfield DR, Conant G, Mummenhoff K, Koch MA, Pires JC (2014) Secondary structure analyses of the nuclear rRNA internal transcribed spacers and assessment of its phylogenetic utility across the brassicaceae (mustards). *PLoS one* 9: 3–9.
18. Aguilar C, Pujol I, Sala J, Guarro J (1998) Antifungal Susceptibilities of *Paecilomyces* Species. *Antimicrob Agents Chemother* 42: 1601–1604.

Corresponding author

Dr. Jorge Rafael Violante Cumpa
 Department of Internal Medicine. Hospital Universitario Dr. José Eleuterio González, Universidad Autónoma de Nuevo León. Av. Madero and Av. Gonzalitos. s/n Colonia Mitras Centro Monterrey, N.L. México.
 Phone and Fax: + (52) 81 83333664, + 52 (811) 2556438.
 Email: jorge_violante@hotmail.com
 ORCID: 0000-0002-7403-0814

Conflict of interests: No conflict of interests is declared.