

Original Article

## Fungal osteomyelitis and soft tissue infections: Simple solutions to uncommon scenarios

Ravi Chavan<sup>1</sup>, Aditya Menon<sup>1</sup>, Rajeev Soman<sup>1</sup>, Camilla Rodrigues<sup>1</sup>, Anjali Shetty<sup>1</sup>, Ravi Bhadiyadra<sup>1</sup>, Vikas M Agashe<sup>1</sup>

<sup>1</sup> P.D. Hinduja Hospital and Medical Research Centre, Mahim, Mumbai, India

### Abstract

**Introduction:** Fungal osteoarticular/soft tissue infections (FOaSI) are an uncommon entity with protracted course due to variability in clinical picture, slow progression; resulting in misdiagnosis with empirical therapy. Recent studies have shown an alarming emergence of FOaSI in immunocompetent individuals with high mortality rates. This study recommends a protocol for managing these complex and confusing scenarios.

**Methodology:** We have retrospectively analysed patients with FOaSI between January 2014 and December 2016, with a minimum 12 months follow up.

**Results:** 8 cases (6 male, 2 female) with a mean age of 42.88 years (26-53) presented to us 45 days (3-365) after initial symptoms. They underwent mean 3 procedures before being diagnosed with a fungal infection. Deep tissue cultures grew 9 fungi and 6 bacteria, commonest fungus being *Candida* sp (n = 4), treated with appropriate antifungals and antibiotics. Infection remission was achieved in 7/8 (87.5%) cases at 27.1 months (19-45) follow-up with 1 mortality. Excellent functional results as per our criteria were seen in 5 cases (62.5%) with 1 talus excision, 1 ray amputation and 1 mortality.

**Conclusions:** This study highlights the significance of implementing a simple rule such as obtaining fungal cultures in every case of bone and soft tissue infections. Standardisation of treatment may not be the ideal solution, since different fungi have different growth patterns and invasiveness. A simple protocol of customising the medico- surgical treatment with an open ended discussion between the surgeons, microbiologists, pathologists and infectious disease specialists forms the cornerstone to success.

**Key words:** Fungal osteomyelitis; mycosis; fungal soft tissue infection; open fractures; mucormycosis; candida osteomyelitis.

*J Infect Dev Ctries* 2020; 14(9):1033-1039. doi:10.3855/jidc.11449

(Received 08 February 2020 – Accepted 18 June 2020)

Copyright © 2020 Chavan *et al.* This is an open-access article distributed under the Creative Commons Attribution License, which permits unrestricted use, distribution, and reproduction in any medium, provided the original work is properly cited.

### Introduction

Fungal osteoarticular/soft tissue infections (FOaSI) are an uncommon entity with protracted course due to variability in clinical picture, slow progression, rarity; resulting in misdiagnosis with empirical therapy [1]. Normally, fungal infections follow an indolent, protracted course lasting over months to years; however, recent studies have shown an alarming emergence of FOaSI in immunocompetent individuals with high mortality rates [2–6]. Till date, there is no consensus on the diagnostic and management protocol. There are very few reports in English literature analysing the characteristics of FOaSI and their outcomes; our retrospective analysis attempts to recommend a protocol for managing these complex and often confusing scenarios.

### Methodology

We have retrospectively analysed patients with FOaSI between January 2014 and December 2016, with a minimum 12 months follow up.

Inclusion criteria were:

1. Complete records (covering clinical details, operation notes, cultures, antibiotics) in the Electronic Medical Record Department (eMRD) after presenting to our centre;
2. Clinical photographs or radiographs at presentation and on achieving infection remission;
3. Minimum follow up of 12 months after the discontinuation of antifungals;
4. Lost to follow up before follow up period of 12 months (considered treatment failure).

Exclusion criteria were:

1. Unavailability of above mentioned records. All the patients were treated by a single

orthopaedic surgeon. A team comprising of infectious disease specialist (ID), microbiologist, histopathologist, plastic surgeon and other specialists as needed helped in managing these patients at a tertiary referral centre with intensive care facilities (ICU).

The protocol included:

1. Detailed history - mode of injury, probable site and extent of contamination in open fractures, treatment received, fixation details, whether external fixation was done, antibiotics/antifungals received, factors responsible for immunocompromised state if any;
2. Good clinical examination- assess scars of the primary injury, scar/scars of osteosynthesis, sinuses, signs of infection, deformities, abnormal mobility;
3. Analyzing photographs and imaging studies of the primary injury whenever available- to locate the possible site/ extent of soft tissue injury in an open fracture, which would give an indication of the primary site of contamination;
4. Relevant imaging and hematological studies;
5. Preoperative referral to the Infectious Disease (ID) specialist who would study the circumstances around the primary injury, index surgery and current picture and then recommend appropriate microbiological tests for the intra operative tissue samples and empirical antibiotics till availability of reports;
6. Avoiding negative cultures- In cases where the general condition of the patient permitted, antibiotic free interval of at least three weeks prior to debridement was preferable. Administering antibiotics for surgical site prophylaxis only after deep tissue cultures were obtained;
7. Debridement beyond the infection (*Oncosurgical debridement*)- It comprised of incision with a margin of clean non- infected tissue, excision of the previous surgical scar, all sinuses and drain sites with intervening skin with the intention of enbloc resection of infected soft tissues; going deep up to the bone and implant maintaining a clean margin all around. Removal of all macroscopic infected tissue, exploration of the site of open injury, implant removal where indicated, removal of biofilm present on the surface and undersurface of the plate and within screw holes, fracture site and medullary canal, reaming of medullary canal in selected cases, excision of necrotic bone till pin point bleeding edges finally leaving a bed of macroscopically clean, healthy tissue and bone;
8. Biopsy- Procuring at least 5 to 6 deep tissue sample for gram staining, culture (aerobic, anaerobic, fungal, tuberculous) and histopathology either by open surgical or image guided biopsy;
9. Suitable stabilization, if necessary;
10. Early soft tissue cover either with primary closure over a drain if possible or later by the plastic and reconstructive surgeon with skin grafts or flaps, as necessary;
11. Antibiotic administration- Empirical (before culture reports) and targeted antibiotics after final antibiotic susceptibility pattern selected by the ID specialist in collaboration with the microbiologist and histopathologist;
12. Negative pressure wound therapy (NPWT) and appropriate local antibiotics were used when indicated for source control in severe infections.

Infection remission was defined as no clinical and radiological signs and symptoms of persistent infection, with normal haematological workup at 12 months follow up after stopping medication. The outcomes were graded based on the last follow up.

Excellent results were defined as a combination of:

1. Remission of infection for a minimum 12 months after the discontinuation of antibiotics/antifungals;
2. No local relapse or distant spread by the same organism at any stage during the follow up and;
3. Radiological union at fracture site (where applicable).

Failure was defined as any one of the following:

1. Persistence or recurrence of infection at the primary site;
2. Amputation/excision in unsalvageable cases;
3. Distant focus of infection by the same organism;
4. Non- union;
5. Patients lost to follow up within 12 months from the last surgery, irrespective of the wound status;
6. Mortality attributed directly or indirectly to the infection.

## Results

Eight cases (six male, two female) with a mean age of 42.88 years (26 - 53) were managed during the study period and fulfilled the inclusion criteria. The patient

demography, aetiology and clinical presentation were as described in Table 1. Patients presented to us at a median 45 days (3 - 365) after initial symptoms. 6/8 had osteoarticular involvement, while two had soft tissue infections. They underwent a mean of three procedures before being diagnosed with a fungal infection. Four were being treated for bacterial infections prior to being diagnosed with a fungal infection. One patient was being treated for infection with *Actinomyces* based on a histopathology report. Following presentation to our institute, 7/8 cases underwent radical debridement to obtain deep tissue cultures, while the 8<sup>th</sup> case with rib osteomyelitis underwent ultrasound (USG) guided aspiration. We adhered to the protocol of sending tissues for bacterial, tubercular, fungal cultures and histopathology in all cases. A total of 15 organisms were isolated (9 fungi and 6 bacteria) with mixed bacterial and fungal infections in 3 (Table 1). The commonest fungi was *Candida* sp (n=4), while the commonest bacteria was *Pseudomonas aeruginosa* (n=3). Antifungals were administered for a mean 2.8 months as prescribed by the ID specialist (Table 1). Appropriate antibiotics were given for those with a mixed infection for 6 weeks. Infection remission was achieved in 7/8 (87.5%) cases at a mean follow up of 27.1 months (19 - 45) with one mortality secondary to septicaemia during the course of hospitalisation. Excellent results as per our criteria were seen in 5 cases (62.5%). There were three failures, the first was a 60

Figure 1. Gangrenous changed bilateral feet.

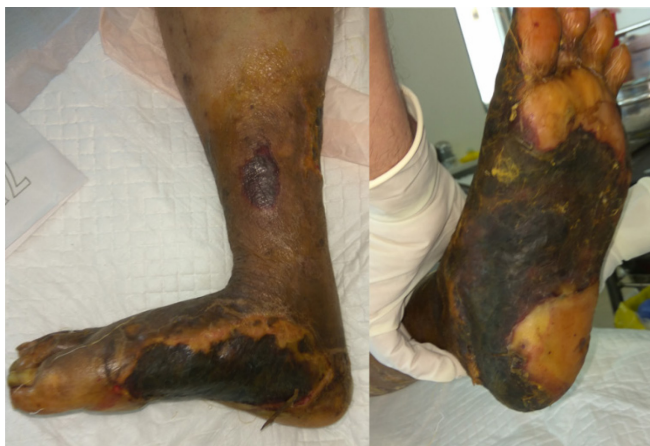

Figure 2. Bilateral lower limb debridement.

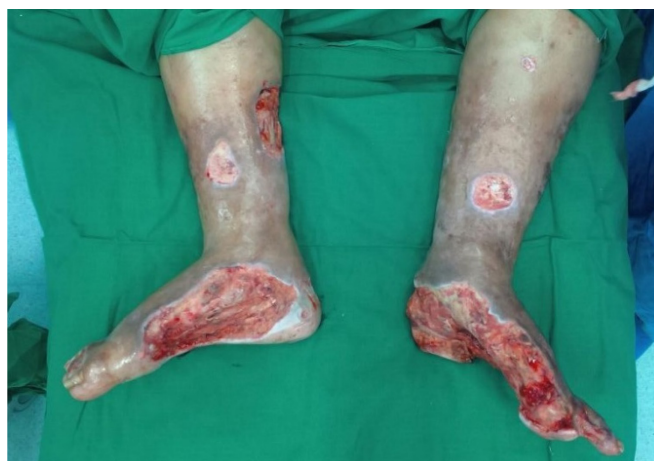
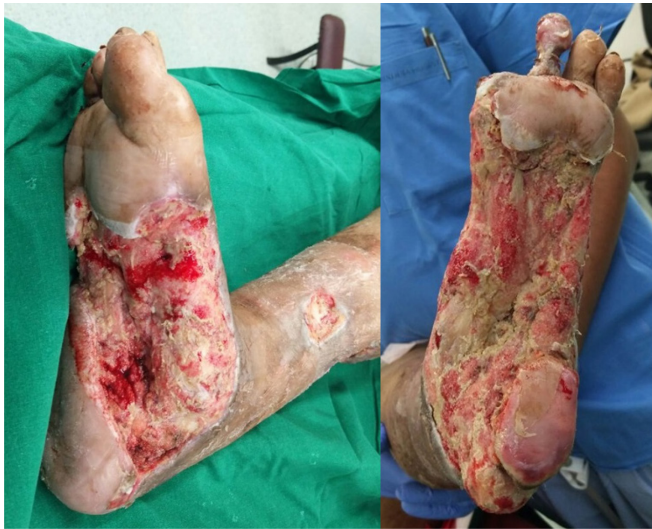
Table 1. Patient demography, aetiology, clinical presentation, Culture results and Antifungal therapy details.

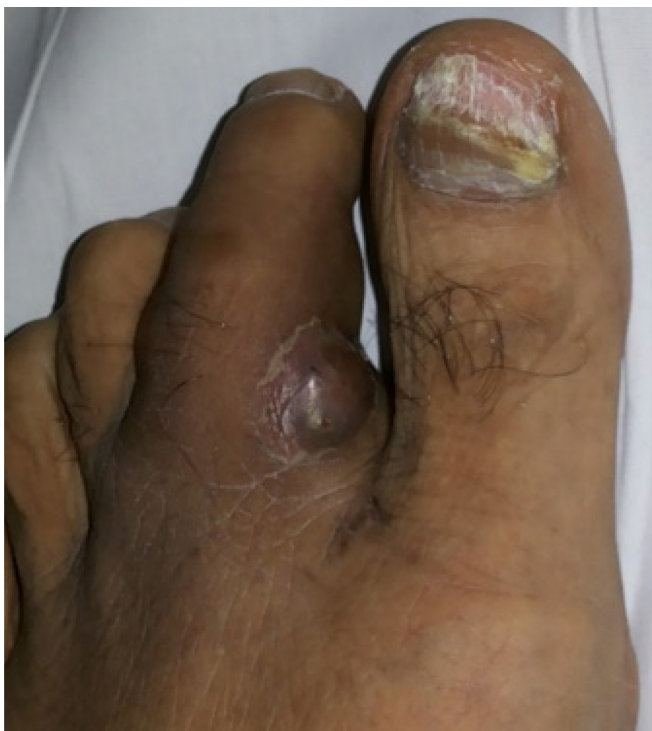Age/ Gender	Clinical presentation	Diagnosis	Co-morbidities	Immunocompromising factors	Culture Results	Antifungal	Duration (months)
1 26/M	Wound over dorsolateral aspect of foot with extruded talus	Open fracture talus	None	None	<i>Curvularia lunata</i> , <i>Pseudomonas aeruginosa</i> , <i>Acinetobacter baumannii</i>	Voriconazole	4
2 51/M	Severe pain, swelling over right costal margin	Osteomyelitis ribs	None	None	<i>Aspergillus flavus</i>	Voriconazole	4
3 40/M	Pain, swelling over left costal margin	Osteomyelitis ribs	None	None	<i>Aspergillus flavus</i>	Voriconazole	3
4 38/F	Multiple non healing ulcers over both legs	Non healing ulcers	Systemic lupus erythematosus	None	<i>Candida pasapsilosis</i>	Fluconazole	3
5 35/M	Sinus over right leg with foul smelling discharge and soft tissue loss	Infected non-union right tibia diaphysis	None	None	<i>Candida haemoloni</i>	Anidulafungin	1
6 40/M	Wound over right proximal thigh medial aspect and inguinal region with foul smelling discharge	Open fracture femur	None	None	<i>Candida albicans</i> , <i>Pseudomonas aeruginosa</i>	Fluconazole	1
7 53/M	Pain and swelling base of second toe	Osteomyelitis right second toe	None	Renal transplant, immunosuppressive therapy	<i>Alternaria alternate</i>	Voriconazole	6
8 60/F	Non healing ulcers bilateral foot and leg with gangrenous changes	Bilateral wet gangrene	Diabetes mellitus, peripheral vascular disease	None	<i>Candida albicans</i> , <i>Mucormycosis</i> , <i>Pseudomonas aeruginosa</i>	Andiulafungin, Posiconazole	15 days

**Figure 3.** Recurrence of soft tissue necrosis.

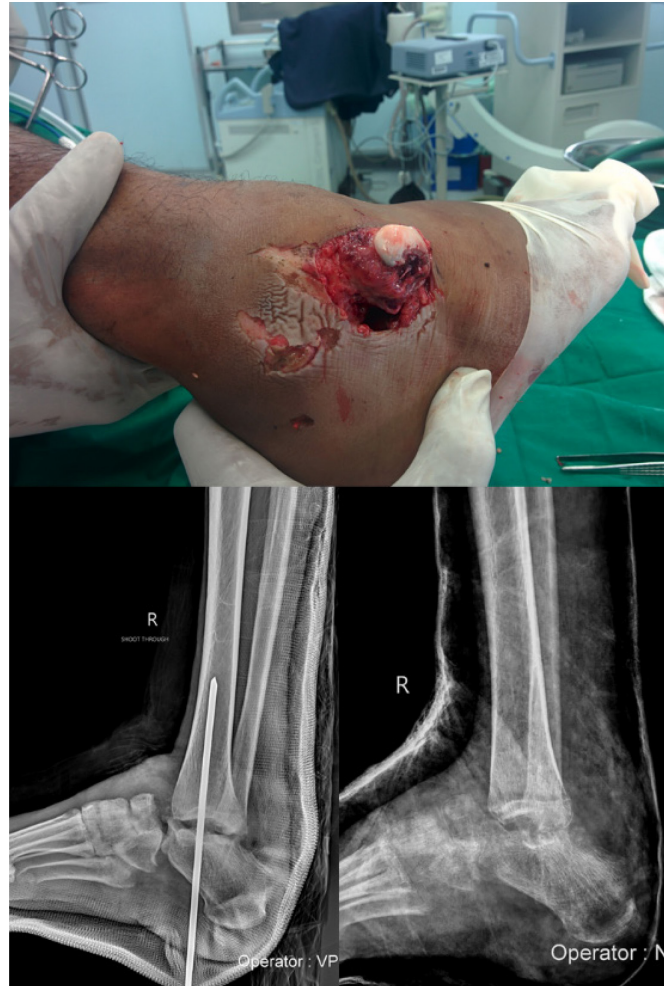

year old known diabetic with peripheral vasculopathy. She presented with bilateral lower limb diabetic gangrene (Figure 1) and was managed with debridement and negative pressure wound therapy (Figure 2). The tissue cultures grew *pseudomonas aeruginosa* and was treated with appropriate antibiotics. The patient and relatives refused the surgical recommendation of bilateral below knee amputation which was advised taking into account the poor wound status, decreased vascularity. The wound

**Figure 5.** Nodule over base of 2nd toe.



**Figure 4.** Talus excised and ankle temporarily stabilised with K Wire.



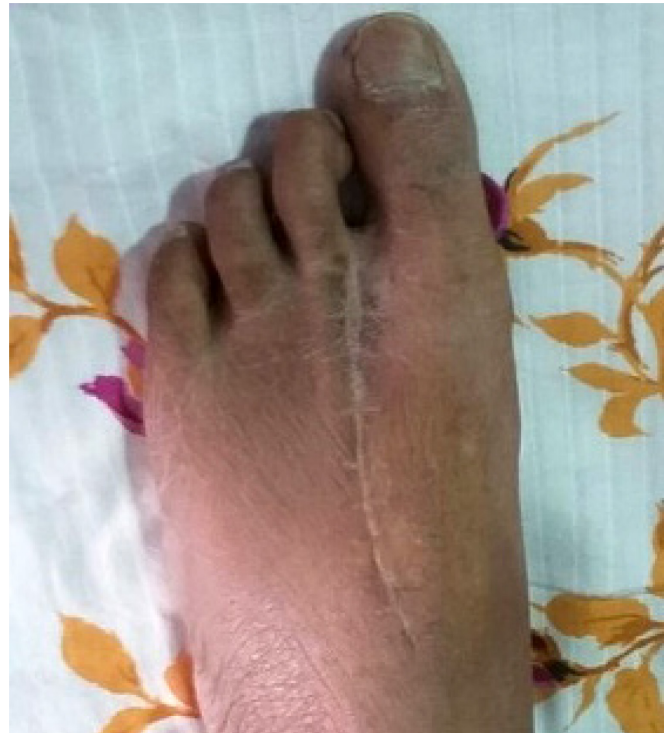condition deteriorated 15 days after the primary debridement and cultures subsequently grew *Candida albicans* and *Mucor* (Figure 3). She was started on Anidulafungin and Posaconazole by the ID specialist. Subsequent bilateral below knee amputation was done considering the invasiveness of *Mucor* infection and the mortality associated with it. However, the patient died due to septic shock secondary to gangrenous diabetic foot. The second patient had a talus excision (Figure 4). The third patient was a 53-year-old male who presented with complaints of recurrent swelling and mild pain over the base of second toe of left foot since 1 year (Figure 5). There was no history of recurrent fever, injury, thorn prick or discharging sinus. Patient had undergone renal transplant 4 years ago and was on immunosuppressive therapy. Excision biopsy done elsewhere was indicative of *Actinomycotic* infection on histopathology. Tissue cultures were negative. He had a recurrence in spite of 3 months of doxycycline and

presented to our institute at this stage. On exploration; a blackish, soft, irregular shaped mass partly adherent to skin extending in to dorsal surface through 1<sup>st</sup> web was excised. Histopathology showed several colonies of pigmented fungus in dermal and subcutaneous tissue with dense granulomatous inflammation and necrosis surrounding these colonies. The cultures grew *Alternaria alternata*, a saprophytic pigmented fungus (Figure 6). He had a locally recurrent nodule 7 months following debridement in spite of 6 months of Voriconazole therapy. The nodule was excised and Voriconazole continued. The nodule recurred locally 4 months later. Considering the immunosuppressive state and a slow growing fungal infection with a possibility of metastasis; 2<sup>nd</sup> ray amputation was done to prevent further recurrence. Voriconazole was continued for a further 6 months. There was no local or distant recurrence 36 months after the ray amputation (Figure 7).

**Discussion**

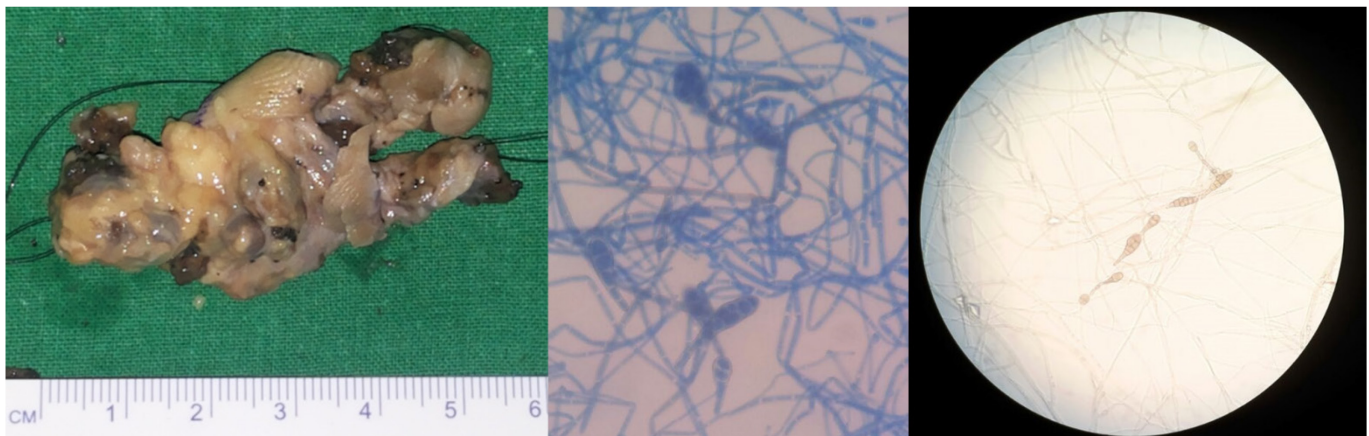
Fungi rarely affect the musculoskeletal system, and have been notorious in causing chronic, low grade, persistent infections [5,6]. Delay in diagnosis can have effects ranging from contiguous spread of infection to haematogenous seeding with high mortality rates, more so in immunocompromised patients [2,7–9]. There have been increasing reports of fungal osteomyelitis in immunocompetent patients, which can be haematogenous or due to direct inoculation [1,6,10]. All except one patient were immunocompetent in our study. The outcome of bone infections primarily depends on aggressive surgical debridement and procuring representative deep tissue samples. This, however, does not seem to hold true for all cases of FOaSI. Literature shows studies with variable results in spite of adequate debridement; the reasons can be manifold- negative

**Figure 7.** Healed 2nd ray amputation with no local recurrence.



culture, inconclusive histopathology, microscopic invasion of fungi in the tissues and vasculature beyond what seems to be macroscopically normal tissue, poor bone penetration of antifungals and immunocompromised state amongst others [2–5,7,10–13]. This variability in results is distinctly highlighted in our case who underwent a second ray amputation following local recurrence [14]. This case highlights the need for a prolonged follow- up of patients with fungal infections due to the propensity for recurrences. Institutes all over the world are battling to setup a systematic protocol to ensure early detection and good outcomes. However, there is yet no consensus on the

**Figure 6.** Gross Image of Lesion and Microscopic images of *Alternaria alternata*.



duration of therapy or the need for adjuvant surgery. A recent prospective observational study on *Candida* osteomyelitis published by Neofytos *et al.*, had multiple cases with sequential change in the antifungal drug and observed shorter duration of antifungal therapy (AFT) in those undergoing a surgical intervention [11]. None of the patients were on AFT for more than 90 days for various reasons. Thus, there was a lack of consensus on the duration of AFT and no guidelines were laid down at the end of the study. Our study highlights the same, with AFT duration ranging from 30 to 180 days, with treatment being individualised on a case to case basis. Contrary to the finding by Neofytos *et al.*, where they found shorter durations in those undergoing surgery; Dietl *et al.*, questioned the basis of surgical debridement in *Candida* osteomyelitis of the sternum following cardiac surgery [7]. They reported worse outcomes in those subjected to debridement followed by a flap with local recurrence in all. They have proposed long term AFT as the first line of management and not radical surgical debridement. 7/8 of our cases were subjected to radical debridement. 6/7 had either an open wound with discharging sinus or non-healing ulcers which warranted surgical debridement. The seventh case had excruciating pain over the costal margin with rib osteomyelitis and soft tissue abscess on MRI, for which he was explored. The only patient who did not undergo debridement had pain over the left costal margin with osteomyelitis of the ribs. There was a history of injury with a piece of wood 2 years prior and patient was clinically stable. An ultrasound guided biopsy was done with a strong suspicion of FOaSI. Tissue cultures grew *Aspergillus flavus*. He responded favourably to 3 months of Voriconazole and had an infection free follow up of 22 months. It has been postulated that FOaSI can arise from three primary routes, namely-hematogenous seeding, direct inoculation and contiguous spread of infection [6]. 4 cases in our series probably had direct inoculation (3 open injuries, 1 penetrating injury with a piece of wood), while the other 4 most likely had a hematogenous infection (1 immunocompromised, 3 immunocompetent). Delay in diagnosis and aggressive management is known to be associated with high mortality rates as seen in one of our cases [2]. Mortality rate in non-disseminated mucormycosis can be as high as 33% as described in a recent case report where the patient had to undergo a hip disarticulation following an open fracture of the tibia [15]. Our study is limited by its retrospective nature, varied etiopathogenesis and diverse treatment strategies.

## Conclusions

In spite of the limitations mentioned, this study clearly highlights the significance of implementing a simple rule such as obtaining fungal cultures in every case of bone and soft tissue infections, since we are seeing increasing rates of FOaSI in immunocompetent individuals when least suspected. Moreover, fungal infections must be suspected in cases of open injuries with soil contamination, prolonged hospitalisation, farmyard injuries and penetrating injuries with vegetation like a thorn prick. Standardisation of treatment may not be the ideal solution, since different fungi have different growth patterns and invasiveness, ranging from relatively benign slow growing fungi to invasive mucormycosis and aspergillosis. A simple protocol of customising the medico-surgical treatment with an open ended discussion between the surgeons, microbiologists, pathologists and infectious disease specialists forms the cornerstone to success as seen in our series.

## References

- Menon A, Rodrigues C, Soman R, Sunavala A, Agashe VM (2017) Aspergillus Osteomyelitis of the Ribs in Immunocompetent Hosts: Report of Two Rare Cases. J Orthop case reports 7: 61–64.
- McNeil MM, Nash SL, Hajjeh RA, Phelan MA, Conn LA, Plikaytis BD, Warnock DW (2001) Trends in Mortality Due to Invasive Mycotic Diseases in the United States, 1980–1997. Clin Infect Dis 33: 641–647.
- Koehler P, Tacke D, Cornely OA (2014) Aspergillosis of bones and joints - a review from 2002 until today. Mycoses 57: 323–335.
- Gabrielli E, Fothergill AW, Brescini L, Sutton DA, Marchionni E, Orsetti E, Staffolani S, Castelli P, Gesuita R, Barchiesi F (2014) Osteomyelitis caused by Aspergillus species: A review of 310 reported cases. Clin Microbiol Infect 20: 559–565.
- Sealy PI (2015) Fungal Osteomyelitis. Eur Int J Sci Technol 4: 17–22.
- Bariteau JT, Waryasz GR, McDonnell M, Fischer SA, Hayda CRA, Born CT (2014) Fungal Osteomyelitis and Septic Arthritis. J Am Acad Orthop Surg 22: 390–401.
- Dietl M, Schwabegger A, Grimm M, Ruttman E, Kompatscher P (2017) First line treatment of Candida osteomyelitis of the sternum: Is there really a need for radical surgical debridement and reconstructive surgery in Candida osteomyelitis of the sternum after cardiac surgery? J Plast Reconstr Aesthetic Surg 70: 291–292.
- Tack KJ, Rhame FS, Brown B, Thompson RC (1982) Aspergillus osteomyelitis. Am J Med 73: 295–300.
- Dotis J, Roilides E (2011) Osteomyelitis due to Aspergillus species in chronic granulomatous disease: An update of the literature. Mycoses 54: 686–696.
- Collignon P (1987) Candida osteomyelitis. Am J Med 83: 1173.
- Neofytos D, Huprikar S, Reboli A, Schuster M, Azie N, Franks B, Horn D (2014) Treatment and outcomes of Candida

- osteomyelitis: Review of 53 cases from the PATH Alliance® registry. *Eur J Clin Microbiol Infect Dis* 33: 135–141.
12. Wu M, Huang T, Li Y, Huang T (2015) Treatment outcomes of fungal vertebral osteomyelitis: A case series study and literature review. *Formos J* 6: 89-97
  13. Arias F, Mata-Essayag S, Landaeta ME, De Capriles CH, Pérez C, Nunez MJ, Carvajal A, Silva M (2004) *Candida albicans* osteomyelitis: Case report and literature review. *Int J Infect Dis* 8: 307–314.
  14. Shrinivas Jakkam M, Agashe VM, Soman R, Almeda A (2015) Subcutaneous Foot Phaeoophomycosis due to *Alternaria alternata* The *J. of Foot and Ankle Surg. (Asia- Pacific)* 2: 44-46
  15. Farraye MA, Jodie Magyari PA, Michael Weaver PJ, von Keudell AG (2018) Mucormycosis Of The Lower Extremity In

The Orthopaedic Trauma Setting. *JBJS J. of Orthop for Physician Assistants* 6: p e37.

### Corresponding author

Aditya Menon  
P.D. Hinduja Hospital and Medical Research Centre  
SVS Rd, Mahim West, Shivaji Park,  
Mumbai, Maharashtra 400016, India  
Tel:  
Fax:  
Email: docmenon83@gmail.com

**Conflict of interests:** No conflict of interests is declared.