

Case Report

A French case of porocephalosis diagnosed by radiologists

François Lersy¹, Thibault Willaume¹

¹ Department of neuroradiology, University hospitals of Strasbourg, Strasbourg, France

Abstract

Porocephalosis is the name given to human infection by *Armillifer*, which is rare, especially in European and North American populations. Among the few cases reported to date, most of them were described in the African community. Humans can become infected, for example, consuming undercooked meat from infected snakes. Herein we report the case of a 31-year-old male, originally from the Democratic Republic of the Congo, who was living in France for many years and presented with lower back pain and mild abdominal pain. Imaging showed multiple comma-shaped calcifications disseminated in the liver and the peritoneal cavity, without any additional feature. The patient reported regular consumption of snake meat during his travels in Africa, and thus the diagnosis of porocephalosis could be made. Doctors treating patients from endemic areas or traveling in endemic areas, particularly in Africa, should become familiar with this infection and consider it in the case of multiple calcifications on imaging. More cases of porocephalosis are likely to be seen in the future because of the increase in international travel.

Key words: Porocephalosis ; *Armillifer*; calcifications; snake.

J Infect Dev Ctries 2020; 14(9):1071-1073. doi:10.3855/jidc.12693

(Received 23 March 2020 – Accepted 22 June 2020)

Copyright © 2020 Lersy *et al.* This is an open-access article distributed under the Creative Commons Attribution License, which permits unrestricted use, distribution, and reproduction in any medium, provided the original work is properly cited.

Introduction

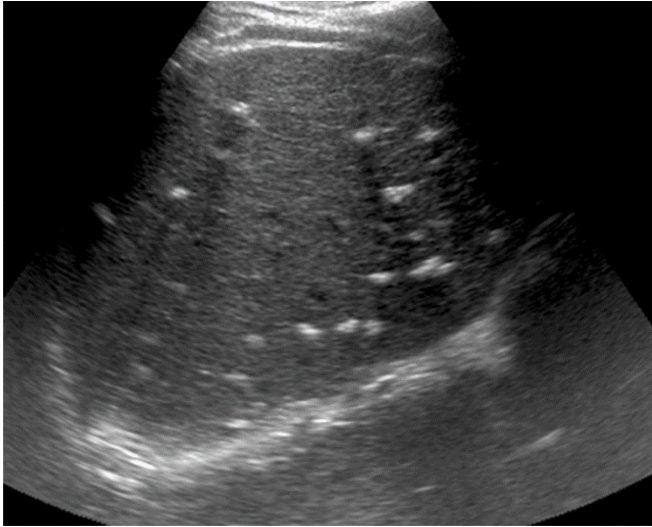
Armillifer, and especially *Armillifer armillatus*, is a genus of parasites belonging to the Pentastomida subclass, endemic in West and Central Africa [1]. The Pentastomida are a group of vermiform endoparasites [2]. *Porocephalosis* is the name given to human infection by *Armillifer*, which is rare, especially in Europe and North America. Most cases of porocephalosis have been described in African populations. The definitive hosts of *Armillifer* are snakes (pythons, vipers, etc.), and adult parasites of *Armillifer* are located in the respiratory system of snakes. Infective ova are excreted in the snake feces or respiratory secretions, contaminating vegetation and water, leading to ingestion by the intermediate hosts (small mammals, especially rodents). Snakes contaminate themselves by eating infected small mammals above mentioned. Humans can become accidental intermediate hosts and acquire the infection by drinking water or eating plants soiled by infective ova or by consuming undercooked meat from infected snakes. Snake meat is described as lean, white, and palatable [3]. Once ingested, the parasite eggs release larvae that will cross the intestinal wall to reach different organs where they encyst (peritoneal cavity, liver, pleura, pericardium, lower respiratory tract,

gastrointestinal tract, spleen, eye). The eye is the site of potentially the most severe infection, leading to blindness, with the presence of the parasite within the eyeball or in the ocular adnexa [4]. With time, the larvae will die and become calcified.

Case report

Here we report the case of a 31-year-old male, originally from the Democratic Republic of the Congo, who was living in eastern France, close to the German border, for many years. He consulted his general practitioner for lower back pain and mild abdominal pain progressing for three days. The patient's medical history was not significant, and the clinical examination provided no further clue as to the diagnosis. The physician ordered laboratory tests, an x-ray of the lumbar spine, and an abdominal ultrasound. Blood analysis showed no significant abnormalities, in particular the hemogram, which indicated a normal eosinophil count. Liver and kidney function tests yielded normal results, and no biological inflammatory syndrome was noted. The abdominal ultrasound depicted numerous liver calcifications (Figure 1). They were confirmed on plain radiographs of the lumbar spine, along with multiple other calcifications in the peritoneal cavity (Figure 2). Subsequently,

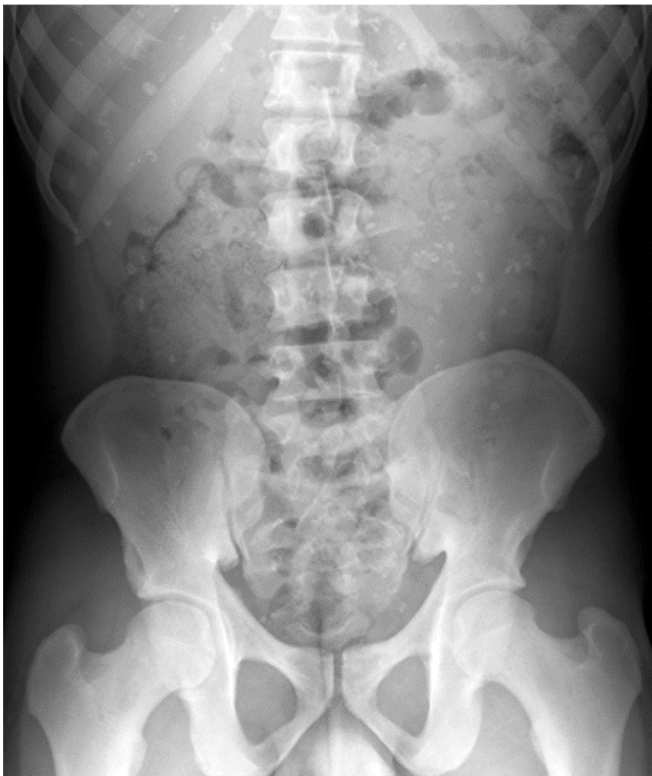Figure 1. Hepatic ultrasound showing multiple disseminated calcifications.



abdominopelvic computed tomography was performed confirming multiple comma-shaped calcifications disseminated in the liver and the peritoneal cavity, without any additional features (Figures 3 and 4).

At this stage, based on the radiological findings, the hypothesis of infectious lesions was made but without a precise diagnosis. The solution came from a

Figure 2. Plain radiograph of the lumbar spine showing calcifications in the projection of the liver and in the peritoneal cavity.



radiologist who was a native of West Africa and doing an internship in our department. When inspecting the images, she asserted, without any doubt, «This patient eats snakes!». When the patient was asked about this, he confirmed that he went on regular trips to Africa, where he would usually consume snake meat.

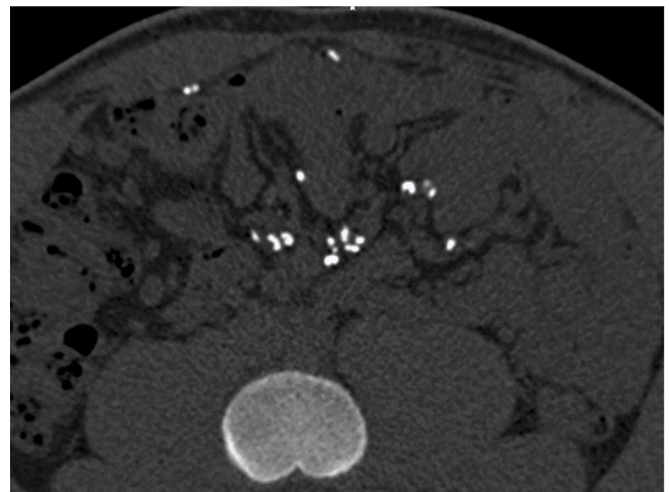
Consequently, the diagnosis of porocephalosis was made. The following are some arguments in favor of the diagnosis in this case:

- the patient originated from a country where *Armillifer* is endemic;
- there was regular consumption of snake meat;
- the clinicobiological features were consistent with the diagnosis;

Figure 3. Unenhanced CT scan showing multiple liver calcifications.

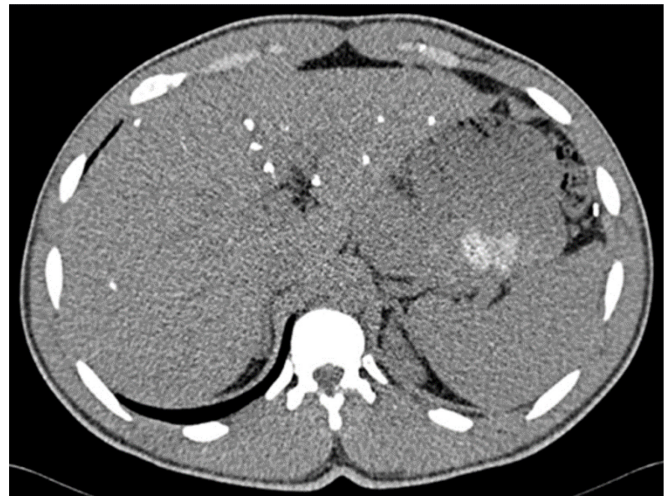

Figure 4. Unenhanced CT scan demonstrating multiple «comma-shaped» calcifications located in the peritoneal cavity.



- comma-shaped calcifications were seen disseminated in the liver and the peritoneal cavity, which are the two main sites of infection.

Owing to the spontaneous regression of symptoms and the likely incidental discovery of porocephalosis, no specific treatment was started.

Discussion

For both radiologists and clinicians, sparse liver calcifications are frequently considered as nonspecific [5]. However, sometimes, liver calcifications can result from pathological conditions, especially infectious causes. In Europe, the most common etiologies are echinococcosis and hydatid cyst, which are associated with calcified liver masses. Other infections can develop multiple small disseminated liver calcifications: tuberculosis, histoplasmosis, pneumocystosis, brucellosis, schistosomiasis, or, as in our case, porocephalosis. During porocephalosis, the two main sites of infection are the peritoneal cavity and the liver. The majority of patients originate from Africa and eat snakes [6]. Most of the patients are asymptomatic, but in the case of symptoms, mild abdominal pains are the commonest complaint. Nevertheless, symptomatic patients can develop a wide range of symptoms: acute abdominal pain secondary to compression by parasites (occlusion), cough, sepsis, neurologic symptoms, and loss of vision. Because infection with *Armillifer* parasites is usually asymptomatic, the incidence of this pathology is probably underestimated. The diagnosis can be made by detection of numerous larvae during surgery or by the identification of multiple comma-shaped calcified lesions corresponding to calcified dead larvae (nymphs are viable for approximately two years in the human body [4]) mainly localized in the peritoneal cavity or liver on imaging [2]. The calcifications can be demonstrated better on abdominal ultrasound and computed tomography. If the diagnosis is suspected, the patients must be asked about the consumption of snake meat, which will be highly suggestive of this infection. An increase in eosinophils is not a systematic finding, and there is no specific blood test for this condition. The diagnosis is confirmed by parasitological analysis.

In the case of a diagnosis made during surgery for another reason, the removal of the nymph should be considered. There are no guidelines or consensus regarding the optimal medical treatment of these patients. In particular, the increase in eosinophils or the absence of calcifications (live nymphs) cannot be used to guide treatment. The effectiveness of anti-helminthic

medications is not proven, and moreover, they may lead to hypersensitivity reactions and paradoxical worsening of the symptoms [1].

Prevention is based on the mode of contamination:

- first, avoid the consumption of snake meat, especially undercooked;
- always wash hands thoroughly after handling snakes;
- do not drink water or eat plants possibly contaminated by snake secretions;
- wash plants thoroughly before preparing and eating them.

Conclusion

Doctors caring for patients from endemic areas or traveling in endemic areas, particularly in Africa, should become familiar with this infection, and consider it in the case of multiple calcifications detected on imaging. Because of the increase in international travel, more cases of porocephalosis are likely to be seen in the future, in Europe and North America.

References

1. Ioannou P, Vamvoukaki R (2019) Armillifer Infections in Humans: A Systematic Review. *Trop Med Infect Dis* 4: 80.
2. Potters I, Desaive C, Van Den Broucke S, Van Esbroeck M, Lynen L (2017) Unexpected Infection with Armillifer Parasites. *Emerg Infect Dis* 23: 2116-2118.
3. Aiyekomogbon JO, Meseko CA, Abiodun OO (2016) Armillifer armillatus infestation in Human; public health scenario of a snake parasite: a report of three cases. *Pan Afr Med J*. 25: 45.
4. Sulyok M, Rózsa L, Bodó I, Tappe D, Hardi R (2014) Ocular pentastomiasis in the Democratic Republic of the Congo. *PLoS Negl Trop Dis*. 8: e3041.
5. Ropion-Michaux H, Mathias J, Bruot O, Ganne PA, Laurent V, Régent D (2010) Liver calcifications in adults: the KUB stars are too frequently neglected in the CT era. *J Radiol* 91: 759-768. [Article in French].
6. Tappe D, Haeupler A, Schäfer H, Racz P, Cramer JP, Poppert S (2013) Armillifer armillatus pentastomiasis in African immigrant, Germany. *Emerg Infect Dis*. 19: 507-508.

Corresponding author

François Lersy, MD
 Department of neuroradiology, University hospitals of Strasbourg, Hautepierre Hospital, 1 avenue Molière, 67200 Strasbourg, France
 Phone: +33388128056
 Email: francois.lersy@hotmail.fr

Conflict of interests: No conflict of interests is declared.