

Case Report

Cytomegalovirus associated severe pneumonia in three liver transplant recipients

Adem Kose¹, Murat Yalcinsoy², Emine Turkmen Samdanci³, Bora Barut⁴, Baris Otlu⁵, Sezai Yilmaz⁴, Yasar Bayindir¹

¹ Department of Infectious Diseases and Clinical Microbiology, Faculty of Medicine, Inonu University, Malatya, Turkey

² Department of Pulmonary Diseases, Faculty of Medicine, Inonu University, Malatya, Turkey

³ Department of Pathology, Faculty of Medicine, Inonu University, Malatya, Turkey

⁴ Institute of Liver Transplantation, Faculty of Medicine, Inonu University, Malatya, Turkey

⁵ Department of Medical Microbiology, Faculty of Medicine, Inonu University, Malatya, Turkey

Abstract

Introduction: Cytomegalovirus (CMV), is the most common opportunistic infection, remains a cause of life-threatening disease and allograft rejection in liver transplant (LT) recipients. The purpose of this case series is to state that CMV may lead to severe pneumonia along with other bacteria.

Methodology: CMV pneumonia was diagnosed with the thoracic computed tomography (CT) scan findings, bronchoscopic biopsy, real time quantitative Polymerase Chain Reaction (qPCR) and clinical symptoms. For extraction of CMV DNA from the clinical sample, EZ1 Virus Mini Kit v2.0 (Qiagen, Germany) was used, and amplification was performed with CMV QS-RGQ Kit (Qiagen, Germany) on Rotor Gene Q 5 Plex HMR (Qiagen, Germany) device.

Results: All recipients had severe pneumonia, leukopenia, thrombocytopenia and at least two-fold increase in transaminases on seventh, twenty-eighth and twenty-second days after surgery, respectively. Thoracic CT scan revealed as diffuse interstitial infiltration in the lung parenchyma. Bronchoscopy, Gram-staining and culture from bronchoalveolar lavage (BAL) fluid were performed in all of them. During bronchoscopy, a bronchial biopsy was administered to two recipients. One recipient could not be performed procedure because of deep thrombocytopenia. PCR results were positive from serum and BAL fluid. Bronchial biopsy was compatible with CMV pneumonia. However, *Pseudomonas aeruginosae* was found in two cases and *Klebsiella pneumoniae* in one case BAL fluid cultures.

Conclusions: CMV pneumonia can be seen simultaneously with bacterial agents due to the indirect effects of the CMV. It should be kept in mind that CMV pneumonia may cause severe clinical courses and can be mortal.

Key words: liver transplantation; cytomegalovirus; pneumonia.

J Infect Dev Ctries 2020; 14(11):1338-1343. doi:10.3855/jidc.12536

(Received 12 February 2020 – Accepted 31 July 2020)

Copyright © 2020 Kose *et al.* This is an open-access article distributed under the Creative Commons Attribution License, which permits unrestricted use, distribution, and reproduction in any medium, provided the original work is properly cited.

Introduction

Cytomegalovirus (CMV) is the most common opportunistic viral agent following LT [1]. The incidence of active CMV infection was reported between 30-70% in LT recipients in the absence of antiviral prophylaxis, but late initiation or delaying of preemptive therapy may increase the incidence [2].

CMV often invades multiple systems, such as the respiratory system (interstitial pneumonia), gastrointestinal tract (e.g., gastroenteritis, esophagitis, colitis) and others (retinitis, encephalitis, nephritis, myocarditis and pancreatitis), while direct effects of CMV include tissue-invasive disease or CMV syndrome (fever, elevated liver function enzymes and myelosuppression in the presence of CMV infection), it

may have many indirect effects, such as graft rejection, reduced graft survival and high morbidity and mortality rates [3]. CMV pneumonia is a mortal CMV disease after LT, and the reported incidence rate is 2.5-9.2% [4]. CMV may also cause a predisposition to other opportunistic infections with immunomodulatory effects. CMV infection, directly and indirectly, increases the risk of *Pneumocystis jirovecii* pneumonia (PJP). The association between CMV infection and post-transplant PJP is biologically plausible considering the immunomodulatory effect of this viral infection [5]. Gram-negative bacilli, particularly *Pseudomonas aeruginosae*, continue to cause most early (< 1 month) infections [6]. A positive culture or nucleic acid amplification test (NAT) from BAL

specimens in the LT recipients may reflect viral shedding for the diagnosis of CMV pneumonia [7]. CMV DNA assay is the most commonly used laboratory parameter to diagnose and monitor CMV infection, but the gold standard method for diagnosis of the tissue-invasive disease is histopathological findings [8]. The standard treatment of CMV pneumonia is intravenous ganciclovir at 5 mg/Kg twice daily. Strategies to prevent CMV have significantly reduced CMV disease and decreased the “indirect effects” of the CMV infection. Two major strategies are commonly employed for the prevention of CMV infection: universal prophylaxis and preemptive therapy. Universal prophylaxis with valganciclovir at 900 mg orally is the more common approach used to prevent tissue-invasive disease, CMV syndrome and reactivation [9].

In this case study, we evaluated three cases diagnosed not only CMV pneumonia but also bacterial agents were detected in concomitant BAL fluid cultures in the first month after LT to emphasize that the mortality and morbidity may increase despite the appropriate antibacterial and antiviral therapies administered.

Cases Presentation

Case 1

A 65-year-old male patient had undergone LT in another center, underwent re-transplantation from living donor in November 2017 in our hospital. The patient and his donor were screened for active infections before LT and all results were negative. He had no comorbid diseases. Respiratory failure occurred on the seventh postoperative day. Laboratory tests simultaneously showed anemia hemoglobin (Hb): 7.6

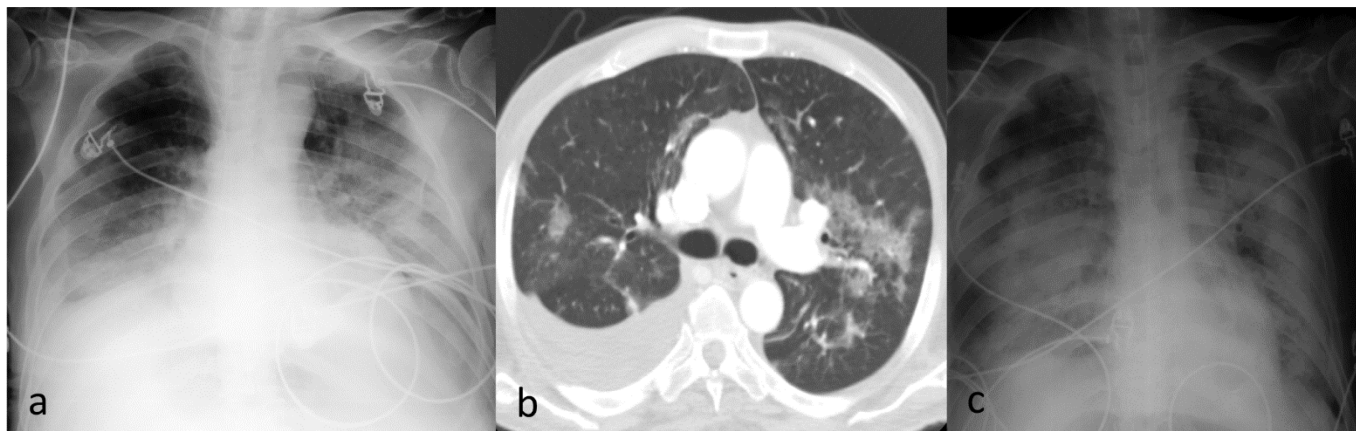
g/dL, thrombocytopenia platelets (Plt): $42 \times 10^3/\text{mL}$, elevated transaminases alanine transaminase (ALT): 66 U/L, aspartate transaminase (AST): 222 U/L, total bilirubin (T. blb): 4.18 mg/dL, direct bilirubin (D. blb): 3.3 mg/dL. In the chest X-ray, bilaterally infiltration and blunt, the sinuses were observed. Thorax CT revealed unilaterally pleural effusion and diffuse ground-glass infiltrates (Figure 1). The culture antibiogram result of the growing *P. aeruginosae* reported as ceftazidime, amikacin and colistin-sensitive. First of all, we applied for ceftazidime 1 gr three times in a day, amikacin 500 mg/day intravenous therapy. Bronchoscopy was applied because of the worsening of the general condition. There was seen a large number of leukocytes in BAL fluid Gram-staining, and culture growing was reported as *P. aeruginosae*. Fiberoptic bronchoscopic transbronchial parenchyma biopsy could not be performed because of thrombocytopenia (Plt: $42 \times 10^3/\text{L}$). Real time qPCR was used. The patient's CMV DNA PCR values were 1,214 and 50,455 copies/mL from serum and BAL fluid, respectively.

Patient's creatinine clearance was between 30-50 mL/minute due to chronic renal failure. Then, we added on ganciclovir 5 mg/Kg/day intravenous therapy for CMV pneumonia. Patient died on the 9th day of ceftazidime and amikacin therapies on the second day of ganciclovir therapy. Total intensive care unit (ICU) staying and survival duration were fifteen days.

Case 2

A 44-year-old female patient was performed LT from living donor in November 2018 in our institute. She had no comorbid disease. Antiviral prophylaxis was started as valganciclovir 900 mg/day per orally on

Figure 1. Thorax computerized tomography and portable chest X-ray images of case 1. **a.** Bilaterally infiltration and blunt the sinuses with portable chest X-ray **b.** Thorax computerized tomography (CT) show unilaterally pleural effusion and diffuse ground glass infiltration **c.** Portable chest X-ray show progression in infiltration.

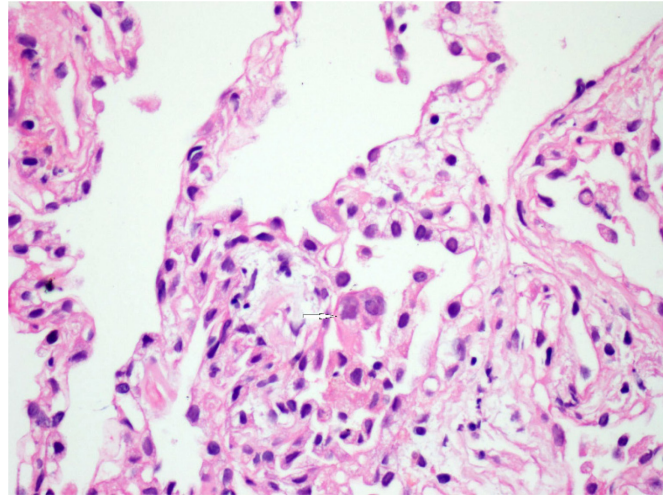


the seventh day after LT. Respiratory distress, leukopenia (white blood cells (WBC): $2.28 \times 10^9/L$), thrombocytopenia (Plt: $121 \times 10^3/mL$) and ALT: 65 U/L, AST: 67 U/L, gamma glutamyl transferase (GGT): 88 U/L were detected on the 28th day. Thoracic CT revealed diffuse patchy infiltration, air bronchogram and bilaterally pleural effusion (Figure 2). Fiberoptic bronchoscopy was applied to the patient and taken Gram-staining and culture from BAL fluid. BAL fluid Gram-staining result was reported as < 10 epithelium/lower field, 10-25 leukocytes/lower field, no bacteria were seen, culture resulted in *Klebsiella pneumoniae*. The patient's CMV DNA PCR values were 636 and 1780 copies/mL from serum and BAL fluid, respectively. Bronchoscopic biopsy was performed and was interpreted as findings consistent with CMV pneumonia (Figure 3). Patient's creatinine clearance was above 50 mL/minute. The culture antibiogram result of the growing *K. pneumoniae* reported as ceftazidime, cefepime, amikacin, piperacillin/tazobactam sensitive. We initiated piperacillin/tazobactam 4,5 g intravenous, daily four doses. Then, we added on ganciclovir 5 mg/Kg daily twice intravenous therapy for CMV pneumonia. During treatment, daily haemogram, creatinine values, and weekly serum CMV DNA PCR were studied. Clinical and radiological improvement was achieved with piperacillin/tazobactam for 14 days and ganciclovir for 28 days. CMV DNA values observed once a week during ganciclovir treatment were 893, < 100 , twice negative. No abnormalities were seen leukocyte, platelet counts, creatinine and ALT, AST values during antimicrobial treatment. At the end of the treatment, the patient was discharged when he was healthy. The

Figure 2. Thoracic CT show diffuse infiltration and air bronchogram (arrow) of case 2.

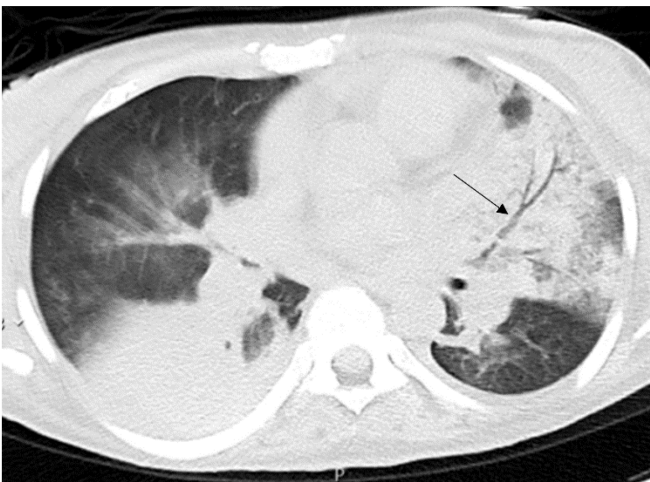

Figure 3. Viral effect compatible with CMV in pneumocytes (complete). Hematoxylin and Eosin staining $\times 400$ of case 2.

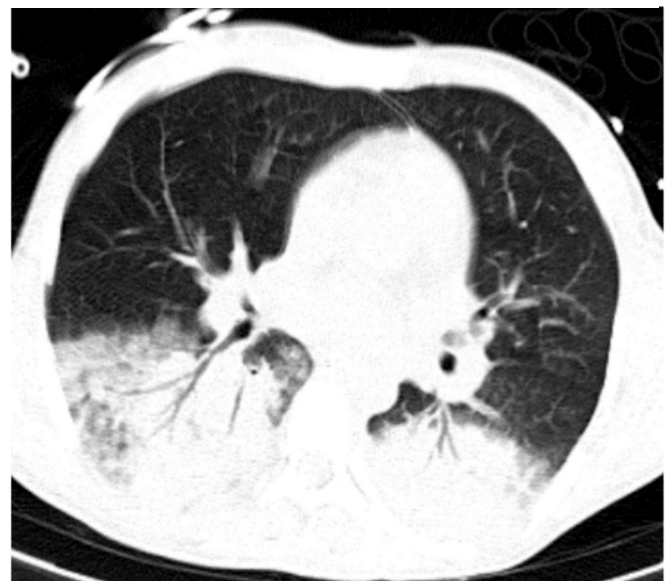

patient was followed up for 36 days in the ICU and 10 days in our department.

Case 3

A 34-year-old female patient was performed LT from living donor date in November 2018 in our hospital. She had no comorbid disease. Antiviral prophylaxis was started as valganciclovir 900 mg/day per orally on the ninth day after LT. Respiratory distress, pancytopenia (Hb: 7.4 g/dL, WBC: $2.25 \times 10^9/L$, trombocytes: $64 \times 10^3/mL$ and elevated liver function tests (ALT: 68 U/L, AST: 83 U/L, GGT: 155 U/L, T. blb: 10.2 mg/dL, D. blb: 7.11 mg/dL) were detected on the 22th day. Thoracic CT revealed infiltration involving

Figure 4. Multislice thoracic CT show infiltration involving air bronchogram in bilaterally lower lobes of case 3.

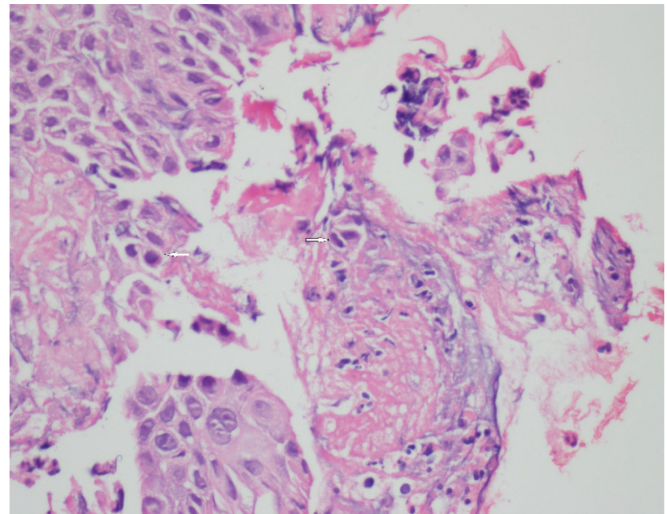


air bronchogram in bilaterally lower lobes (Figure 4). Fiberoptic bronchoscopy was applied to the patient and Gram-staining and culture from BAL fluid were taken. BAL fluid Gram-staining result was reported as < 10 epithelium, > 25 PNL/field and no bacteria seen. BAL fluid culture resulted in *P. aeruginosae*. The patient's CMV DNA PCR values were 2043 and 371 copies/mL from serum and BAL fluid, respectively. Bronchoscopic biopsy was performed and was interpreted as findings consistent with CMV pneumonia (Figure 5). Patient's creatinine clearance was above 50 mL/minute. The culture antibiogram result of the growing *P. aeruginosae* reported as ciprofloxacin, amikacin, ceftazidime, and piperacillin/tazobactam sensitive. First of all, we administered piperacillin/tazobactam 4,5 g daily four doses plus ciprofloxacin 400 mg, daily twice, intravenous therapy, then, we added on ganciclovir 5 mg/Kg, daily twice intravenous therapy for CMV pneumonia. During the treatment haemogram, creatinine and transaminase values were controlled daily. Patient died on the 12th day of piperacillin/tazobactam and ciprofloxacin therapies on the fourth day of ganciclovir therapy. Total ICU stay and survival duration were twenty-nine days.

Discussion

CMV infection occurs in the majority of LT recipients, primarily in the one to six months following LT when immunosuppressants are intensely administered [10,11]. Although LT alone is an important risk factor for the development of pneumonia, in a clinical trial conducted by Golfieri *et al.* mechanical ventilation, dose and duration of immunosuppression, pulmonary edema, encephalopathy, erythrocyte transfusion, dysfunction of acid-related respiratory muscles, re-transplantation, malnutrition and upper abdominal surgery are other risk factors [12]. In addition to all these risk factors, long-term ICU stay, recurrent and long-term intubations, and previous history of pneumonia (one case) were present in our cases. CMV-induced pulmonary lesions exhibit diffuse alveolar damage and/or interstitial inflammation. CMV pneumonia is primarily associated with CMV infection following LT and develops into acute respiratory distress syndrome (ARDS), usually leading to respiratory failure and mortality [13]. We observed unexplained fever, bicytopenia/pancytopenia, respiratory failure and clinical pneumonia in the first month after LT in the ICU follow-up. ARB, PCR and culture for tuberculosis and PJP antigen from BAL fluid were studied in all cases, but bacterial agents were grown in BAL fluid cultures. Therefore, we thought that

Figure 5. Cells with CMV effect in the necrobiotic material of the bronchial lumen (arrows). Hematoxylin and Eosin staining ×400 of case 3.



despite starting antiviral prophylaxis in two cases, there might be a coexistence of CMV pneumonia and bacterial pneumonia.

CMV DNA assay is the most commonly used laboratory test to diagnose and monitor CMV infection. Serial quantitative CMV DNA measurements can be used for infection monitoring. This usage allows monitoring of CMV infection's progression or regression, but there is no standardized threshold value that has been established for this test. High viral load values (e.g., 1000 copy/mL or above) may be predictive of the CMV pneumonia in LT recipients [14]. The gold standard for diagnosis of tissue-invasive CMV disease remains the demonstration of CMV pathology in a biopsy specimen from the involved organ. A few trials have suggested diagnosing CMV pneumonia, the detection of CMV DNA in the blood and bronchoalveolar specimens and identifying inclusion bodies in biopsy material by immunohistochemistry [15]. We had a thoracic CT scan to diagnose in our cases and quantitative CMV DNA PCR from blood and BAL fluid was positive. Two cases underwent bronchial biopsy and CMV-compatible effect and inclusion bodies were seen in pneumocytes. CMV has direct and indirect effects during active infection. These effects may trigger the development of secondary infections due to bacterial, fungal and other viral agents. Clinicians may sometimes have difficulties in making a differential diagnosis of this condition [16]. Intravenous ganciclovir and oral valganciclovir are the most commonly used drugs for the treatment of CMV disease. Antiviral therapy should be continued based on viral load monitoring and CMV viral load should be

monitored at least weekly. Guidelines currently recommend continuing of therapy until two serial assays run from samples drawn at least one week apart are negative [17,18]. We planned to start ganciclovir 5 mg/Kg daily twice treatment to our cases and to see during the course of treatment daily serum blood creatinine, ALT, AST, GGT controls and weekly serum CMV DNA values. However, two cases died under CMV pneumonia treatment. In one case, we continued the treatment until one week after the viral load was negative; we finished treatment after both bacterial pneumonia and CMV pneumonia findings and infection parameters improved.

Because of chronic immunosuppression to prevent organ rejection, transplant recipients are at risk of secondary pulmonary infections. Following LT, bacteria and CMV account for a majority of the severe pneumonias [19]. Although the clinical, laboratory and radiological findings of our cases supported CMV pneumonia, bacterial agents were present in simultaneously BAL fluid cultures. Although CMV pneumonia appears to occur less often after LT than previously reported, it still substantially and negatively affects patient survival. In a study by Aduen *et al.*, *P. aeruginosae* was found to be dominant in eight of the 14 patients who developed pneumonia in the first month after LT. In the early period after LT, bacteria, especially *P. aeruginosa*, continue to be the predominant type of organism causing pneumonia [20]. BAL cultures of our two cases yielded *P. aeruginosae*. This situation caused the clinical course to be worse. Two cases died despite the appropriate combined antibacterial and antiviral treatments, and one case was achieved with clinical improvement after four weeks of treatment. We could not make a clear comment on whether CMV is the sole effect of the severe clinical findings or whether it is a combined effect with a bacterial infection. It should be kept in mind that CMV infections may develop in LT recipients, especially in the first three months, where immunosuppression is the most intense, despite active antiviral prophylaxis. Plasma CMV DNA levels should be seen in patients with unexplained fever, bicytopenia/pancytopenia, elevated transaminases/bilirubin values and must be careful concerning CMV tissue-invasive disease [21].

Conclusions

It should not be forgotten that CMV pneumonia may be alone or developing PJP and bacterial pneumonia attacks on the basis of CMV pneumonia and should be kept in mind to cause severe clinical course. Although antiviral prophylaxis, CMV pneumonia can

rarely be seen in LT recipients with the suspicion of antiviral resistance, and it can be mortal. Further studies are needed on this subject.

References

1. Beam E, Razonable RR (2012) Cytomegalovirus in solid organ transplantation: epidemiology, prevention, and treatment. *Curr Infect Dis Rep* 14: 633–641.
2. Tan SK, Waggoner JJ, Pinsky BA (2015) Cytomegalovirus load at treatment initiation is predictive of time to resolution of viremia and duration of therapy in hematopoietic cell transplant recipients. *J Clin Virol* 69: 179-183.
3. Stratta RJ, Pietrangeli C, Baillie GM (2010) Defining the risks for cytomegalovirus infection and disease after solid organ transplantation. *Pharmacotherapy* 30: 144-157.
4. Knollmann FD, Maurer J, Bechstein WO, Vogl TJ, Neuhaus P, Felix R (2000) Pulmonary disease in liver transplant recipients. Spectrum of CT features. *Acta Radiol* 41: 230-236.
5. Hosseini-Moghaddam SM, Shokoochi M, Singh G, Dufresne SF, Boucher A, Jevnikar A, Prasad GVR, Shoker A, Kabbani D, Hebert MJ, Cardinal H, Houde I, Humar A, Kumar D (2019) A multicenter case-control study of the effect of acute rejection and cytomegalovirus infection on pneumocystis pneumonia in solid organ transplant recipients. *Clin Infect Dis* 68: 1320-1326.
6. Humar A, Snyderman D; AST Infectious Diseases Community of Practice (2009) Cytomegalovirus in solid organ transplant recipients. *Am J Transplant* 9 Suppl 4: 78-86.
7. Palmer SM, Grinnan DC, Diane Reams B, Steele MP, Messier RH, Duane Davis R (2004) Delay of CMV infection in high-risk CMV mismatch lung transplant recipients due to prophylaxis with oral ganciclovir. *Clin Transplant* 18: 179-185.
8. Lumbreras C, Manuel O, Len O, ten Berge IJ, Sgarabotto D, Hirsch HH (2014) Cytomegalovirus infection in solid organ transplant recipients. *Clin Microbiol Infect* 20 Suppl 7: 19-26.
9. Yadav SK, Saigal S, Choudhary NS, Saha S, Kumar N, Soim AS (2017) Cytomegalovirus infection in liver transplant recipients: Current approach to diagnosis and management. *J Clin Exp Hepatol* 7: 144-151.
10. Shorr AF, Abbott KC, Agadoa LY (2003) Acute respiratory distress syndrome after kidney transplantation: epidemiology, risk factors, and outcomes. *Crit Care Med* 31: 1325-1330.
11. Snyderman DR (1994) Cytomegalovirus prophylaxis strategies in high-risk transplantation. *Transplant Proc* 5 Suppl 1: 20–22.
12. Golfieri R, Giampalma E, Morselli Labate AM, d'Arienzo P, Jovine E, Grazi GL, Mazziotti A, Maffei M, Muzzi C, Tancioni S, Sama C, Cavallari A, Gavelli G (2000) Pulmonary complications of liver transplantation: radiological appearance and statistical evaluation of risk factors in 300 cases. *Eur Radiol* 10: 1169-1183.
13. Connors GR, Christopher-Stine L, Oddis CV, Danoff SK (2010) Interstitial lung disease associated with the idiopathic inflammatory myopathies: what progress has been made in the past 35 years? *Chest* 138: 1464-1474.
14. Kim DJ, Kim SJ, Park J, Choi GS, Lee S, Kwon CD, Ki C, Joh J (2007) Real-time PCR assay compared with antigenemia assay for detecting cytomegalovirus infection in kidney transplant recipients. *Transplant Proc* 39: 1458–1460.
15. Chemaly RF, Yen-Lieberman B, Castilla EA, Reilly A, Arrigain S, Farver C, Avery RK, Gordon SM, Procop GW (2004) Correlation between viral loads of cytomegalovirus in

- blood and bronchoalveolar lavage specimens from lung transplant recipients determined by histology and immunohistochemistry. *J Clin Microbiol* 42: 2168-2172.
16. Bruminhent J, Razonable RR (2014) Management of cytomegalovirus infection and disease in liver transplant recipients. *World J Hepatol* 27: 370–383.
 17. Torre-Cisneros J, Aguado JM, Caston JJ, Almenar L, Alonso A, Cantisán S, Carratalá J, Cervera C, Cordero E, Fariñas MC, Fernández-Ruiz M, Fortún J, Frauca E, Gavaldá J, Hernández D, Herrero I, Len O, Lopez-Medrano F, Manito N, Marcos MA, Martín-Dávila P, Monforte V, Montejo M, Moreno A, Muñoz P, Navarro D, Pérez-Romero P, Rodríguez-Bernot A, Rumbao J, San Juan R, Vaquero JM, Vidal E Spanish Society of Transplantation (SET); Group for Study of Infection in Transplantation of the Spanish Society of Infectious Diseases and Clinical Microbiology (GESITRA-SEIMC); Spanish Network for Research in Infectious Diseases (REIPI) (2016) Management of cytomegalovirus infection in solid organ transplant recipients: SET/GESITRA-SEIMC/REIPI recommendations. *Transplant Rev* 30: 119-143.
 18. Kotton CN, Kumar D, Caliendo AM, Huprikar S, Chou S, Danziger-Isakov L, Humar A, The Transplantation Society International CMV Consensus Group (2018) The third international consensus guidelines on the management of cytomegalovirus in solid-organ transplantation. *Trasplant Rev* 102: 900-931.
 19. Xia D, Yan LN, Xu L, Li B, Zeng Y, Wen TF, Zhao JC, Yang JY, Wang WT, Xu MQ, Chen ZY, Pang MH (2006) Postoperative severe pneumonia in adult liver transplant recipients. *Transplant Proc* 38: 2974-2978.
 20. Aduen JF, Hellinger WC, Kramer DJ, Stapelfeldt WH, Bonatti H, Crook JE, Steers JL, Burger CD (2005) Spectrum of pneumonia in the current era of liver transplantation and its effect on survival. *Mayo Clin Proc* 80: 1303-1306.
 21. Garrigue I, Doussau A, Asselineau J, Bricout H, Couzi L, Rio C, Merville P, Fleury H, Lafon ME, Thiébaud R (2008) Prediction of cytomegalovirus (CMV) plasma load from evaluation of CMV whole-blood load in samples from renal transplant recipients. *J Clin Microbiol* 46: 493–498.

Corresponding author

Adem Kose, MD.

Department of Infectious Diseases and Clinical Microbiology,
Faculty of Medicine, Inonu University, Elazığ yolu 8 Km
TR 44280 Malatya, Turkey.

Tel: +905330163644

Fax: +90(422)3411220

Email: adem.kose@inonu.edu.tr

Conflict of interests: No conflict of interests is declared.