

Case Report

Clinical and mycological characteristics of keratitis caused by *Colletotrichum gloeosporioides*: A case report and review of literature

Alireza Izadi¹, Mohammad Soleimani², Roshanak Daie Ghazvini¹, Seyed Jamal Hashemi¹, Mohssen Gramishoar¹, Kazem Ahmadikia¹, Mehdi Aminizadeh², Mohammad Ghahri³, Zohre Abedinifar³, Aleksandra Barac⁴, Sadegh Khodavaisy¹

¹ Department of Medical Parasitology and Mycology, School of Public Health, Tehran University of Medical Sciences, Tehran, Iran

² Department of Ocular Trauma and Emergency, Farabi Eye Hospital, Tehran University of Medical Sciences, Tehran, Iran

³ Eye Research Center, Farabi Eye Hospital, Tehran University of Medical Sciences, Tehran, Iran

⁴ Clinic for Infectious and Tropical Diseases, Clinical Centre of Serbia, Faculty of Medicine, University of Belgrade, Belgrade, Serbia

Abstract

Introduction: *Colletotrichum* species are well-known plant pathogens, which have been increasingly reported as the cause of keratitis or subcutaneous lesions in humans. In this study we reported a rare case of fungal keratitis from Iran and reviewed the literature.

Case Presentation: A 69-year-old man whose right eye was injured by herbal material was examined by slit-lamp biomicroscopy and mycology investigation of corneal scrapings was done. The grown filamentous fungal was identified as *Colletotrichum gloeosporioides* based on morphological characteristics and DNA sequence of the internal transcribed spacer region. The isolated strain was sensitive to amphotericin B, caspofungin, anidolafungin, micafungin, voriconazole, and relatively resistant to fluconazole, and itraconazole. Patient was successfully treated with voriconazole.

Conclusions: This report highlights that the early and accurate identification and therapy can be helpful to management of keratitis caused by *C. gloeosporioides*.

Key words: *Colletotrichum gloeosporioides*; Keratitis; Molecular identification.

J Infect Dev Ctries 2021; 15(2):301-305. doi:10.3855/jidc.14492

(Received 15 December 2020 – Accepted 14 February 2021)

Copyright © 2021 Izadi *et al.* This is an open-access article distributed under the Creative Commons Attribution License, which permits unrestricted use, distribution, and reproduction in any medium, provided the original work is properly cited.

Introduction

Fungal keratitis (FK) is one of the main causes of ocular morbidity [1]. Delay or inappropriate treatment can be potentially leading cause of blindness [2]. In recent years, the genus *Colletotrichum* has been recognized as an infrequent cause of FK [2-4]. *Colletotrichum* species are common plant pathogens in tropical and subtropical regions worldwide [3-5]. Trauma with plant materials is one of the main predisposing factors in keratitis caused by these fungi [6]. Among *Colletotrichum* genus, only a few species are known to be pathogenic for humans. The *Colletotrichum* spp. have been associated with human ophthalmic infections including *C. dematium*, *C. coccodes*, *C. gloeosporioides*, *C. graminicola*, *C. crassipes*, *C. capsicii* [7]. Based on the literature, *C. gloeosporioides* considered as the second most common cause of FK after *Colletotrichum dematium*

[8,9]. Though *Colletotrichum* infection in humans is rare, to avoid ophthalmic complications an early identification of pathogenic fungus and their antibiotic susceptibility can be helpful for management of the infection. Molecular techniques may help in accurate diagnosis of the agent [7]. Close resemblance of the curved conidia of *Fusarium* and *Colletotrichum* spp. may mislead inexperienced laboratory personnel [3]. Here, we review the literature and report a case of FK. To our knowledge, this is the first case report documenting the clinical and mycological characteristics of FK caused by *C. gloeosporioides* from Iran.

Case presentation

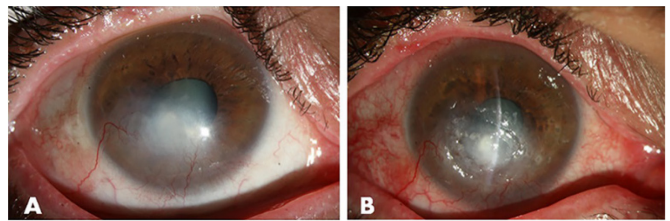
A 69-year-old male farmer presented to Farabi eye hospital in Tehran with a sudden loss of visual acuity. He mentioned a history of ocular trauma in right eye by

herbal material 10 days earlier. On initial examination of the patient, visual acuity (VA) was counting fingers in the right eye and 20/25 in the left eye. Slit lamp examination of the affected eye revealed superficial corneal infiltration with a size of 4×3 mm and epithelial defect without hypopyon (Figure 1). Corneal scrapings are obtained using sterile surgical blades for mycological examination. One sample was used to perform potassium hydroxide (KOH) mount and routine Gram's staining, while the second was inoculated into Sabouraud dextrose agar (SDA- Merck, Germany) supplemented with 0.5% chloramphenicol and sheep blood agar plates, which incubated at 28°C and 37°C, respectively. Microscopic examinations by KOH mount and gram's staining of sample showed septate filamentous fungal fragments and did not show any bacterial cells. Based on clinical findings and the result of microscopic examination of corneal scraping, treatment was initiated with topical 0.1% voriconazole, vancomycin and ceftazidime hourly. Culture of corneal scrapings revealed brownish-black filamentous fungal colonies, consisting of numerous sclerotia on SDA (Figure 2). The microscopic examination of fungal colonies showed abundant cylindrical non-septate conidia with blunt ends and darkly pigmented with white aerial hyphae (Figure 3), which are features characteristic of the genus *Colletotrichum*. DNA was extracted using a DNA isolation kit (Gene All DNA extraction kit; Gene All, Germany) according to the manufacturer's instructions and stored at -20°C prior to use. To confirm the *Colletotrichum* species identification, the Internal Transcribed Spacer (ITS) region was sequenced, as previously described [10]. Yielded sequence was subjected to Basic Local Alignment Search Tool (BLAST) program (<http://www.blast.ncbi.nlm.nih.gov/Blast>). The DNA sequence of the ITS gene matched that of *Colletotrichum gloeosporioides* species (GenBank MT130718) by showing 99% similarity with the ex-type strain of the species (GenBank MT065696). Additionally, *in vitro* antifungal testing was performed according to the Clinical and Laboratory Standards Institute (CLSI) M38-A2 for filamentous fungi [11]. The minimal inhibitory concentrations (MICs) of amphotericin B, fluconazole, voriconazole, itraconazole, caspofungin, anidulafungin and micafungin were 0.5, >64, 0.5, 8, 0.5, 0.5 and 0.25 respectively. The patient was treated with voriconazole every hour, levofloxacin 4 hours and passing 42 days, the lesion turned into corneal scar and there were no signs of a recurrence after 2 months of treatment with voriconazole.

Discussion

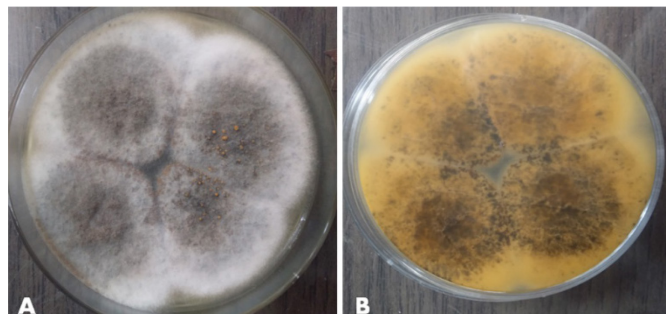
Colletotrichum species are coelomycetous soil fungi that are an uncommon cause of keratitis worldwide [5, 6]. Traumatic insemination is important for the initiation of *Colletotrichum* infection [2]. Thorough search of literature using “Keratitis” and “*Colletotrichum*” showed *Colletotrichum spp.* keratitis is increasingly reported (Table 1). Fernandez *et al.* reported, FK due to *Colletotrichum* was in 10 of 360

Figure 1. Slit lamp photographs of right eye.



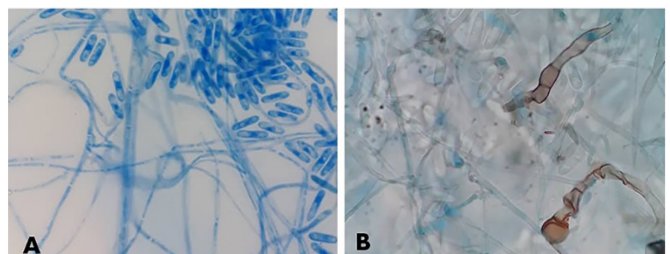
(A) Corneal ulcer with infiltration and the centrifugal, linear, circular spread of fungal infection through the corneal channels, (B) Corneal scarring after treatment with voriconazole.

Figure 2. Fungal colonies growth on Sabouraud dextrose agar.



(A) The growing fungus produced brown-gray concentrically ringed colonies. *Colletotrichum gloeosporioides* produced orange mucus beads centrally after 10 days at 30°C. (B) Reverse side showing brownish-black pigmentation.

Figure 3. (A) Lactophenol cotton blue tease mount from the colony. Hyphae with abundant cylindrical conidia with blunt ends (magnification X400); (B) brownish appressoria, which are characteristic features of *Colletotrichum gloeosporioides* (magnification X400).



cases (2.8%) [12]. In other series by Kaliamurthy *et al.* [13] and Hung *et al.* [3], *Colletotrichum* was the cause of FK in 7 of 378 cases (1.9%) and in 7 of 65 cases (10.8%), respectively. The ocular trauma and contamination by organic materials were principal risk factors for *Colletotrichum* keratitis [12, 13]. Our case had a history of ocular injury by herbal material during farm work, similar to other cases reported [8, 9, 14]. *Colletotrichum* spp. can be identified by nonseptate conidia, presence of appressoria, and (in the later stage)

acervuli with setae but the morphological identification is time-consuming and technically challenging [7]. Due to the difficulty of the morphological identification of *Colletotrichum* spp., molecular approaches based on the nucleic acid sequence of ITS region are the more applicable and accurate method for isolates identification to the species level in the diagnostic laboratory [5, 15]. Most cases of FK caused by *Colletotrichum* species, particularly *C. dematium* and *C. gloeosporioides* respond well to natamycin, possibly

Table 1. Summary of previously reported cases reports of *Colletotrichum gloeosporioides* keratitis.

Authors (Reference)	Country, Year	No. of case	Age/ Sex	Predisposing factor and risk factor	Eye direction	Initial visual activity	Hypopyon	Medical therapy	Fungal identification method	Outcome
María Borrás-Máñez <i>et al.</i> (5)	Spain, 2015	1	75 / M	trauma with plant material (orange tree branch)	NM	NM	Yes	Voriconazole, Keratoplasty	Microscopic, culture and molecular (sequencing)	Evisceration
S.T. Pote <i>et al.</i> (19)	India, 2017	1	45 / M	trauma with with stone chip	Right	6/60	Yes	Amphotericin-B, Voriconazole, Natamycin	Microscopic, culture and molecular (DNA sequencing of its region)	CI
Lipeng Wang <i>et al.</i> (15)	China, 2019	1	52 / M	trauma with plant material (apple tree branch)	Right	NM	NM	Natamycin, Levofloxacin, Voriconazole	Microscopic, culture, MALDI-TOF, DNA sequencing of ITS,	CI
Atsushi Shiraishi <i>et al.</i> (4)	Japan, 2011	3	80 / F	Trauma with dust particles	Right	20/2,000	Yes	Voriconazole, Pimaricin	Microscope, culture, DNA sequencing of ITS	CI
			71 / F	Trauma with plant material	Left	20/80	NM	Voriconazole, Natamycin, Moxifloxacin	Microscope, culture, DNA sequencing of ITS	CI
Noriaki Yamamoto <i>et al.</i> (9)	Japan, 2001	1	60 / M	Trauma with plant material (orange tree branch)	Right	20/300	NM	Voriconazole, Miconazole, Natamycin, Levofloxacin	Microscope, culture, DNA sequencing of ITS	CI
			82 / M	Injured by insect, cataract surgery 6 months previously, myelodysplastic syndrome	Left	20/30	NM	Natamycin, Fluconazole	Microscope, culture	CI
Ning Hung <i>et al.</i> (3)	Taiwan, 2020	5	72 / M	Farming, dirty water contact	NM	20/200	NM	Natamycin	Microscope, culture, DNA sequencing of ITS	CI
			22 / M	Trauma with metallic body	NM	20/30	NM	No antifungal medication	Microscope, culture, DNA sequencing of ITS	CI
			79 / F	Farming, soil contact	NM	20/125	NM	Amphotericin B, Voriconazole	Microscope, culture, DNA sequencing of ITS	CI
J. Lamarca <i>et al.</i> (20)	Spain, 2015	1	63 / F	Trauma with plant material	NM	20/100	NM	No antifungal medication	Microscope, culture, DNA sequencing of ITS	CI
			77 / F	Unknown	NM	20/800	NM	Natamycin, Amphotericin B	Microscope, culture, DNA sequencing of ITS	CI
Ismail Zakariya-Yousef Brevál <i>et al.</i> (21)	Spain, 2019	1	45 / M	Trauma with plant material (orange tree branch)	Right	NM	Yes	Voriconazole	Microscope, culture	CI
Our case	Iran, 2020	1	69 / M	Trauma with plant material	Right	counting fingers	No	Voriconazole	Microscope, culture, DNA sequencing of ITS	CI

Abbreviations: M: male; F: female; NM: not mentioned; CI: clinical improvement.

Table 2. The MICs of antifungal drugs on the *C. gloeosporioides* isolated from reported case.

Authors (Reference)	MICs (µg/ml)										
	Amphotericin B	Fluconazole	Voriconazole	Itraconazole	Posaconazole	Miconazole	Caspofungin	Anidulafungin	Micafungin	5- flucytosine	Natamycin
Lipeng Wang <i>et al.</i> (15)	0.25	64	0.25	0.25	0.25	-	0.25	0.12	0.06	16	-
Atsushi Shiraishi <i>et al.</i> (4)	0.125	>64	0.5	0.25	-	0.5	-	-	<0.03	>64	4
	<0.03	64	0.125	0.125	-	0.25	-	-	<0.03	2	4
	<0.03	16	0.125	0.03	-	0.25	-	-	0.125	>64	2
Our case	0.5	>64	0.5	8	-	-	0.5	0.5	0.25	-	-

due to its easy availability [12, 13]. However, Shiraishi *et al.* and Fernandez *et al.* reported that isolates of *C. gloeosporioides* in their study showed intermediate resistance to natamycin [4, 12]. In our reported case, simultaneous voriconazole regimen leads to complete regression of eye lesion. The excellent results have been reported following voriconazole treatment in cases of FK and endophthalmitis caused by a number of species of fungi [16, 17]. Shiraishi *et al.* [4] treated 3 cases of *C. gloeosporioides* keratitis with voriconazole, as well as Mitani *et al.* reported [2]. However, Máñez *et al.* [5] reported oral, topical, intravitreal and intrastromal voriconazole showing no improvement of eye lesion. In some case reported combination therapy (natamycin plus amphotericin-B/voriconazole) may be more effective than monotherapy [4]. There is a lack of consensus regarding the optimal therapy against *Colletotrichum spp.* ophthalmic infection in the literature [15]. Few reports mentioning the drug sensitivity test against *C. gloeosporioides* [4, 15]. Shiraishi *et al.* indicated that all three *C. gloeosporioides*, isolated cases of FK, were sensitive to amphotericin B, itraconazole, miconazole, micafungin, and voriconazole, and relatively resistant to flucytosine, fluconazole, and natamycin [4]. Also, Mitani *et al.*, reported similar results [2]. The MICs of different antifungal drugs on the *C. gloeosporioides* isolated from case reports are shown in Table 2. Reported studies have indicated that the majority of *Colletotrichum* isolates have a different degree of resistance to antifungal drugs and therefore combination therapy may be more effective than monotherapy for complete cure of patients having *Colletotrichum* infections [18, 19].

In conclusion, this is a rare FK case caused by *C. gloeosporioides* in Iran. The results suggest that molecular investigations and antifungal susceptibility testing will be required to further understand the epidemiology and optimal management of FK caused by rare fungal pathogens in humans.

Acknowledgements

Authors would like to thank staff of Farabi Eye Hospital and Molecular Biology of Medical Mycology Laboratory for their kind help.

Authors' contributions

AI, RDG, SJH and SK drafted the manuscript. AI, MS, MG, KA, MA, MG, ZA and SK conducted the clinical examinations and Laboratory tests. AI, MS, RDG, SJH, AB, and SK reviewed the manuscript and participated in the layout and design of the report. All authors read and approved the final manuscript.

Ethics approval and consent to participate

The patient provided a signed written informed consent to undergo the treatment. This report was approved by ethics committee of Tehran University of Medical Sciences (IR.TUMS.SPH.REC.1398.256).

Funding

This study has been funded and supported by Tehran University of Medical Sciences (TUMS); Grant no. 99-1-99-46389. Funding this study was part of a PhD. dissertation (grant No. 9611353001) supported by Tehran University of Medical Sciences. Dr. Aleksandra Barac is funded by the Project of Ministry of Education, Science and Technology of the Republic of Serbia (No. III45005).

References

- Martinez JD, Amescua G, Alfonso EC (2020) Fungal Keratitis. Foundations of Corneal Disease. Springer, Cham: pp. 37-49.
- Mitani A, Shiraishi A, Uno T, Miyamoto H, Hara Y, Yamaguchi M, Ohashi Y (2009) *In vivo* and *in vitro* investigations of fungal keratitis caused by *Colletotrichum gloeosporioides*. J Ocul Pharmacol and Th 25: 563-566.
- Hung N, Hsiao CH, Yang CS, Lin HC, Yeh LK, Fan YC, Sun PL (2020) *Colletotrichum* Keratitis: a rare yet important fungal infection of human eyes. Mycoses 63: 407-415.
- Shiraishi A, Araki-Sasaki K, Mitani A, Miyamoto H, Sunada A, Ueda A, Asari S, Zheng X, Yamamoto Y, Hara Y, Ohashi Y (2011) Clinical characteristics of keratitis due to *Colletotrichum gloeosporioides*. J Ocul Pharmacol and Th 27: 487-491.
- Borrás-Máñez M, Ortega-Evangelio L, Gil-Tomás JJ, Tomás JM (2016) Keratitis due to *Colletotrichum gloeosporioides* and Herpesvirus reactivation. Enferm Infec Microbiol Clin 34: 69.

6. Tabatabaei SA, Tabatabaei M, Soleimani M, Tafti ZF (2018) Fungal keratitis caused by rare organisms. J Curr Ophthalmol 30: 91-96.
7. Shivaprakash MR, Appannanavar SB, Dhaliwal M, Gupta A, Gupta S, Gupta A, Chakrabarti A (2011) *Colletotrichum truncatum*: an unusual pathogen causing mycotic keratitis and endophthalmitis. J Clin Microbiol 49: 2894-2898.
8. O'Quinn RP, Hoffmann JL, Boyd AS (2001) *Colletotrichum* species as emerging opportunistic fungal pathogens: a report of 3 cases of phaeoerythromycosis and review. J Am Acad Dermatol 45: 56-61.
9. Yamamoto N, Matsumoto T, Ishibashi Y (2001) Fungal keratitis caused by *Colletotrichum gloeosporioides*. Cornea 20: 902-903.
10. Klindworth A, Pruesse E, Schweer T, Peplies J, Quast C, Horn M, Glöckner FO (2013) Evaluation of general 16S ribosomal RNA gene PCR primers for classical and next-generation sequencing-based diversity studies. Nucleic acids res 41: e1-e1.
11. Wayne P (2008) Reference Method for Broth Dilution antifungal susceptibility testing of filamentous fungi, Approved Standard M38-A2: Clinical and Laboratory Standards Institute.
12. Fernandez V, Dursun D, Miller D, Alfonso EC (2002) *Colletotrichum* keratitis. Am J Ophthalmol 134: 435-438.
13. Kalamurthy J, Kalavathy C, Ramalingam M, Prasanth DA, Jesudasan CN, Thomas PA (2004) Keratitis due to a coelomycetous fungus: case reports and review of the literature. Cornea 23: 3-12.
14. Mendiratta D, Thamke D, Shukla A, Narang P (2005) Keratitis due to *Colletotrichum dematium*-a case report. Indian J Med Microbiol 23: 56.
15. Wang L, Yu H, Jiang L, Wu J, Yi M (2020) Fungal keratitis caused by a rare pathogen, *Colletotrichum gloeosporioides*, in an east coast city of China. Journal de Mycologie Médicale: 100922.
16. Bunya VY, Hammersmith KM, Rapuano CJ, Ayres BD, Cohen EJ (2007) Topical and oral voriconazole in the treatment of fungal keratitis. Am j ophthalmol 143:151-153.
17. Sponsel W, Chen N, Dang D, Paris G, Graybill J, Najvar LK, Zhou L, Lam KW, Glickman R, Scribbick F (2006) Topical voriconazole as a novel treatment for fungal keratitis. Antimicrob agents chemother 50: 262-268.
18. Guarro J, Svidzinski TE, Zaror L, Forjaz MH, Gené J, Fischman O (1998) Subcutaneous Hyalohyphomycosis Caused by *Colletotrichum gloeosporioides*. J Clin Microbiol 36: 3060-3065.
19. Pote S, Chakraborty A, Lahiri K, Patole M, Deshmukh R, Shah S (2017) Keratitis by a rare pathogen *Colletotrichum gloeosporioides*: A case report. J Mycol Med 27: 407-411.
20. Lamarca J, Vilaplana F, Nadal J, García-Barberán I, Barraquer R (2016) Treatment resistant fungal keratitis caused by *Colletotrichum gloeosporioides*. Archivos de la Sociedad Española de Oftalmología (English Edition) 91: 97-101.
21. Breval IZ-Y, Sanabria AM, González AG, Abreu AT (2019) Queratitis fúngica por *Colletotrichum gloeosporioides*: A propósito de un caso. Revista Española de Quimioterapia 32: 198.

Corresponding author

Sadegh Khodavaissy, PhD

Department of Medical Parasitology and Mycology, School of Public Health, Tehran University of Medical Sciences

Tehran, Iran

Tel: +982188008588

Email: sadegh_7392008@yahoo.com

Conflict of interests: No conflict of interests is declared.