

## Case Report

# *Cystoisospora belli* infection in a renal transplant recipient: a case report and review of literature

Büşra Betül Özmen-Çapın<sup>1</sup>, Gamze Gürsoy<sup>2</sup>, Sema Tortop<sup>1</sup>, Jabrayil Jabrayilov<sup>3</sup>, Ahmet Çağkan İnkaya<sup>2</sup>, Sibel Ergüven<sup>1</sup>

<sup>1</sup> Department of Medical Microbiology, Faculty of Medicine, Hacettepe University, Ankara, Turkey

<sup>2</sup> Department of Infectious Diseases and Clinical Microbiology, Faculty of Medicine, Hacettepe University, Ankara, Turkey

<sup>3</sup> Department of Internal Diseases, Nephrology Subdivision, Faculty of Medicine, Hacettepe University, Ankara, Turkey

### Abstract

*Cystoisospora belli* is a coccidian parasite that causes prolonged watery diarrhea especially among immunocompromised patients. Herein, we report a renal transplant patient who complains of alternating diarrhea and review of literature related to cystoisosporiasis amongst the transplant recipients.

**Key words:** *Cystoisospora belli*; renal transplantation; opportunistic parasites.

*J Infect Dev Ctries* 2021; 15(4):599-602. doi:10.3855/jidc.12407

(Received 17 January 2020 – Accepted 19 August 2020)

Copyright © 2021 Özmen-Çapın *et al.* This is an open-access article distributed under the Creative Commons Attribution License, which permits unrestricted use, distribution, and reproduction in any medium, provided the original work is properly cited.

### Introduction

*Cystoisospora belli* is a coccidian parasite that infects both immunocompetent and immunosuppressed individuals. Infection begins via ingestion of contaminated food and water containing mature oocysts of *C. belli*. In immunocompetent individuals, disease is usually asymptomatic or causes self-limiting diarrhea [1]. On the other hand, immunosuppressed patients present with more severe, prolonged diarrhea and can have extra-intestinal manifestations such as liver, spleen, gallbladder, and biliary tract [1,2]. We report a male patient under immunosuppressive treatment, which was rearranged recently, presented with alternating diarrhea and constipation eight years after the transplantation.

### Clinical case

A-25-year-old male patient, residing with three of his family members and working as a cashier in a supermarket in Sanliurfa, southeastern Turkey, had presented with recurrent urinary tract infections due to his vesicoureteral reflux. This resulted in chronic renal failure and he had undergone renal transplantation from cadaver in 2009. Immunosuppressive therapy (tacrolimus 2×0,5 mg, mycophenolic acid 2×500 mg

and prednisolone 1×5 mg) had been commenced to prevent organ rejection. Eight years later, because of his deterioration of kidney function tests, his immunosuppressive therapy was rearranged into tacrolimus 2×1 mg, mycophenolic acid 2×500 mg, and prednisolone 1×10 mg. Subsequent to this, the patient began to experience alternating diarrhea and constipation for the last year and diarrhea became more frequent in the last month. No additional symptoms were noted. No pathogenic bacteria was isolated from stool culture. ELISA for *Entamoeba histolytica* performed and was negative. Enteric bacteria multiplex PCR panel test (including *Salmonella* spp., *Campylobacter* spp., *Shigella* spp. / enteroinvasive *Escherichia coli*, Shiga toxin-producing *E. coli*) and enteric parasite multiplex PCR panel test (including *E. histolytica*, *Cryptosporidium* spp. and *Giardia intestinalis*) were run and none of them was detected. The macroscopic examination of the stool sample revealed no blood or mucus. In microscopic examination, non-sporulated oocysts of the parasite were detected by saline-Lugol wet mount preparations and confirmed with the modified Kinyoun's acid-fast stain [3]. Charcot Leyden crystals were observed, too. In addition, examination with fluorescence microscope

revealed autofluorescent *C. belli* oocysts (Figure 1). After that, stool sample was kept in the incubator at 37 °C and after the incubation period, sporulated oocysts were shown. The patient was treated with trimethoprim-sulfamethoxazole (800/160 mg) twice daily for 10 days. Symptoms of the patient were improved and the fecal sample was free from oocysts as an indication of both clinical and laboratory recovery. Patient was followed-up every three months thereafter, he did not present with diarrhea or any other symptoms as an evidence of reinfection. Verbal consent of the patient was obtained for this report.

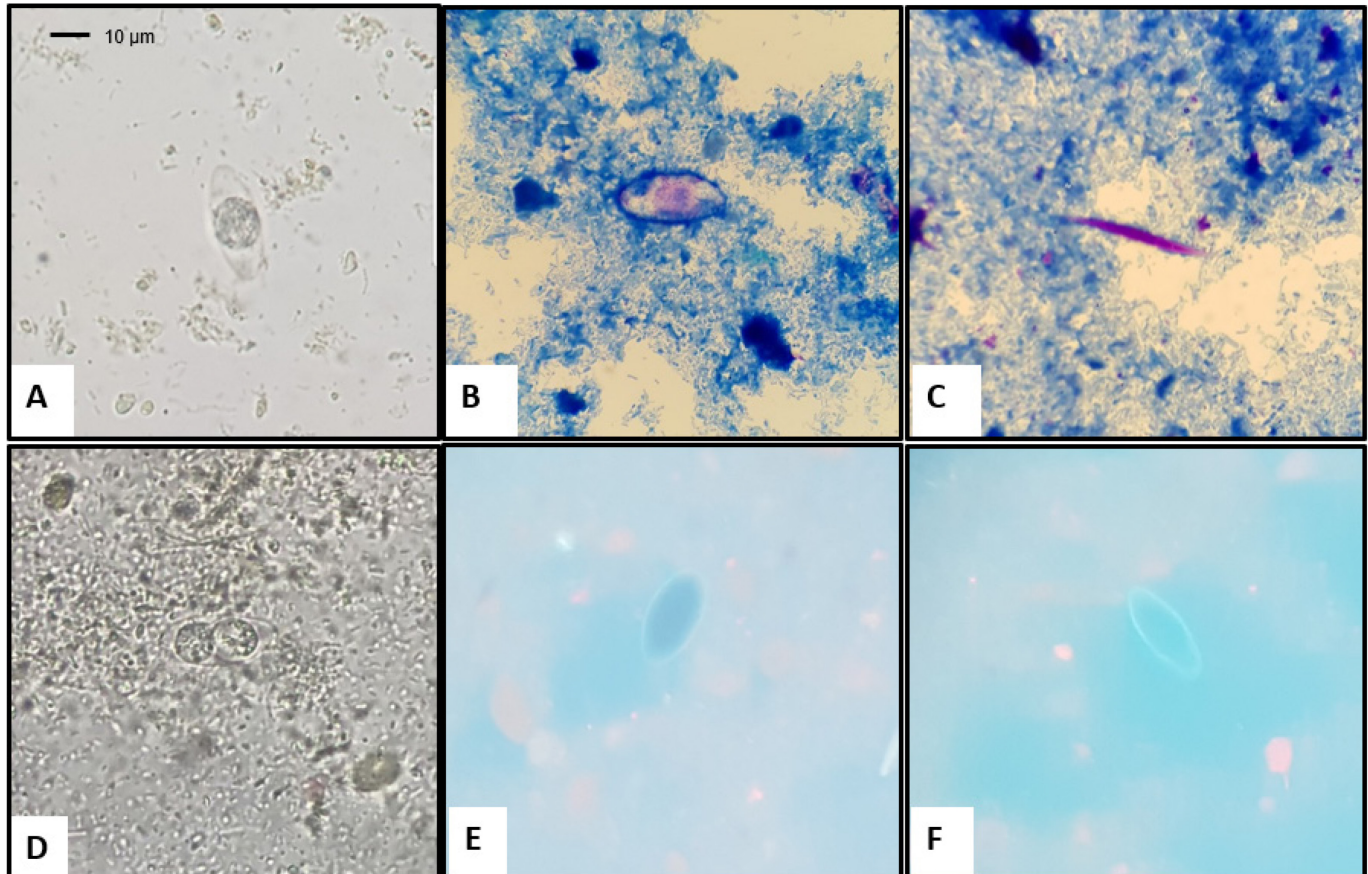
**Discussion and literature review**

We conducted a review of literature searching PubMed database using “*Cystoisospora belli*” or “*Isospora belli*” keywords at any time and among human species. Three hundred and eighty-eight results appeared. When “transplant” keyword was added, thirteen results left. Three results were irrelevant and excluded. The summary of the significant features from

*C. belli* infections among transplantation patients was shown in Table 1 [4-13].

*C. belli* infection has a global distribution with a predominance in the tropical and subtropical locations and this is the third *C. belli* infection reported amongst the renal transplantation patients in Turkey. Other two cases were in 2006 and 2007, respectively [12,13]. Our literature search showed that several renal transplantation cases with cystoisosporiasis were reported from other countries, too [6,7]. Here in this case, it has been eight years from the renal transplantation to the beginning of the *C. belli* infection. *C. belli* infection mostly presents with the prolonged watery diarrhea among immunosuppressed patients or individuals with some other situations such as poor hygiene, malnutrition, chronic alcoholism and debilitating infectious disease [14]. Since the immunosuppressive therapy is already a known risk factor, dosage increment of this therapy is also critical. However, in this case, the patient presented with alternating diarrhea and constipation. These symptoms might suggest colorectal cancer and an unnecessary

**Figure 1.** **A.** Suspected unsporulated *C. belli* oocyst (wet mount); **B.** Unsporulated *C. belli* oocyst (modified acid-fast staining method); **C.** Charcot Leyden crystal (modified acid-fast staining method); **D.** Sporulated *C. belli* oocyst (wet mount); **E and F.** Autofluorescent *C. belli* oocysts under fluorescence microscope (395-415 nm).



colonoscopy might be performed. Therefore, before these kinds of invasive procedures, this coccidian parasite should be suspected and a simple stool sample could be taken from the patient.

Diagnosis of *C. belli* is based on the demonstration of the large (25 to 30 µm), typically ellipsoidal shaped oocysts. Diagnosis can be challenging owing to intermittent and low-grade shedding of oocysts [15]. Oocysts can be visualized on wet mounts and modified acid-fast stained slides by microscopy. When oocysts are excreted, they are immature and contain one sporoblast [1]. We determine the non-sporulated oocysts of the *C. belli* by saline-Lugol wet mount and modified acid-fast staining methods. In addition, stool samples were kept in the incubator at 37 °C and we observed sporulated oocysts in the stool sample. *C. belli* oocysts will also autofluoresce under ultraviolet fluorescence microscopy [1].

**Conclusions**

In patients under immunosuppressive therapy and with complaints of prolonged diarrhea, both clinicians and microbiologists should be aware of coccidian parasites and further investigations should be carried out such as modified acid-fast staining method and/or fluorescence microscopy for these parasites which may be missed during routine coprological examination. From now on, we planned a standard screening protocol to investigate cystoisosporiasis among organ transplanted, and other immunosuppressed patients with diarrhea. By this plan, prevalence will be evaluated and epidemiological situation will be highlighted at our facility.

**References**

1. Centers for Disease Control and Prevention (CDC) (2017) Cystoisosporiasis. Available: <https://www.cdc.gov/dpdx/cystoisosporiasis/index.html>. Accessed: 1 February 2020
2. Legua P, Seas C (2013) *Cystoisospora* and *Cyclospora*. *Curr Opin Infect Dis* 26: 479-483.
3. Garcia LS (2016) Macroscopic and microscopic examination of fecal specimens. In Garcia LS, editor. *Diagnostic medical parasitology*. 6th edition. Washington, DC: ASM Press. 26-76.
4. Yadav P, Khalil S, Mirdha BR (2016) Molecular appraisal of intestinal parasitic infection in transplant recipients. *Indian J Med Res* 144: 258-263.
5. Sanches BF, Morgado J, Carvalho N, Anjos R (2015) Multiple parasitic infections in a cardiac transplant recipient. *BMJ Case Rep* 2015: bcr2014207033.
6. Gautam N, Khurana S, Sharma A, Sehgal R (2014) Isosporiasis in a tertiary care center of North India. *Indian J Pathol Microbiol* 57: 272-274.
7. Marathe A, Parikh K (2013) Severe diarrhoea due to *Cystoisospora belli* in renal transplant patient on immunosuppressive drugs. *Indian J Med Microbiol* 31: 185-187.
8. Usluca S, Inceboz T, Unek T, Aksoy U (2012) *Isospora belli* in a patient with liver transplantation. *Turkiye Parazitolo Derg* 36: 247-250.
9. Gruz F, Fuxman C, Errea A, Tokumoto M, Fernandez A, Velasquez J, Nagel C, Ruf A, Murino E, Nachman F, Rumbo M, Gondolesi G (2010) *Isospora belli* infection after isolated intestinal transplant. *Transpl Infect Dis* 12: 69-72.
10. Atambay M, Bayraktar MR, Kayabas U, Yilmaz S, Bayindir Y (2007) A rare diarrheic parasite in a liver transplant patient: *Isospora belli*. *Transplant Proc* 39: 1693-1695.
11. Aksoy U, Tuncay S (2007) Short communication: investigation of intestinal coccidia in patients with diarrhea. *Mikrobiyol Bul* 41: 127-131. [Article in Turkish].
12. Koru O, Araz RE, Yilmaz YA, Erguven S, Yenicesu M, Pektas B, Tanyuksel M (2007) Case report: *Isospora belli* infection in a renal transplant recipient. *Turkiye Parazitolo Derg* 31: 98-100.

**Table 1.** Summary of the significant features of *C. belli* infections among transplantation patients.

Author, year and reference	Country	Sex and age	Number of patients	Transplantation	Signs and symptoms
Yadav <i>et al.</i> 2016 [4]	India	Not specified*	3*	Not specified*	Diarrhea
Sanches <i>et al.</i> 2015 [5]	Portugal	Female, 13	1	Cardiac	Diarrhea, weight loss
Gautam <i>et al.</i> 2014 [6]	India	Male, 34	1	Renal	Diarrhea
Marathe <i>et al.</i> 2013 [7]	India	Male, 50	1	Renal	Chronic severe watery diarrhea, low grade-fever, nausea, occult blood test positive
Usluca <i>et al.</i> 2012 [8]	Turkey	Male, 35	1	Liver	Colic, diarrhea, occult blood test positive
Gruz <i>et al.</i> 2010 [9]	Argentina	Male, 23	1	Intestinal	High ostomy output, dehydration, abdominal pain, hypokalemia
Atambay <i>et al.</i> 2007 [10]	Turkey	Female, 25	1	Liver	Abdominal pain, nausea, watery diarrhea
Aksoy <i>et al.</i> 2007 [11]	Turkey	Not specified	1	Liver	Diarrhea
Koru <i>et al.</i> 2007 [12]	Turkey	Male, 32	1	Renal	Abdominal pain, watery diarrhea, low grade-fever, nausea
Yazar <i>et al.</i> 2006 [13]	Turkey	Male, 25	1	Renal	Weakness, nausea, vomiting, diarrhea

\* Stool samples obtained from 38 transplant recipients comprising 29 renal, two liver and seven bone marrow transplant recipients presenting with diarrhea. In three patients, *C. belli* was detected. Any additional data was not specified related to these patients.

13. Yazar S, Tokgoz B, Yaman O, Sahin I (2006) *Isospora belli* infection in a patient with a renal transplant. *Turkiye Parazitol Derg* 30: 22-24. [Article in Turkish].
14. Garcia LS (2016) Intestinal Protozoa (Coccidia), Microsporidia, and Algae. In Garcia LS, editor. *Diagnostic medical parasitology*. 6th edition. Washington, DC: ASM Press. 637-642.
15. Woon SA, Yang R, Ryan U, Boan P, Prentice D (2016) Chronic *Cystoisospora belli* infection in an immunocompetent Myanmar refugee- microscopy is not sensitive enough. *BMC Infect Dis*. 16: 221.

**Corresponding author**

Büşra Betül Özmen Çapın, MD  
Hacettepe Üniversitesi Tıp Fakültesi, Tıbbi Mikrobiyoloji  
Anabilim Dalı, 06100, Sıhhiye, Ankara, Turkey  
Phone: +90 312 305 15 70  
Fax: +90 312 310 05 80  
Email: busrabetulozmen@gmail.com

**Conflict of interests:** No conflict of interests is declared.