

Letter to the Editor

Unusual presentations of actinomycosis: a case series and literature review

Tomislava Skuhala^{1,2}, Dalibor Vukelić^{1,3}, Boško Desnica¹, Mirjana Balen-Topić^{1,3}, Andrija Stanimirović^{4,5}, Klaudija Višković¹

¹ University Hospital for Infectious Diseases “Dr. Fran Mihaljević”, Zagreb, Croatia

² School of Dental Medicine, University of Zagreb, Zagreb, Croatia

³ School of Medicine, University of Zagreb, Zagreb, Croatia

⁴ Department of Clinical Medicine, University of Applied Health Sciences, Zagreb, Croatia

⁵ School of Medicine, European University Cyprus, Nicosia, Cyprus

Abstract

Introduction: To review unusual actinomycosis cases that appeared as a diagnostic and therapeutic challenge at our institution and to present a literature review on the usual clinical presentations.

Methodology: This retrospective review included all patients hospitalized for actinomycosis in a 10-year period at the University Hospital for Infectious Diseases “Dr. Fran Mihaljević”, Zagreb, Croatia.

Results: A total of 15 patients were hospitalized during the observed period, 9 (60%) females and 6 (40%) males. The localizations of actinomycosis were: pelvis (5), lungs (3), blood stream (2), colon (1), penis (1), stomach (1), skin (1), cervicofacial region (1).

We present four unusual cases: subcutaneous actinomycotic abscess, actinomycosis of the stomach with underlying non-Hodgkin lymphoma, sepsis due to *Actinomyces neslundii* originated from chronic asymptomatic periapical tooth abscesses and actinomycosis of the distal part of the penile shaft.

Conclusions: Actinomycosis was a very rare clinical problem in our clinical practice (0.032% of all hospitalizations and 0.0034% of all outpatients) but among those cases classical clinical presentations were also very rare.

Key words: Actinomycosis; skin; stomach; sepsis; penis; treatment.

J Infect Dev Ctries 2021; 15(6):892-896. doi:10.3855/jidc.13414

(Received 21 July 2020 – Accepted 13 November 2020)

Copyright © 2021 Skuhala *et al.* This is an open-access article distributed under the Creative Commons Attribution License, which permits unrestricted use, distribution, and reproduction in any medium, provided the original work is properly cited.

Dear Editor,

Actinomycosis is a bacterial, slowly progressive infection that can affect virtually any site in the body. *Actinomyces israelii* is the major human pathogen, however, other species have also been associated with the disease, including *A. naeslundii*, *A. viscosus*, *A. odontolyticus*, *A. meyeri*, *A. gerencseriae* and others. *Actinomyces* species are commensals of the human oropharynx, the gastrointestinal tract, and the urogenital tract. Infections caused by *Actinomyces* spp. are mainly endogenous. They appear when tissue integrity is breached through a mucosal or skin lesion, and microorganisms then invade local structures and become pathogenic. During the infection, granulomatous tissue, reactive fibrosis and necrosis, abscesses, draining sinuses and fistulas can be formed [1-3]. Most actinomycotic infections are polymicrobial and, depending on the infection site, different bacteria have been isolated [1,3].

In a 10-year period, between January 1, 2009 and December 31, 2018, at the University Hospital for Infectious Diseases “Dr. Fran Mihaljević” in Zagreb, Croatia, a total of 15 patients were hospitalized with a diagnosis of actinomycosis, 9 (60%) females and 6 (40%) males. Localizations of actinomycosis were: pelvis (5), lungs (3), blood stream (2), colon (1), penis (1), stomach (1), skin (1), cervicofacial region (1). We present four unusual cases: subcutaneous actinomycotic abscess, actinomycosis of the stomach with underlying non-Hodgkin lymphoma, an *Actinomyces neslundii* sepsis case originated from chronic asymptomatic periapical tooth abscesses and actinomycosis of the distal part of penile shaft (Table 1) together with their laboratory findings (Table 2). After isolation in culture, the identification of *Actinomyces* to species level was made by biochemical method (VITEK Automated Reader) in all cases.

Cases Presentations

Case 1

A 75-year-old male with a medical history of atrial fibrillation, arterial hypertension, asymptomatic abdominal aortic aneurysm, and chronic lumbosacral radiculopathy, was admitted one month after the incision of a subcutaneous abscess in the right lumbar region. The physical examination on admission revealed a large (7 cm in diameter and 3 cm deep) subcutaneous abscess with purulent discharge. Four months earlier, the patient received 5% lidocaine as neural blockade in the treatment of radiculopathy. The abscess developed at the site of injection. It manifested as a painful, warm swelling in the paravertebral lumbosacral region. As the swelling and pain increased, the patient was treated with amoxicillin/clavulanic acid orally (1,000 mg BID) for one month. The treatment failed and the patient returned with fever and a suppurative fistula (Figure 1a). An incision of the lesion was performed. The pus from the abscess was cultured

and the following bacteria were isolated: 1. *Actinomyces* spp., 2. *Corynebacterium* spp., 3. *Staphylococcus* spp. (coagulase negative), 4. *Streptococcus viridans*. Intravenous penicillin was administered (4 million units QID) during one-week hospitalization, followed by a two-month oral doxycycline treatment (100 mg BID). Local wound treatment with octenidine and phenoxyethanol irrigation was performed daily. Six weeks after hospitalization, the local healing process was completed with no skin defect, but with a scar.

Case 2

A 64-year-old male with a medical history of arterial hypertension and diabetes mellitus was admitted because of actinomycosis of the stomach revealed after gastroscopy performed as part of weight loss and epigastric pain evaluation. The first gastroscopy was performed almost eight months after the onset of symptoms and revealed an infiltrative

Table 1. Patient characteristics.

	Patient 1	Patient 2	Patient 3	Patient 4
Localization of infection	skin, subcutaneous tissue	stomach	blood stream/ teeth	penis
Causative agent	<i>Actinomyces</i> spp.	<i>Actinomyces neslundii</i>	<i>Actinomyces neslundii</i>	<i>Actinomyces odontolyticus</i>
Method of detection	cultivation	Cultivation, histopathology	cultivation	cultivation
Clinical specimen	pus	tissue	blood, aspirated material	pus
Antibiotic treatment	Amoxicillin/clavulanic acid (1,000 mg BID); penicillin (4 million units QID); doxycycline (100 mg BID)	Penicillin (4 million units QID); doxycycline (100 mg BID)	Ampicillin (2,000 mg QID); amoxicillin (500 mg QID)	Clindamycin (900 mg TID); amoxicillin (500 mg QID)
Duration of therapy	3 months	6 months	6 months	4 months
Outcome	cured, with scar	cured	cured, installation of dental bridges	cured, no scar

Table 2. Patient laboratory findings on admission.

	Patient 1	Patient 2	Patient 3	Patient 4
ESR (mm/first hour)	20	80	70	62
CRP (mg/L)	3	65.7	65	192.2
AST (U/L)	49	13	16	11
ALT (U/L)	50	14	22	8
GGT (U/L)	87	28	20	29
ALP (U/L)	64	56	55	84
LDH (U/L)	333	133	224	167
Creatinine ($\mu\text{mol/L}$)	100	67	90	84
WBC ($\times 10^9/\text{L}$)	5.8	8.2	9.5	23.2
Neutrophils (%)	62.2	73.4	71	85
Lymphocytes (%)	25.6	13.1	18	5
Monocytes (%)	8.1	9.9	10	8
Eosinophils (%)	3.4	2.6	0	1
Basophils (%)	0.7	1	1	1

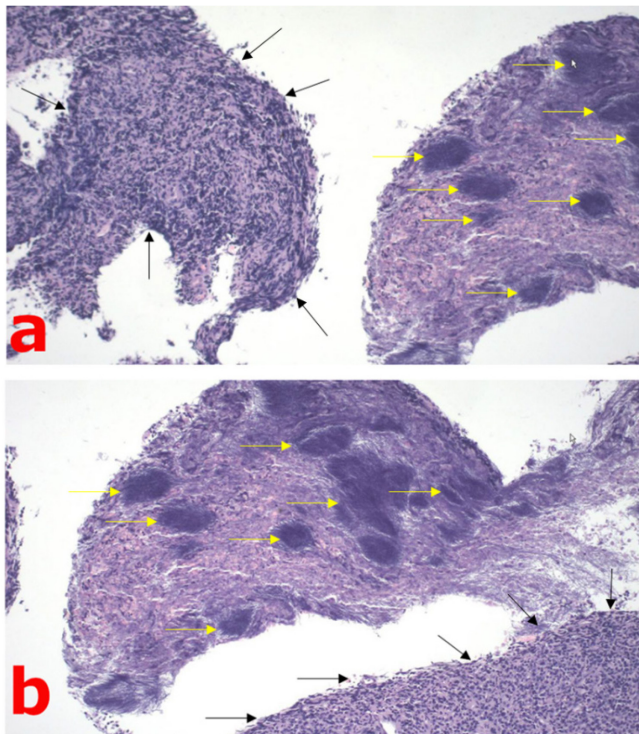
ESR: erythrocyte sedimentation rate; CRP: C-reactive protein; WBC: white blood cell count; AST: aspartate aminotransferase; ALT: alanine aminotransferase; GGT: gamma glutamyltransferase; ALP: alkaline phosphatase; LDH: lactate dehydrogenase; WBC: white blood cell count.

process of the stomach corpus and cardia. Actinomycosis was proven histologically. *Actinomyces nelsundii* was isolated from the stomach biopsy taken during the first gastroscopy. During the entire hospitalization period of 63 days, the patient received penicillin intravenously (4 million units QID) followed by doxycycline (100 mg BID) for the next three months. The last gastroscopy with biopsy was performed before discharge from the hospital. A reduction of the infiltrative process of the cardia and the upper part of the stomach was observed, and a histopathological diagnosis of non-Hodgkin lymphoma was established (Figure 2). After completion of the antimicrobial treatment actinomycosis was no more present in the bioptic material from the stomach.

Case 3

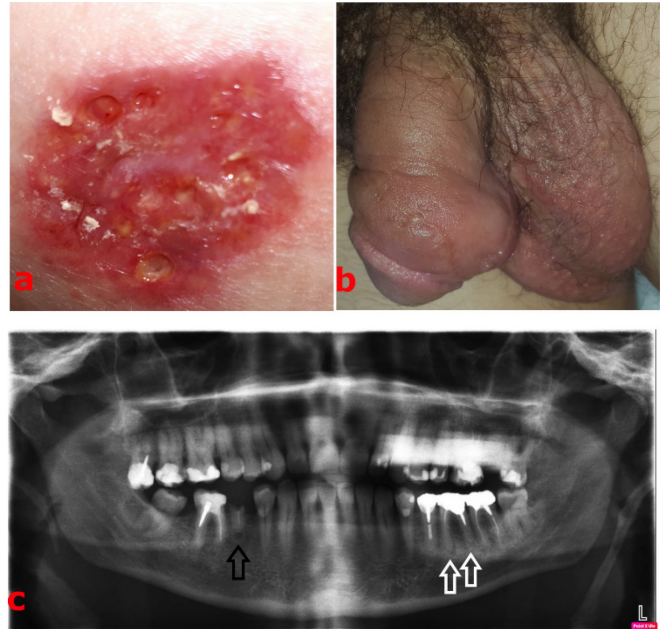
A 49-year-old male with a medical history of arterial hypertension presented with fever, chills and sweating that started ten days before admission. *Actinomyces nelsundii* was isolated from blood cultures (four aerobic and four anaerobic). Based on this finding the patient was examined by a maxillofacial surgeon. A digital orthopantomography revealed chronic

Figure 2. Histopathological findings in a patient with gastric actinomycosis and non-Hodgkin lymphoma (patient No. 2).



a. Hematoxylin and eosin stain, objective ×10; b. Hematoxylin and eosin stain, objective ×20; The black arrows indicate lymphoma infiltration, and the yellow arrows indicate area of actinomycosis.

Figure 1. Clinical manifestations of actinomycosis in presented patients.



a. Subcutaneous abscess in the right lumbar region before incision (patient No. 1); b. Painful red fluctuant inflamed mass of the distal part of the penile shaft (patient No. 4); c. Digital orthopantomography revealed chronic periapical abscesses of the 36th (white arrows) and 45th tooth (black arrow) (patient No. 3).

asymptomatic periapical abscesses of the 36th and 45th teeth (Figure 1c) and performed teeth extraction. *Actinomyces nelsundii* was isolated from the material aspirated from the abscesses after the extraction. The patient was treated with ampicillin intravenously (2,000 mg QID) for four weeks followed by oral amoxicillin (500 mg QID) for the next five months. An echocardiography did not reveal any pathological findings on the valves which could indicate endocarditis. After antibiotic treatment the patient underwent dental procedure which included installation of dental bridges replacing the missing teeth.

Case 4

We already reported on a 45-year-old male with a medical history of arterial hypertension, epilepsy and surgical correction of distal penile hypospadias in childhood, with actinomycosis of the distal part of the penile shaft caused by *Actinomyces odontolyticus* confirmed by culture (Figure 1b). He was treated with clindamycin intravenously (900 mg TID) for three weeks, followed by oral amoxicillin (500 mg QID) for the next three months, with a rapid clinical response [4]. Complete recovery of the affected penile skin was

observed. Six months after the treatment ended, no signs of relapse have been noted.

Discussion

Actinomycosis is an uncommon disease especially in Western populations, for which there are no available prevalence rates, especially for those from developing countries [2,3]. The disease can affect patients of all ages, immunocompetent and immunocompromised, but it appears to be more frequent in adults, particularly in men [2,3]. The cervicofacial (50%), abdominal (20%) and thoracic (15 to 20%) areas are the most commonly affected [2].

The laboratory findings in actinomycosis are non-specific [1,2], as also in our patients.

In cutaneous and soft tissue actinomycosis, many *Actinomyces* species have been identified. Actinomycosis is usually a secondary infectious process with underlying infective or noninfective pathological findings in deeper tissues. Skin disruption may facilitate the invasion of *Actinomyces* spp. [3,5,6]. The vast majority of actinomycotic lesions are polymicrobial (75-95%) [3], as in our patient of case 1. The role of concomitant organisms is considered to synergistically enhance the infectious process [3,7]. The puncture wound was probably the route of infection in our patient with skin and subcutaneous tissue abscess.

The involvement of the gastrointestinal tract in actinomycosis is relatively common. In the majority of cases the lower parts are involved (ileum, caecum, appendix) whereas gastric localization is rare [8,9]. High acid output in the stomach lumen prevents bacterial colonization. In most cases of gastric actinomycosis underlying diseases (tumors, ulcers) facilitate the formation of typical submucous abscesses [8-10].

Several *Actinomyces* species have been detected in blood [3,11-13] and the isolation of *Actinomyces* spp. from sterile clinical specimens is, traditionally, always viewed as significant. However, some meta-analyses suggest that in patients without evidence of clinical disease these organisms are blood-culture contaminants or represent transitory bacteremia from the oropharyngeal or bowel mucosa [11]. Even though our patient of case 3 did not have any symptoms of any type of oral infection, oral origin was first suspected, as the mouth is an important source of *Actinomyces* bacteremia.

Actinomycosis of the penis is an extremely uncommon condition, with most cases being associated with a pilonidal sinus of the penis [14].

Regarding the treatment of actinomycosis, it has been considered that a prolonged course of antimicrobial therapy with high doses of antibiotics is necessary, usually two to six weeks intravenously, followed by six to 12 months orally [1-3]. However, the modern approach to treatment is more individualized (Table 1), and the exact antibiotic regimen depends on the site of infection, the severity of the disease and the clinical response to treatment [2].

Actinomycosis was a very rare clinical problem in our clinical practice (0.032% of all hospitalizations and 0.0034% of all outpatients) but among those cases classical clinical presentations were also very rare. Because of this wide variety of clinical presentations reported in the literature and its tendency to mimic different diseases, actinomycosis acts as a ‘great pretender’ [15].

References

1. Russo TA (2015) Agents of actinomycosis. In Bennett JE, Dolin R, Blaser MJ editors. Principles and practice of infectious diseases. Philadelphia: Elsevier Saunders. 2864-2873.
2. Wong VK, Turmezei TD, Weston VC (2011) Actinomycosis. *BMJ* 343: d6099.
3. Könönen E, Wade WG (2015) Actinomyces and related organisms in human infections. *Clin Microbiol Rev* 28: 419-442.
4. Skuhala T, Tomasović D, Štimac G, Ljubičić N, Orošić D, Stanimirović A, Vukelić D (2018) Treatment of penile actinomycosis. *Dermatol Ther* 31: e12636.
5. Metgud SC (2008) Primary cutaneous actinomycosis: a rare soft tissue infection. *Indian J Med Microbiol* 26: 184-186.
6. Roy D, Roy PG, Misra PK (2003) An interesting case of primary cutaneous actinomycosis. *Dermatol Online J* 9: 17.
7. Schaal KP, Lee HJ (1992) Actinomycete infections in humans — a review. *Gene* 115: 201-211.
8. Tajima S, Waki M, Ohata A, Koda K, Maruyama Y (2015) Xanthogranulomatous gastritis associated with actinomycosis: report of a case presenting as a large submucosal mass. *Int J Clin Exp Pathol* 8: 1013-1018.
9. Al-Obaidy K, Alruwaili F, Al Nemer A, Alsulaiman R, Alruwaili Z, Shawarby MA (2015) Primary gastric actinomycosis: report of a case diagnosed in a gastroscopic biopsy. *BMC Clin Pathol* 15: 2.
10. Carneiro L, Ferreira R, Pinto J (2016) The lymphoma hidden in actinomycosis. *GE Port J Gastroenterol* 23: 273-275.
11. Jeffery-Smith A, Nic-Fhogartaigh C, Millar M (2016) Is the presence of *Actinomyces* spp. in blood culture always significant? *J Clin Microbiol* 54: 1137-1139.
12. Cone LA, Leung MM, Hirschberg J (2003) *Actinomyces odontolyticus* bacteremia. *Emerg Infect Dis* 9: 1629-1632.
13. Topić MB, Desnica B, Vicković N, Skuhala T, Bayer K, Bukovski S (2014) The polymicrobial *Actinomyces naeslundii* and *Pseudomonas aeruginosa* sepsis in a patient with ulcerative colitis 2 months after colonoscopy. *Wien Klin Wochenschr* 126: 130-132.

14. Chikkamuniyappa S, Scott RS, Furman J (2004) Pilonidal sinus of the glans penis associated with actinomyces case reports and review of literature. *Scientific World Journal* 4: 908-912.
15. Acevedo F, Baudrand R, Letelier LM, Gaete P (2008) Actinomycosis: a great pretender. Case reports of unusual presentations and a review of the literature. *Int J Infect Dis* 12: 358–362.

Corresponding author

Tomislava Skuhala, MD, PhD
University Hospital for Infectious Diseases “Dr. Fran Mihaljević”,
Mirogojska 8, 10000 Zagreb, Croatia
Phone: +385 91 4121972
Fax: +385 1 2826153
Email: tomlava_skuhala@yahoo.com

Conflict of interests: No conflict of interests is declared.