

## Case Report

# Rhino-Orbital mucormycosis in an immunocompetent pediatric patient with hyperglycemia of the hospitalized patient

Héctor Manuel Prado-Calleros<sup>1</sup>, Juan Pablo Brito-Vera<sup>1</sup>, Gabriela Moreno-Coutiño<sup>2</sup>, Lilian Elizabeth Andrade-Morelos<sup>2</sup>, Mónica Patricia Escobedo-Torres<sup>3</sup>, Genoveva Vázquez-Zavala<sup>4</sup>, Rigoberto Hernández-Castro<sup>5</sup>

<sup>1</sup> Otolaryngology and Head and Neck Surgery Department, General Hospital "Dr. Manuel Gea González", México City, México

<sup>2</sup> Mycology Department, General Hospital "Dr. Manuel Gea González", México City, México

<sup>3</sup> Pediatrics Infectology Department, General Hospital "Dr. Manuel Gea González", México City, México

<sup>4</sup> Pediatrics Intensive Care Division, General Hospital "Dr. Manuel Gea González", México City, México

<sup>5</sup> Ecology of Pathogens Department, General Hospital "Dr. Manuel Gea González", México City, México

### Abstract

**Introduction:** Acute invasive rhino-orbital mucormycosis usually affects diabetic or neutropenic patients, and only exceptionally develops in immunocompetent adults and children.

**Methodology:** A 12-years-old immunocompetent female, presented with complicated rhinosinusitis with a subperiosteal orbital abscess, without improvement after initial medical and surgical management, the patient also developed hyperglycemia of the hospitalized patient that represented a challenging and potentially lethal clinical scenario.

**Results:** Diagnosed with an unsuspected rhino-orbital mucormycosis by direct microscopy and PCR, she survived after amphotericin B and surgical treatment.

**Conclusions:** In cases with torpid clinical evolution, even in apparently immunocompetent patients, appropriate multidisciplinary workup must be performed to rule out opportunistic etiologies including mucormycosis to improve survival.

**Key words:** Mucormycosis; immunocompetent; rhinosinusitis.

*J Infect Dev Ctries* 2021; 15(7):1035-1038. doi:10.3855/jidc.14299

(Received 03 November 2020 – Accepted 15 December 2020)

Copyright © 2021 Prado-Calleros *et al.* This is an open-access article distributed under the Creative Commons Attribution License, which permits unrestricted use, distribution, and reproduction in any medium, provided the original work is properly cited.

### Introduction

Mucormycosis is a rare and frequently fatal opportunistic invasive fungal disease [1].

In adults, it usually affects immunocompromised diabetic patients, particularly in developing countries; most of the children with mucormycosis have an underlying hematological malignancy, but also uncontrolled diabetes type I has been reported. Mucormycosis exceptionally develops in immunocompetent adults and children [1].

Fungal invasive rhinosinusitis is caused by some species that belong to the order Mucorales (the most frequent *Rhizopus* spp but also by *Mucor* spp, *Lichtheimia* spp, *Cunninghamella* spp, *Apophysomyces elegans* among others) and by some species of *Aspergillus* (reported mainly in adult hematologic patients), with a tendency for vascular invasion causing thrombosis that leads to tissue necrosis [1-3].

In children, the paranasal sinus/sino-orbital region is the third site of infection; cutaneous, pulmonary, gastrointestinal, and disseminated infection have also been reported [1,2,4,5].

Diagnosis requires a high index of suspicion and the identification of the fungus with histopathology, culture, direct microscopy, and molecular tests; image studies as magnetic resonance imaging help to determine the extension in the rhino-orbit-cerebral forms [3].

Antifungals and surgery, along with correction of the underlying medical condition, are the cornerstone of treatment [3,6].

The reported mortality ranges between 33-67% depending on the underlying condition, the site and dissemination of the infection, and the treatment administered; to be noted, even in immunocompetent patients, death can occur. [1,7]

## Case Report

A 12-years-old eutrophic female, with a history of introducing a hairpin in her left nose that was extracted several hours later by a physician who also recommended an unspecified oral antibiotic. Five days later, she noted nasal obstruction, left purulent rhinorrhea, ocular pain, diplopia, and an increase of volume of her left eyelid.

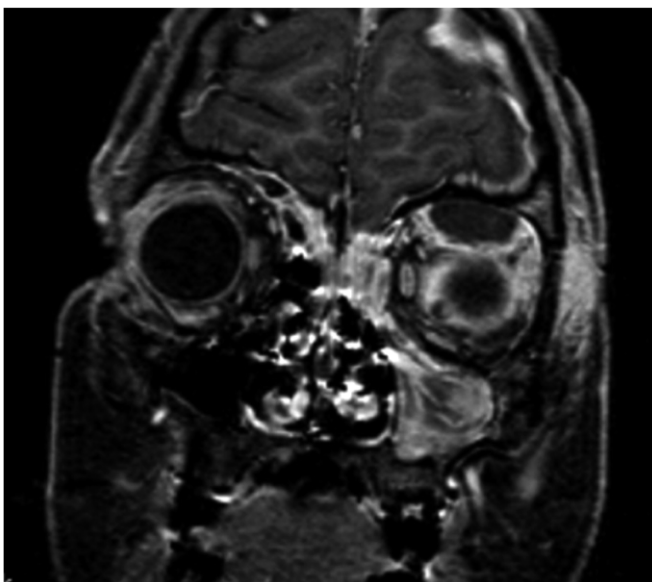
At admission in the emergency department, she was afebrile; her blood tests reported leukocytes 15,100 mm<sup>3</sup>, neutrophils 88.7%, hemoglobin 14 g/dL, glucose 107 mg/dL, creatinine 1.05 mg/dL, and C Reactive Protein 4 mg/L.

A computed tomography showed ethmoidal sinusitis and left orbital cellulitis with proptosis.

Consultation with the otolaryngology and ophthalmology departments was obtained; the nasal endoscopy showed normochromic nasal mucosa and purulent secretion at the left middle meatus. A diagnosis of complicated bacterial rhinosinusitis with orbital cellulitis was considered.

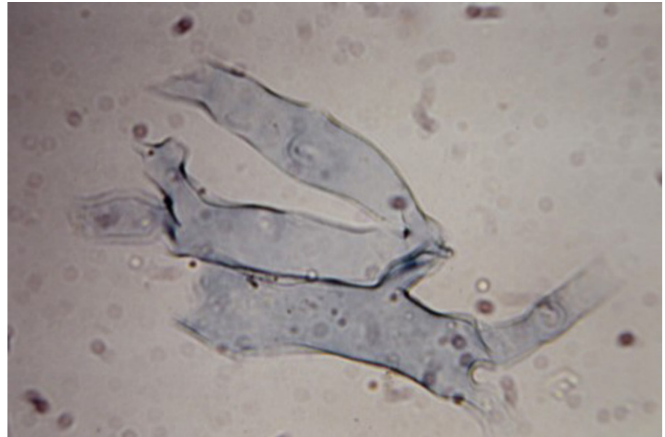
Antibiotic treatment with i.v. clindamycin (30 mg/kg/ per day) and ceftriaxone (75 mg/kg/ per day) were initiated, and she was surgically treated with endoscopic left ethmoidectomy, draining scarce purulent secretion, also, debridement of palpebral fasciitis was performed. Negative bacterial cultures were reported. Pathology of the ethmoidal sinus tissue reported mucosa with acute inflammation and bone with acute osteitis.

**Figure 1.** Magnetic Nuclear Resonance.



Subperiosteal abscess in the left orbit and meningeal thickening.

**Figure 2.** Direct microscopic examination.



Broad, non-septate hyphae branching irregularly at wide angles.

Postoperatively, she persisted with orbital swelling, ophthalmoplegia, and low-grade fever (38.2 °C maximum); headache and papilledema were detected leading to suspicion of endocranial hypertension, a cerebral magnetic resonance imaging reported an abscess in the upper left orbital region, bifrontal meningeal thickening, and left frontoethmoidal and maxillary sinusitis (Figure 1).

Vancomycin and dexamethasone were initiated, and orbital surgery performed through an external supra-ciliary approach, draining a subperiosteal abscess.

Direct microscopic examination with potassium hydroxide preparation (KOH mount) and light microscopy of the secretion revealed broad, non-septated hyphae, compatible with Mucormycosis (Figure 2).

PCR was carried out in the research laboratory, with a positive result for *Rhizopus oryzae*. Genomic DNA was isolated from paraffin-embedded tissue sample using a DNeasy blood and tissue kit (Qiagen, Ventura, CA, USA) according to the manufacturer's instructions. The molecular identification was achieved by 18S-ITS1-5.8S-ITS2-25S rRNA gene amplification using a set of primers previously reported to identify fungi species (5'-TCCGTAGGTGAACCTTGCGG-3') and ITS4 (5'-TCCTCCGCTTATTGATATGC-3') [8].

A PCR product of 630 bp was amplified, purified, and sequenced in both directions; nucleotide sequence was determined with Taq FS Dye Terminator Cycle Sequencing Fluorescence-Based Sequencing and analyzed on an Applied Biosystems 3730 DNA sequencing system (Foster City, CA, USA) (Figure 3).

The sequence was edited with the Vector NTI program, and a homology search was performed in the

GenBank database (Nucleotide Blast), finding a 100% identity with *Rhizopus oryzae* NB31, BAB-4277, CMH004, and 1231D17 strains, among others. The sequence obtained for *Rhizopus oryzae* GEA 616 was deposited in the GenBank under accession number MW345817.

Negative bacterial cultures were reported. Histopathology study showed ischemic necrosis and acute inflammation from the upper left eyelid tissue.

The patient was transferred to the pediatric intensive care unit where Amphotericin B (1 mg/kg/ per day) was initiated. No liposomal amphotericin was available at our institution.

Although her glucose on admission was within normal ranges, during her hospital stay she developed hyperglycemia up to 307 mg/dL that required insulin management. The requested glycosylated hemoglobin was 6.1%, integrating the diagnosis of hyperglycemia of the hospitalized patient by the endocrinology service.

Evaluations to rule out immunodeficiency were conducted, resulting in normal complement (C3 132 mg/dL, C4 36 mg/dL), normal immunoglobulins (IgA 207, IgG 870, IgM 107), normal thyroid profile, negative human immunodeficiency virus (HIV), Venereal Disease Research Laboratory test (VDRL), and antinuclear antibodies, ruling out also associated comorbidities.

She gradually improved, her glucose level returned to normal, and she was discharged from the hospital. After 6 months of follow-up, she is asymptomatic and without any treatment.

## Discussion

In only about 9.5-14% of children with mucormycosis, as this case report, no apparent underlying medical conditions are found, predominantly when located at sinus and sino-orbital sites, therefore, a high clinical suspicion is required for its diagnosis [1,2].

Although no consistent correlation has been found between the clinical form and the etiological agent, not infrequently, species different than *Rhizopus*, like *Apophysomyces elegans*, *Cunninghamella* spp, *Actinomyces elegans*, and *Conidiobolus* spp have been reported in the immunocompetent cases [6,7,9,10].

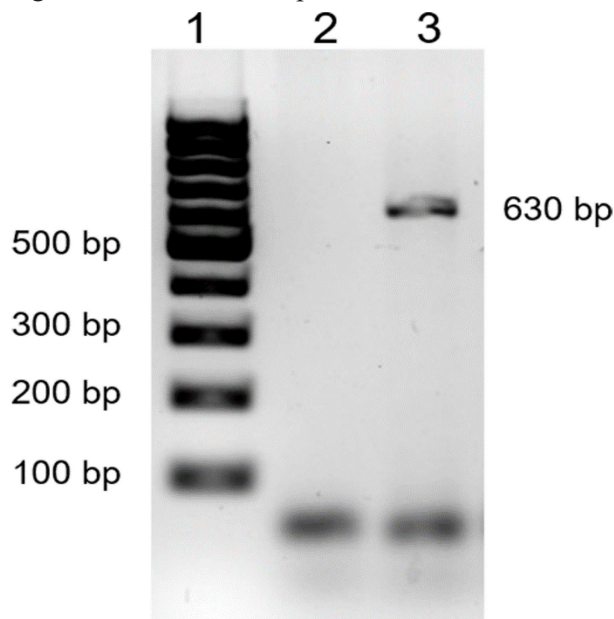
This case presented with some confounding risk factors that maybe have interacted for the development of mucormycosis: the foreign body introduced at her nose that may harbor fungal elements, the instrumentation for its removal that can have disrupted the mucosal lining, and the prescribed antibiotics that may cause dysbiosis, a known predisposing factor for superinfections [11].

Hyperglycemia of the hospitalized patient is a recognized clinical entity that can impact the mortality and morbidity in diabetics and non-diabetics who need to be managed at the emergency room and may predispose to metabolic and immunologic complications associated with its pathophysiology. As reported by Palacio *et al.* [12], hyperglycemia was present in one-fourth of the children admitted in the hospital, most of them without a history of diabetes before admission and was associated with a greater need for intensive care unit (ICU) care and longer ICU stay but not with increased in-hospital mortality, like the case we report. In patients with mucormycosis, glycemic control including cases with hyperglycemia of the hospitalized patient and correction of the underlying medical conditions, are key factors in their management [6,9].

The clinical presentation of complicated rhinosinusitis with an orbit abscess in this immunocompetent patient delayed the diagnosis of mucormycosis [13,14].

In this case, the histopathological report of ischemic necrosis, and the lack of clinical improvement, raise the clinical suspicion of an atypical cause of rhinosinusitis; until repeated surgical drainage and debridement, and

**Figure 3.** Amplification of 18S-ITS1-5.8S-ITS2-28S rRNA region from a tissue sample.



Lane 1: molecular size marker 100 bp DNA ladder; lane 2: negative control; lane 3: *Rhizopus oryzae* GEA 616.

after many differential diagnoses were ruled out, the diagnosis was achieved by a multidisciplinary team.

The limitations of this report are that it is an isolated case, and although we diagnosed the mycotic infection by PCR and direct microscopy, we were unable to culture the pathogenic fungus.

## Conclusions

Even in immunocompetent pediatric patients, one must consider mucormycosis in the differential diagnoses and carry out the appropriate microbiological, pathological, and serological studies to make the correct diagnosis.

## References

1. Pana ZD, Seidel D, Skiada A, Groll AH, Petrikos G, Cornely OA, Roilides E (2016) Invasive mucormycosis in children: an epidemiologic study in European and non-European countries based on two registries. *BMC Infect Dis* 16: 667.
2. Zaoutis TE, Roilides E, Chiou CC, Roden MM, Buchanan WL, Knudsen TA, Sarkisova TA, Schaufele RL, Sein M, Sein T, Prasad PA, Chu JH, Walsh TJ (2007) Zygomycosis in children: a systematic review and analysis of reported cases. *Pediatr Infect Dis J* 26: 723-727.
3. Francis JR, Villanueva P, Bryant P, Blyth CC (2018) Mucormycosis in children: review and recommendations for management. *J Pediatric Infect Dis Soc* 7: 159-164.
4. Prasad PA, Vaughan AM, Zaoutis TE (2012) Trends in zygomycosis in children. *Mycoses* 55: 352-356.
5. Roilides E, Zaoutis TE, Walsh TJ (2009) Invasive zygomycosis in neonates and children. *Clin Microbiol Infect* 15 Suppl 5: 50-54.
6. Bonifaz A, Tirado-Sánchez A, Calderón L, Romero-Cabello R, Kassack J, Ponce RM, Mena C, Stchigel A, Cano J, Guarro J (2014) Mucormycosis in children: a study of 22 cases in a Mexican hospital. *Mycoses* 57 Suppl 3: 79-84.
7. Elinav H, Zimhony O, Cohen MJ, Marcovich AL, Benenson S (2009) Rhinocerebral mucormycosis in patients without predisposing medical conditions: a review of the literature. *Clin Microbiol Infect* 15: 693-697.
8. Korabečná M, Liška V, Fajfrlík K (2003) Primers ITS1, ITS2 and ITS4 detect the intraspecies variability in the internal transcribed spacers and 5.8S rRNA gene region in clinical isolates of fungi. *Folia Microbiol* 48: 233-238.
9. Pozo JC, Pontes A, Pozo C, Robles JC, Linares MJ (2015) Disseminated mucormycosis in immunocompetent patients: a disease that also exists. *Rev Iberoam Micol* 32: 63-70. [Article in Spanish]
10. Singh ND, Sharma N, Dawa L, Malhotra S (2017) *Apophysomyces elegans* caused rhino-orbito mucormycosis: an emerging infection in immunocompetent individuals. *J Microbiol Infect Dis* 7: 207-212.
11. Roden MM, Zaoutis TE, Buchanan WL, Knudsen TA, Sarkisova TA, Schaufele RL, Sein M, Sein T, Chiou CC, Chu JH, Kontoyiannis DP, Walsh TJ (2005) Epidemiology and outcome of zygomycosis: a review of 929 reported cases. *Clin Infect Dis* 41: 634-653.
12. Palacio A, Smiley D, Ceron M, Klein R, Cho IS, Mejía R, Umpierrez GE (2008) Prevalence and clinical outcome of inpatient hyperglycemia in a community pediatric hospital. *J Hosp Med* 3: 212-217.
13. Amanati A, Barzegar H, Pouladfar G, Dashti AS, Abtahi MB, Khademi B, Ashraf MJ, Badiie P, Hamzavi SS, Kashkooe A (2020) Orbital mucormycosis in immunocompetent children; review of risk factors, diagnosis, and treatment approach. *BMC Infect Dis* 20: 770.
14. Dabritz J, Attarbaschi A, Tintelnot K, Kollmar N, Kremens B, v. Loewenich FD, Schrod L, Schuster F, Wintergerst U, Weig M, Lehrnbecher T, Groll AH (2011) Mucormycosis in paediatric patients: demographics, risk factors and outcome of 12 contemporary cases. *Mycoses* 54: e785-e788.

## Corresponding author

Héctor Manuel Prado-Calleros, MD  
Education and Research Department, General Hospital “Dr. Manuel Gea González”, Calzada de Tlalpan 4800, Colonia Sección XVI, Delegación Tlalpan, 14080, México City, México  
Tel: +55-4000-3000  
Fax: +55-4000-8212  
Email: hmpradoc@hotmail.com

**Conflict of interests:** No conflict of interests is declared.