

Case Report

Subacute transverse myelitis as a clinical presentation of neurobrucellosis

Juan José Díaz-Vintimilla¹, Luis Adrián Rosales Hernández¹, Rogelio Zapata-Arenas¹, Sokani Sánchez-Montes^{2,3}, Ingeborg Becker²

¹ General Hospital of Mexico “Dr. Eduardo Liceaga”, Mexico City, Mexico

² National Autonomous University of Mexico, Mexico City, Mexico

³ Veracruzana University, Veracruz, Mexico

Abstract

Brucella melitensis is the main cause of human brucellosis worldwide and is considered the most virulent and neurotropic species. In Mexico, this species is considered endemic, being reported since the first decade of the 20th century. Here we present a case of subacute transverse myelitis with the isolation and identification of *B. melitensis* as the causative agent of Neurobrucellosis in a female patient from the coastal state of Guerrero, Mexico.

Key words: Transverse myelitis; *Brucella melitensis*; neurobrucellosis; case report.

J Infect Dev Ctries 2021; 15(9):1359-1363. doi:10.3855/jidc.14753

(Received 21 January 2021 – Accepted 11 March 2021)

Copyright © 2021 Díaz-Vintimilla *et al.* This is an open-access article distributed under the Creative Commons Attribution License, which permits unrestricted use, distribution, and reproduction in any medium, provided the original work is properly cited.

Introduction

Human brucellosis is the most common zoonotic infection worldwide, Latin America being a high-risk area [1,2]. It is caused by four species of the genus *Brucella* (*Brucella abortus*, *B. melitensis*, *B. canis*, and *B. suis*). This disease is transmitted to humans through direct contact with secretions of infected animals or ingestion of their products, mainly unpasteurized dairy products, or less commonly raw meat. It is a multisystem disease than can simulate other infectious and noninfectious pathologies, mainly affecting the musculoskeletal system [2-5]. However, less than 5% of patients infected by any of the *Brucella* species develop neurologic manifestations [2-5].

Neurobrucellosis may develop at any stage of the disease, with variable manifestations such as meningitis, meningoencephalitis, radiculitis, myelitis, cranial and peripheral nerve palsies, intracerebral and subarachnoid hemorrhage, and psychiatric manifestations [2,3,6,7].

Transverse myelitis is a very unusual presentation of this condition and clinical suspicion requires integration of geographic, alimentary and sanitary risk factors; compatible clinical manifestations, and complementary studies, such as Rose Bengal serum agglutination, 2-mercaptoethanol (2-ME) associated serum agglutination (SAT), polymerase chain reaction (PCR), and bone marrow culture.

We present the case of a 35-year-old woman with subacute myelopathy in whom *B. melitensis* was isolated, with resolution of the symptoms after targeted antimicrobial therapy.

Case report

A 35-year-old woman from the coastal state of Guerrero, Mexico, without previous medical conditions or contact with domestic animals, but a history of unpasteurized cheese consumption, presented with a two-month clinical picture of 39 °C temperature, night sweats, weight loss of 16 kg, and sacrococcygeal pain. Three weeks prior to hospital admission, she started to have lower limb paresthesia and hypoaesthesia, paraparesis, and urinary incontinence.

Neurologic examination revealed an alert and oriented patient, with no cranial nerve involvement. Motor examination showed paraparesis (3/5), lower limb hyperreflexia with sustained ankle clonus, and bilateral Babinski and Chaddock signs. A T8 spinal cord level with loss of all sensory modalities was evidenced. The rest of the examination was unremarkable.

Laboratory studies including complete blood count, serum chemistry, electrolytes, and liver function tests were not relevant, except for a positive serum Rose Bengal agglutination test with 1:640 titers. Serum Erythrocyte Sedimentation Rate (ESR) and C-Reactive Protein (CRP) were within normal limits.

A lumbar puncture was performed with opening pressure of 12 cm of H₂O, clear cerebrospinal fluid (CSF), with 3 cells/mm³ (no predominance), and CSF glucose and protein values of 43 and 56.53 mg/dL (CSF/plasma glucose rate 0.35), respectively. Genomic DNA was extracted using a DNeasy Blood & Tissue kit (Qiagen, Hilden, Germany). To verify the integrity of the DNA, amplification of a 400 bp fragment of the mitochondrial gene cytochrome oxidase subunit I of the host was performed. Polymerase Chain Reaction (PCR) was performed using the primers Bru1F (TGCTAATACCGTATGTGCTT) and Bru1R (TAACCGCGACCGGGATGT) that amplify a 900 bp fragment of the ribosomal 16S-rDNA gene (16S) of *Brucella* (Figure 1). The PCR product was sequenced at Macrogen Inc., Korea and the electropherograms were analyzed using the software Chromas. The sequence was compared with those of references deposited in GenBank using the BLASTn tool. The sequence was

99.8% (830/831 bp) identical to *B. melitensis* strain IMHT4 (GenBank accession no. MT611102.1). Our sequence was deposited in GenBank with the accession no. MT912851. We used the F4 / R2 primers. Additionally, we achieved the characterization of the species by sequencing a fragment of more than 800 bp of the 16S-rDNA gene, which replaces the use of the BruceLadder multiplex that requires a greater number of primers for species typing. Also, adenosine deaminase (ADA) and GeneXpert-RIF assays were performed on the CSF, looking for central nervous system (CNS) tuberculosis, both of which were negative. Additionally, a bone marrow culture sample was drawn which also isolated *B. melitensis*.

Contrast-enhanced spinal magnetic resonance imaging (MRI) revealed hyperintensity and contrast enhancement on T1- and T2-weighted sequences extending from T4 to T9 spinal cord segments (Figure

Figure 1. Molecular identification of *Brucella*. PCR products of the patient’s cerebrospinal fluid 3 and 2 μL, respectively (lines 2 and 3), *Brucella abortus* positive control (line 4), Healthy donor genomic DNA (line 1) and Nuclease-free water as the negative controls (line 5). L = Ladder 100 pb.

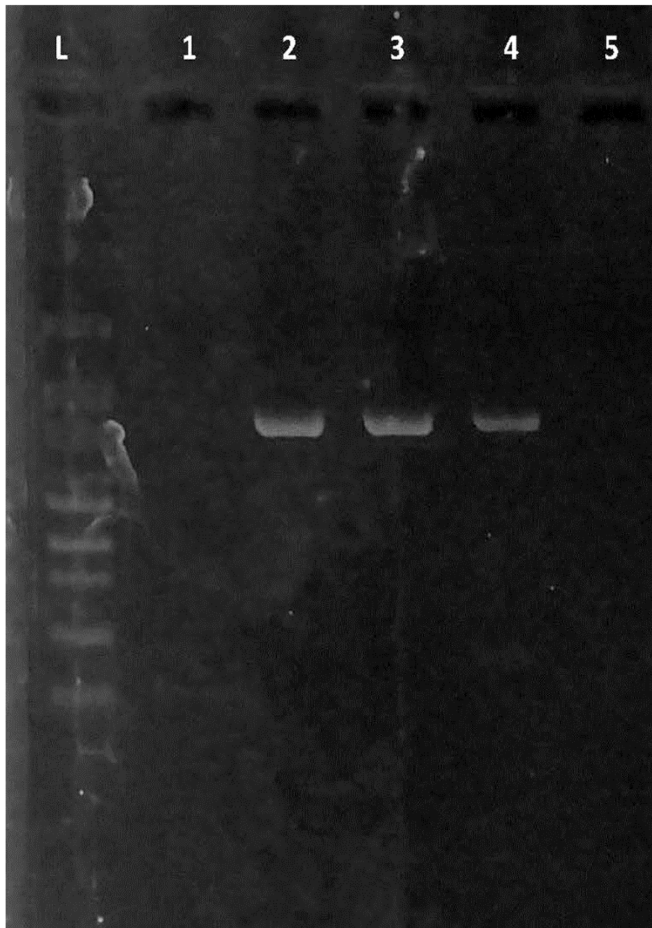
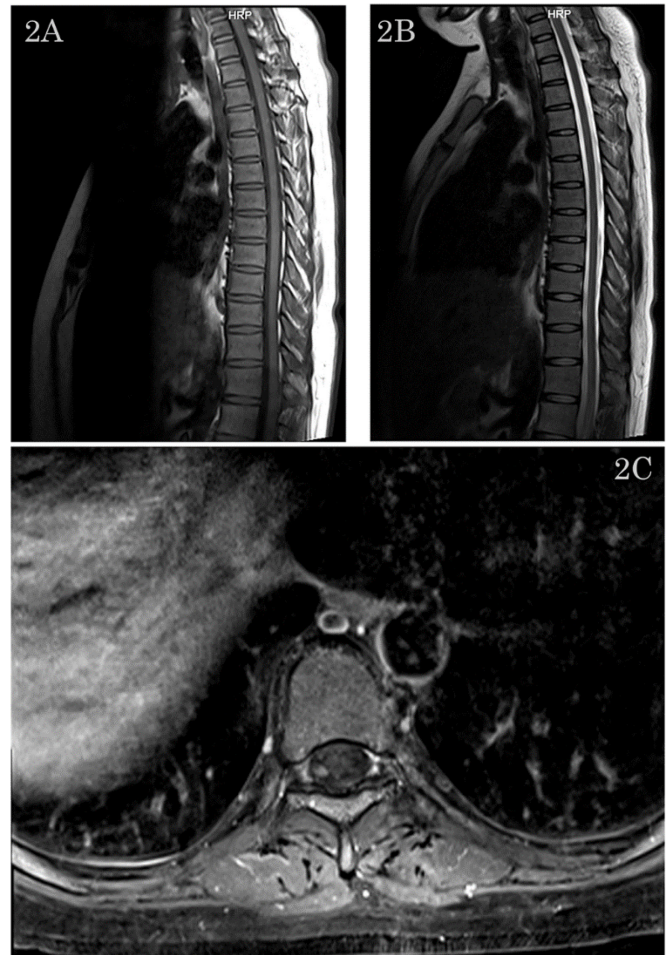


Figure 2. Main findings of neurobrucellosis. Spinal MRI showing increased signal on T1 and T2-weighted sequences extending from T4 to T9 spinal cord segments. A) Sagittal T1-weighted sequence. B) Sagittal T2-weighted sequence. C) Axial T1-weighted sequence.



2A-C). Subacute transverse myelitis was diagnosed in the context of neurobrucellosis and triple antibiotic therapy was started with intravenous ceftriaxone 2 g every 12 hours for one month plus oral doxycycline (100 mg every twelve hours) and rifampin (600 mg once daily) for a total of four months.

Three days after antibiotic therapy was started, the patient's symptoms improved, with complete resolution of the motor and sensory deficits and urinary and fecal incontinence on the sixth and seventh days, respectively.

After completing one month of intravenous treatment with ceftriaxone, the patient was discharged from our service, with subsequent follow-up visits at 15 and 30 days, where notable progress was evident regarding sensory and motor function, with mild lower limb residual paresthesia and 4/5 muscle strength in the left lower limb. No residual urinary or fecal incontinence was seen. The patient continued with oral doxycycline and rifampin up to four months.

Discussion

Brucella melitensis is the main cause of brucellosis worldwide and is considered to be the most virulent species to human beings, given that 10–100 organisms are able to cause chronic infection. Additionally, it is the most neurotropic agent, because nervous system involvement caused by other *Brucella* species is rare. In Mexico, this species is considered endemic, being reported since the first decade of the 20th century, when it was determined that *B. melitensis* was the main causative agent of Malta fever in Mexico [8]. High bacterial loads are present in milk, urine, and products derived from animal pregnancy; human disease is acquired from ingestion of unpasteurized milk and dairy products, and contact with blood and other secretions from infected animals [2,5,8].

Bone marrow culture has sensitivity of 97% during the acute phase, 90% in the subacute phase, and 50% during the chronic phase. It is considered the standard of reference for the diagnosis of *Brucella* infection and it is found to be positive in up to 24–28% of neurobrucellosis cases [5]. In our study, it was possible to recover an axenic culture that could be typified as *B. melitensis*. *Brucella* can also be isolated from other biologic samples such as blood (serum culture positivity is 24–50% for neurobrucellosis), pus, CSF (15–30% by means of culture), and pleural, synovial, and peritoneal fluids [3,6,7,9].

In the absence of cultures, serologic diagnostic tests (such as Rose Bengal, serum agglutination, or Coombs test) and molecular techniques can be used.

Particularly, the amplification of the *bcs31* gene has a sensitivity of 100% and specificity of 98.3%. Other studies improved the amplification of the 16S-rDNA, with variable results that goes from 70–90%. In the present study we were able to successfully amplify and sequence a fragment of ~800 bp of the 16S-rDNA gene from *Brucella* using the set of primers F47R2, which allowed us to corroborate the identity of the infecting species [10,11].

Direct CNS involvement in patients with *Brucella* infection occurs in <5% of adult cases and < 1% of pediatric cases. Regarding acute infection, CNS involvement is nonspecific, with headache, fatigue and myalgia frequently reported. Subacute and chronic neurobrucellosis occurs in less than 10% of cases, with a clinical presentation that includes myelitis, meningoencephalitis, meningomyelitis, optic neuritis, peripheral neuritis, and facial palsy. CSF findings characteristically show lymphocytic pleocytosis, elevated protein count, positive seroagglutination titers, or culture with isolation of *Brucella* spp. [4,9].

Incidence of neurobrucellosis can change depending on the sample size and the epidemiologic findings of different research centers in various countries. Several studies have reported unusual manifestations as the initial presentation such as pseudotumor cerebri, demyelinating syndromes, intracranial granuloma, transverse myelitis, sagittal sinus thrombosis, spinal arachnoiditis, aphasia, hearing loss, and hemiparesis [12].

Diagnosis of neurobrucellosis is based on the following criteria:

- 1- Signs and symptoms of neurological disease in the absence of other diseases.
- 2- CSF analysis with lymphocytic pleocytosis (> 16/mm³); elevated protein content (> 45 mg/dL) and reduced CSF/plasma glucose rate (< 0.50).
- 3- Bacteria isolation from blood and other body fluids.
- 4- Standard tube agglutination (STA) titers positivity in serum and/or cerebrospinal fluid (CSF), or positive Rapid agglutination (RAT), Coombs tests (titers ≥ 1/160) and Wright ≥ 1/160 in serum or any value of titer in CSF obtained by the RAT, Wright or Coombs' tests.
- 5- Response to specific antimicrobial therapy with a significant drop in the CSF lymphocyte count and protein concentration [2,7,9].

The role of imaging studies in the diagnosis of neurobrucellosis is limited because its findings can mimic other inflammatory or infectious conditions.

MRI is superior to computerized tomography (CT) scanning and is indicated in cases of diagnostic doubt, neurologic deterioration, slow improvement, or unusual physical findings [12].

Neurobrucellosis can initially present as longitudinally extensive transverse myelitis [7]. Incidence of acute transverse myelitis is about 1–4 per million population and can present at any age, with a peak between the second and fourth decades [4]. The first case in the literature, reported by Ozer *et al.*, was of a 56-year-old woman with paraparesis and absent deep tendon reflexes [4]; MRI showed diffuse bulging of the L3–L4, L4–L5, and L5–S1 spinal cord segments. Nerve conduction studies were conclusive, with radiculoneuritis and positive serum Rose Bengal; however, no microorganism was isolated from the CSF. Ten days after treatment with ceftriaxone, rifampin and doxycycline was started, the patient showed improvement of paraparesis [4].

Transverse myelitis (TM) is characterized by an interruption of axonal conduction due to an inflammatory process within the spinal cord; it can be part of a systemic disease or present as an isolated condition [13].

Krishnan *et al.* reported a case of a 65-year-old man with headache and hearing loss who developed progressive diplopia and required brain tissue biopsy, with an abscess as a complication of such a procedure, in whom *B. melitensis* was isolated [13].

Treatment of neurobrucellosis represents a problem because of the need to reach therapeutic concentrations of antibiotics in the CSF. Considering that tetracyclines and aminoglycosides do not adequately penetrate the blood–brain barrier, it is recommended to add rifampin and cephalosporins to the standard treatment with doxycycline. Duration of treatment is determined by clinical and CSF response (normal CSF protein, cell count < 100/mm³) and therefore should be continued for three months to one year, usually 6 months [3,4,6,9,14].

Antimicrobial treatment shortens the natural history of the disease, decreases the incidence of complications, and avoids relapses. There is strong evidence that tetracyclines are the drugs of choice for *Brucella* infection. They cause rapid resolution of symptoms, with defervescence occurring around the first 2–7 days depending on clinical presentation [5,8,9,15].

In conclusion, patients with a prolonged febrile illness and neurological manifestations call for careful evaluation of both clinical and epidemiological antecedents. Neurobrucellosis must be considered in

Mexico, once other pathogens, causing nonspecific febrile symptoms, have been ruled out.

References

1. Skalsky K, Yahav D, Bishara J, Pitlik S, Leibovici L, Paul M (2008) Treatment of human brucellosis: systematic review and meta-analysis of randomised controlled trials. *BMJ* 336: 701-704.
2. Dreshaj S, Shala N, Dreshaj G, Ramadani N, Ponosheci A (2016) Clinical manifestations in 82 neurobrucellosis patients from Kosovo. *Mater Sociomed* 28: 408-411.
3. Guven T, Ugurlu K, Ergonul O, Celikbas AK, Gok SE, Comoglu S, Baykam N, Dokuzoguz B (2013) Neurobrucellosis: clinical and diagnostic features. *Clin Infect Dis* 56: 1407-1412.
4. Ozer G, Kutlu G, Inan L (2018) A rare clinical presentation of neurobrucellosis paraparesis: a report of two cases. *Eurasian J Med Oncol* 2: 254-257.
5. Pappas G, Akritidis N, Bosilkovski M, Tsianos E (2005) Brucellosis. *N Engl J Med* 352: 2325-2336.
6. Abid R, Smaoui O, Oueslati I, Hannachi S, Battih R, Louzir B (2018) Neurobrucellosis: an unusual location of brucellosis. *Ann Clin Case Rep* 3: 1525
7. Yamout BI, Massouh J, Hushaymi I, Zeineddine M, Saab G (2020) Neurobrucellosis presenting as longitudinally extensive transverse myelitis: a case report and review of the literature. *Mult Scler Relat Disor* 40: 101947
8. Spink WW (1953) Observations on brucellosis due to *Brucella melitensis*. *Bull World Health Organ* 9: 385-398.
9. Ceran N, Turkoglu R, Erdem I, Inan A, Engin D, Tireli H, Goktas P (2011) Neurobrucellosis: clinical, diagnostic, therapeutic features and outcome. Unusual clinical presentations in an endemic region. *Braz J Infect Dis* 15: 52-59.
10. Zamanian M, Hashemi Tabar GR, Rad M, Haghparast A (2015) Evaluation of different primers for detection of *Brucella* in human and animal serum samples by using PCR method. *Arch Iran Med* 18: 44-50.
11. Garshasbi M, Ramazani A, Sorouri R, Javani S, Moradi S (2014) Molecular detection of *Brucella* species in patients suspicious of brucellosis from Zanjan, Iran. *Braz J Microbiol* 45: 533-538.
12. Ulu-Kilic A, Metan G, Alp E (2013) Clinical presentations and diagnosis of brucellosis. *Recent Pat Antiinfect Drug Discov* 8: 34-41.
13. Krishnan C, Kaplin AI, Graber JS, Darman JS, Kerr DA (2005). Recurrent transverse myelitis following neurobrucellosis: immunologic features and beneficial response to immunosuppression. *Journal Neurovirol* 11: 225-231.
14. Erdem H, Ulu-Kilic A, Kilic S, Karahocagil M, Shehata G, Eren-Tulek N, Yetkin F, Celen MK, Ceran N, Gul HC, Mert G, Tekin-Koruk S, Dizbay M, Inal AS, Nayman-Alpat S, Bosilkovski M, Inan D, Saltoglu N, Abdel-Baky L, Adeva-Bartolome MT, Ceylan B, Sacar S, Turhan V, Yilmaz E, Elaldi N, Kocak-Tufan Z, Ugurlu K, Dokuzoguz B, Yilmaz H, Gundes S, Guner R, Ozgunes N, Ulcay A, Unal S, Dayan S, Gorenek L, Karakas A, Tasova Y, Usluer G, Bayandir Y, Kurtaran B, Sipahi OR, Leblebicioglu, H (2012) Efficacy and tolerability of antibiotic combinations in neurobrucellosis:

results of the Istanbul study. *Antimicrob Agents Chemother* 56: 1523–1528.

15. Solera J (2010) Update on brucellosis: therapeutic challenges. *Int J Antimicrob Agents* 36: S18-S20.

Corresponding author

Díaz-Vintimilla Juan José, MD

General Hospital of Mexico “Dr. Eduardo Liceaga”, Dr. Balmis

148, Col. Doctores, 06726 Ciudad de México, México

Phone: +52-5611-244-277

Fax: +52-55-2789-2000, ext. 1265

Email: juanjose_diazv@hotmail.com

Conflict of interests: No conflict of interests is declared.