

Brief Original Article

Assessment of pathomorphological characteristics of the oral mucosa in patients with HBV, HCV and HIV

Vahe Azatyan¹, Lazar Yessayan¹, Anna Khachatryan², Anush Perikhanyan³, Alvard Hovhannisyan⁴, Melanya Shmavonyan⁴, Hasmik Ghazinyan⁵, Robert Gish⁶, Gayane Melik-Andreasyan⁷, Kristina Porksheyanyan⁸

¹ Department of Therapeutic Stomatology, Yerevan State Medical University (YSMU), Yerevan, Armenia

² Department of Pathological Anatomy, Yerevan State Medical University (YSMU), Yerevan, Armenia

³ Department of Medical Affairs, FMD Contract Research Organization, Yerevan, Armenia

⁴ Department of Infectious Diseases, Yerevan State Medical University (YSMU), Yerevan, Armenia

⁵ Department of Hepatology, Nork Clinical Infectious Hospital (CJSC), Yerevan, Armenia

⁶ Department of Medicine, Stanford University Hospital, Stanford, California, United States

⁷ National Center of Disease Control and Prevention, RA Ministry of Health, Yerevan, Armenia

⁸ Department of Diagnostic Radiology, Yerevan State Medical University (YSMU), Yerevan, Armenia

Abstract

Introduction: Oral clinical manifestations in HBV HCV and HIV patients indicate a deterioration in general health status. The aim of the study was to assess pathomorphologic features of oral mucosa observed in patients with these diseases.

Methodology: The study was conducted in N1 Dental Clinic of YSMU after M. Heratsi. The total number of patients taking part in the research was 120, including HBV (n = 40), HCV (n = 40) and HIV (n = 40). After biopsy and subsequent histological examination of the oral mucosa, statistical analysis was carried out using Excel 2013 and R software.

Results: Pathomorphological examination revealed inflammatory infiltrations in all samples collected from HBV, HCV and HIV patients. These changes included microcirculatory disorders in 98.3% of samples: fibrinous-like deposits lining the surface of erosions and ulcers on the oral mucosa (1.67%), fibrosis of the mucous membrane (70%), dystrophy of squamous epithelium (93.3%) and bone sequestration (3.3%). Comparative analysis of pathomorphological characteristics revealed distinct content of infiltrates: lymphoplasmacytic infiltration in patients with HBV and HCV, while HIV patients showed neutrophils infiltration and lack of plasmocytes.

Conclusions: There are common abnormal morphological changes in the oral mucosa typical of all patients with HBV, HCV and HIV, as well as liver diseases specific to each of them. Inflammation in the patients with HIV indicated impairment of the humoral immune system. Understanding the distinct characteristic of inflammation in the oral cavity could be useful for early differential diagnosis and management of patients with HIV, HBV and HCV.

Key words: Histology; oral mucosa; HBV; HCV; HIV.

J Infect Dev Ctries 2021; 15(11):1761-1765. doi:10.3855/jidc.15062

(Received 20 March 2021 – Accepted 24 May 2021)

Copyright © 2021 Azatyan *et al.* This is an open-access article distributed under the Creative Commons Attribution License, which permits unrestricted use, distribution, and reproduction in any medium, provided the original work is properly cited.

Introduction

The tissues of the oral cavity reflect the person's general health status and often indicate the presence of a systemic disease, since many lesions and diseases occur primarily in the oral cavity [1,2]. In some cases, the symptoms of systemic disease appear in the oral cavity before the disease is seen in other organs [3]. The accurate diagnosis of mucosal lesions, which may present similar clinical manifestations, might be challenging for a dentist and general practitioner and is necessary for monitoring a real morbidity rate of the population. Viruses can affect almost any type of body cells, but the oral mucosa particularly undergoes

significant impairment [4]. Viruses may cause severe oral and orofacial diseases, appear as oral signs of systemic infection and can be transmitted from patients to dental staff [5,6]. Therefore, theoretical knowledge allows doctors to quickly recognize clinical symptoms of viral infections in the oral cavity.

HBV, HCV and HIV infections have been reported as the most dangerous occupational hazard in the dental profession [7-11]. Awareness of the possible transmission routes of infection diseases in dental settings as well as clinical symptoms of infectious disease and histopathological data are crucial to avoid healthcare-associated transmission. Only a few studies

focused on the detailed histopathological and morphological characteristics of the oral cavity lesions associated with these infections. Therefore, the aim of the study was to assess pathomorphological characteristics of the oral mucosa in patients with HBV, HCV and HIV.

Methodology

The material for the morphological studies was tissue samples taken from the oral mucosa and gums. The study engaged the patients who attended Nork Clinical Hospital of Infectious Diseases and “Armenikum” Clinical Center in Yerevan for inpatient treatment in 2017-2018. The age of the patients ranged between 18 and 70. The number of patients with each disease was equal: 40 patients with HBV, HCV and HIV infection, respectively.

The viral nature of hepatitis and HIV was verified by the detection of hepatitis B virus DNA, hepatitis C virus RNA and HIV in the blood serum of the examined subjects. Pathomorphological study of the material obtained from the oral mucosa of patients with HBV, HCV and HIV was conducted to reveal the pathologic changes in the mucous membrane of the mouth. Pieces of tissue were fixed in 10% neutral formalin, and then dehydrated and embedded in paraffin according to standard histological practice. A series of sections 5 µm thick were made from the blocks, and were stained with hematoxylin-eosin and picrofuchsin according to Van Gieson for a general assessment of the condition of the examined tissues [12]. Histological slides were studied with a ZEISS Primo Star trinocular microscope (ZEISS Microscopy, Germany) at 200, 400 and 1000 times magnification (the latter with immersion oil). Microphotographs were taken with a ZEISS Axiocam ERc 5s (ZEISS Microscopy, Germany). Stromal-epithelial relation as well as the severity and nature of the inflammatory reaction were assessed using the method of panoramic microscopy. All clinical symptoms were studied in accordance with the

international standards and World Health Organization (WHO) recommendations.

Statistical analysis

Descriptive analysis was applied for all variables of interest: the differences between the two groups were evaluated using “chi-square” and “Fisher’s exact” test. Analyses were carried out using Excel 2013 and R software.

Ethics

This study was approved for conduct by the Institutional Review Board of Yerevan State Medical University after M. Heratsi. Informed consent was obtained from each participated patient.

Results

In the oral cavity a primary localization of the pathological process was the mucous membrane of the cheeks (55% of patients) and gums (45% of patients). Macroscopically, the oral mucosa in patients with HBV, HCV and HIV was thickened, swollen, grayish-red or red, with the presence of multiple hemorrhages and erosions, alternated with areas of normal mucosa. In the healing process the areas of ulceration turned pink. Based on the results of the microscopy, six groups of major pathomorphological changes in the oral mucosa were distinguished in the patients with HBV, HCV and HIV infection (Table 1).

The results of the histological study revealed that all patients with HBV, HCV and HIV infection show signs of inflammation in the oral mucosa. The presence of severe inflammatory cell infiltration, mainly in the upper layers of the oral mucosa, was revealed in biopsy of specimens from all patients observed. Diffuse inflammatory infiltrate consisted of lymphocytes, plasma cells and polymorphonuclear leucocytes. It indicates the presence of a severe chronic inflammation and the involvement of the immune mechanisms in the pathological process.

Table 1. Main pathomorphological changes in oral mucosa of HBV, HCV and HIV patients.

Patient Groups	Inflammatory infiltration	Circulatory disorders	Fibrinous coating on surface of erosions and ulcers of the mucous membrane	Fibrosis of mucous membrane	Dystrophic changes in squamous epithelium	Bone sequestration
HBV (n = 40)	40 (100%)	38 (95%)	2 (5%)	6 (15%)	36 (90%)	2 (5%)
HCV (n = 40)	40 (100%)	40 (100%)	0	38 (95%)	36 (90%)	2 (5%)
HIV (n = 40)	40 (100%)	40 (100%)	0	40 (100%)	40 (100%)	0
All (N = 120)	120 (100%)	118 (98.3%)	2 (1.67%)	84 (70%)	112 (93.3%)	4 (3.33%)

Figure 1. Acanthosis of squamous epithelium of oral mucosa. Picrofucsin staining according to Van Gieson [12]. X 100.

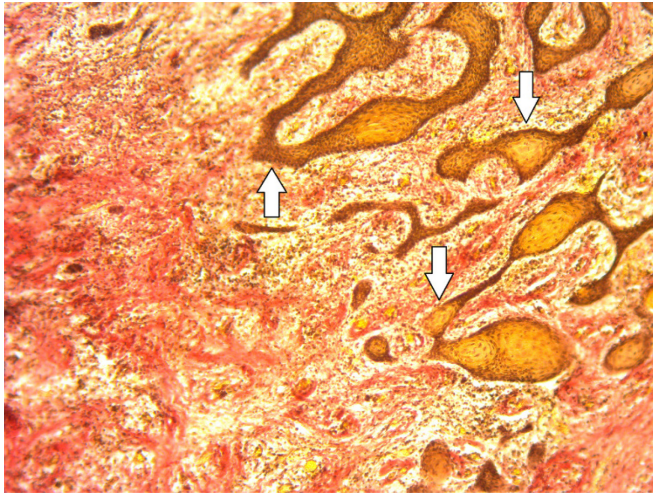


Figure 2. Perinuclear vacuolization of epithelial cells. Hematoxylin and eosin stain. X 400.

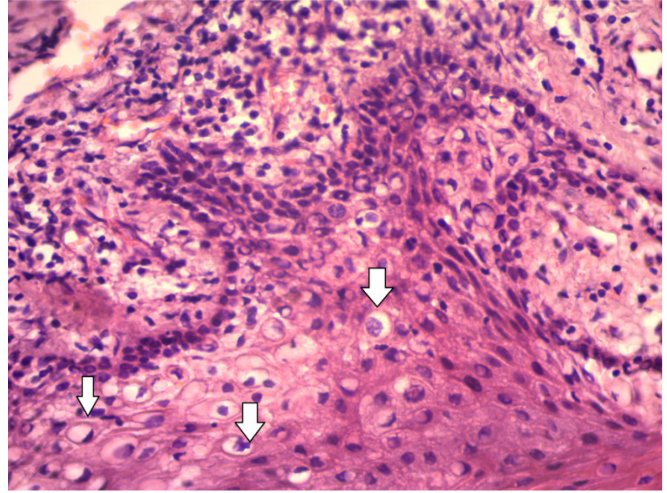


Table 2. Main histopathological characteristics of oral mucosa of HBV patients vs. HIV patients.

Characteristics	Level	HBV (N = 40)	HIV (N = 40)	Odds Ratio / Mean Difference	p value*
Inflammatory infiltration	present	40 (100%)	40 (100%)	-	N/R**
	absent	2 (5%)	0 (0%)	Inf	1
Circulatory disorders	present	38 (95%)	40 (100%)	1	1
Fibrinous coating on the surface of erosions and ulcers of the mucous membrane	absent	38 (95%)	40 (100%)	0	1
	present	2 (5%)	0 (0%)	1	1
Fibrosis of mucous membrane	absent	34 (85%)	0 (0%)	Inf	< 0.001
	present	6 (15%)	40 (100%)	1	< 0.001
Dystrophic changes in squamous epithelium	absent	4 (10%)	0 (0%)	Inf	0.487
	present	36 (90%)	40 (100%)	1	0.487
Bone sequestration	absent	38 (95%)	40 (100%)	0	1
	present	2 (5%)	0 (0%)	1	1
Lymphoplasmocytic infiltration	absent	0 (0%)	36 (90%)	0	< 0.001
	present	40 (100%)	4 (10%)	1	< 0.001
Admixture of neutrophils	absent	24 (60%)	4 (10%)	12.53	0.0022
	present	16 (40%)	36 (90%)	1	0.0022

* p-value: test result in comparison of HBV and HIV groups; ** N/R: No Result.

Table 3. Main histopathological characteristics of oral mucosa of HCV patients vs. HIV patients.

Characteristics	Level	HCV (N = 40)	HIV (N = 40)	Odds Ratio / Mean Difference	p value*
Inflammatory infiltration	present	40 (100%)	0 (0%)	Inf	< 0.001
	absent	0 (0%)	40 (100%)	1	< 0.001
Circulatory disorders	present	40 (100%)	40 (100%)	-	N/R**
Fibrinous coating on the surface of erosions and ulcers of the mucous membrane	present	40 (100%)	40 (100%)	-	N/R**
Fibrosis of mucous membrane	absent	40 (100%)	40 (100%)	-	N/R**
Dystrophic changes of squamous epithelium	absent	2 (5%)	0 (0%)	Inf	1
	present	38 (95%)	40 (100%)	1	1
Bone sequestration	absent	4 (10%)	0 (0%)	Inf	0.487
	present	36 (90%)	40 (100%)	1	0.487
Lymphoplasmocytic infiltration	absent	4 (10%)	36 (90%)	0.02	< 0.001
	present	36 (90%)	4 (10%)	1	< 0.001
Admixture of neutrophils	absent	32 (80%)	4 (10%)	31.32	< 0.001
	present	8 (20%)	36 (90%)	1	< 0.001

* p-value: test result in comparison of HCV and HIV groups; ** N/R: No result.

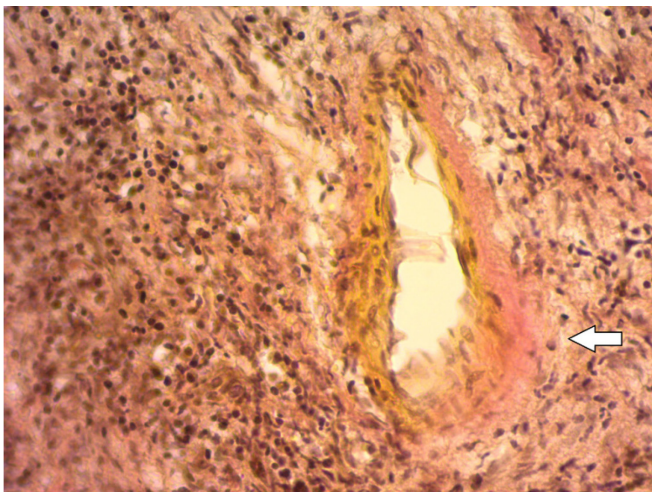
Admixture of neutrophils was revealed at the exacerbation stage. However, while HBV and HCV are characterized by diffuse lymphoplasmacytic infiltration, a lack of plasmocyte in the inflammatory infiltrate in HIV infection is observed (found only in 4 patients), which indicates a depletion of humoral immunity.

The characteristic of inflammation was predominantly productive. The severity of cellular response is an indicator of the immune system activity in relation to cell immune surveillance.

Lymphoid infiltration is also found around unevenly hyperemic areas, on the border of the epithelium with the underlying tissue, and, in some cases, with deep migration of the infiltrate into the epithelium layer. The infiltration rate was moderately to highly diffuse in 75% (n = 30) of patients with HCV and 10% (n = 4) of patients with HIV. Signs of thickening, focal keratinization, epithelial acanthosis, dystrophic changes (hydropic and vacuolar dystrophy) in the cells were observed in the epithelial layer in 90% (n = 36) of patients with HBV and HCV and 100% (n = 40) of patients with HIV (Figures 1 and 2).

Morphological study of the oral mucosa revealed swelling, hyperemia and multiple erosions of irregular shape. Segmented leukocytes predominated in the infiltrate in 40% (n = 16) of patients with HBV, while 20% (n = 8) and 90% (n = 36) of patients with HCV and HIV, respectively. Microscopic examination also revealed damage of the epithelial cells, the appearance of vacuoles in the cytoplasm and desquamation of the epithelium with the formation of micro erosions.

Figure 3. Signs of increased vascular permeability (perivascular edema, lymphoplasmacytic infiltration, loosening of connective tissue), moderate sclerosis of vascular walls in HBV. Picrofuchsin stain according to Van Gieson [12]. X 400.



Erosions or micro ulcers were covered with fibrinous coating in 5% (n = 2) of patients with HBV.

All patients observed had microcirculatory disorders in the form of edema, uneven plethora of blood vessels and focal perivascular lymphoid infiltrates. Circulatory disorders also manifested in the form of edema, hemorrhage of various sizes due to destruction of the vessel walls in HBV and HCV, stagnation of blood in the microvasculature, marginal standing of corpuscular blood elements in venules and capillaries in patients with HBV, HCV and HIV (Figure 3).

Severe microcirculatory disorders, in turn, led to deeper metabolic disorders.

Discussion

There are significant changes in microvasculature caused by HBV, HCV and HIV infections. First, blood circulation disorders aggravate tissue trophism. Second, the high blood vessel density in the regenerating granulation tissue ensures sufficient oxygen supply to stimulate metabolic processes, promotes healing and accelerates a differentiation into coarse fibrous connective tissue.

Tables 2 and 3 illustrate the main histopathological characteristics in patients with HBV, HCV and HIV.

Histological disorders in HBV and HCV were characterized by almost similar changes. The findings in the oral mucosa inflammatory infiltrate of patients with HBV, HCV and HIV are as follows:

- lymphoplasmocytes with an admixture of neutrophils at the stage of exacerbation;
- dystrophic changes in squamous epithelium;
- acanthosis, parakeratosis and thickening of squamous epithelium;
- circulatory disorders (in the form of hemorrhage, edema, angiomas, obliteration of the vascular lumina);
- fibrinous coating on the surface of ulceration and erosion of the mucous membrane and fibrosis of the mucosa membrane in remission.

However, it should be noted that the research was focused on the lesions of the oral mucosa and periodontium in particular for patients with HBV, HCV and HIV, and the available data for a reliable comparative assessment of our study were limited. The scrapes of the lining of the oral cavity taken from the patients with different forms of viral hepatitis were examined. The results of histo-chemical examination proved a marked depression of carbohydrate and protein metabolism, and, also, decrease in immuno-

resistance of the body in patients with HBV and HCV [13,14].

The limited number of the taken samples were due to refusal of the patients of Nork Infectious Diseases Clinical Hospital and the “Armenikum” Clinical Center to get involved in the research.

Conclusions

There are common abnormal morphological changes in the oral mucosa typical of all patients with HBV, HCV and HIV viruses, as well as liver diseases specific to each of them. Inflammation in the patients with HIV indicated impairment of the humoral immune system. Understanding of the distinct characteristic of inflammation in the oral cavity could be useful for early differential diagnosis and management of patients with HIV, HBV and HCV.

Acknowledgements

We thank all the editors for their invaluable editorial assistance in the preparation of this manuscript for publication.

References

- McLean AT, Wheeler EK, Cameron S, Baker D (2012) HIV and dentistry in Australia: clinical and legal issues impacting on dental care. *Aust Dent J* 57: 256-270.
- Gupta K, Metgud R (2013) Evidences suggesting involvement of viruses in oral squamous cell carcinoma. *Patholog Res Int* 2013: 642496.
- Krasteva A, Panov VE, Garova M, Kisselova A, Velikova R, Krastev Z (2008) Hepatitis B and C in dentistry. *J IMAB* 14: 38–40.
- Klevens RM, Moorman AC (2013) Hepatitis C virus: an overview for dental health care providers. *J Am Dent Assoc* 144: 1340–1347.
- Dahiya P, Kamal R, Sharma V, Kaur S (2015) “Hepatitis” - Prevention and management in dental practice. *J Educ Health Promot* 4: 33.
- Yasen A, Herrera R, Rosbe K, Lien K, Tugizov SM (2018) HIV internalization into oral and genital epithelial cells by endocytosis and macropinocytosis leads to viral sequestration in the vesicles. *Virology* 515: 92–107.
- Prabhu A, Rao A, Reddy V, Krishnakumar R, Thayumanavan S, Swathi S (2014) HIV/AIDS knowledge and its implications on dentists. *J Nat Sci Biol Med* 5: 303-307.
- Clarkson E, Mashkoo F, Abdulateef S (2017) Oral viral infections: diagnosis and management. *Dent Clin North Am* 61: 351–363.
- Urse GN (2014) Systemic disease manifestations in the oral cavity. *OPF* 6: 16-21.
- Grinde B, Olsen I (2010) The role of viruses in oral disease. *J Oral Microbiol* 2: 2127.
- Azodo CC, Erhabor P (2015) The roles of viruses in periodontal diseases. *J Dent Res Rev* 2: 37-41.
- Prento P (1993) Van Gieson's picrofuchsin. The staining mechanisms for collagen and cytoplasm, and an examination of the dye diffusion rate model of differential staining. *Histochemistry* 99: 163-174.
- Aznauryan AV, Azatyan VYu, Yessayan LK (2017) Clinical-morphology changes of the oral cavity in HBV and HCV infections. *The New Armenian Medical Journal* 11 Suppl 3: 73.
- Pavan P, Pereira VT, Souza RC, Souza CO, Torres SR, Colombo APV, Costa LJ, Sansone C, Uzeda M, Goncalves LS (2014) Levels of HIV-1 in subgingival biofilm of HIV-infected patients. *J Clin Periodontol* 41: 1061-1068.

Corresponding author

Vahe Azatyan, MD, PhD
 Assistant Professor, Department of Therapeutic Stomatology,
 Yerevan State Medical University, Yerevan, Koryun st.2, Yerevan
 0025, Armenia
 Phone: +374 91326773
 Fax: +374 10547506
 Email: vahe.azatyan@gmail.com

Conflict of interests: No conflict of interests is declared.