

Case Report

Liver abscess after microwave ablation of hepatocellular carcinoma caused by *Clostridium perfringens*

Jiang Guo¹, Changqing Li¹, Xuesong Gao²

¹ Department of Interventional Oncology, Beijing Ditan Hospital, Capital Medical University, Beijing, China

² Department of General Medicine, Beijing Ditan Hospital, Capital Medical University, Beijing, China

Abstract

Clostridium perfringens causes pyogenic liver abscesses, which are rare but rapidly fatal infections. These abscesses often occur in patients with immunodeficiency due to malignancy, liver cirrhosis, diabetes mellitus, or organ transplantation. The identification of gram-positive bacilli in septicemia, the presence of gas-forming liver damage and intravascular hemolysis are manifestations of *Clostridium perfringens* infection. *Clostridioides* toxin A hydrolyzes phospholipids in erythrocyte membranes, causing spherocytosis and subsequent intravascular hemolysis, resulting in rapid deterioration and a high mortality rate. A 62-year-old man with recurrent hepatocellular carcinoma complained of a high fever and abdominal pain one day after microwave ablation. Abdominal computed tomography revealed gas-containing lesions in the liver. His condition was complicated with massive hemolysis. Laboratory examinations revealed low hemoglobin, high serum lactate dehydrogenase, and elevated indirect bilirubin levels, suggesting massive intravascular hemolysis. Although aggressive treatment was applied, he died within 16 hours after onset of the infection. After the patient died, a blood culture indicated *Clostridium perfringens* positivity. *Clostridium perfringens*-induced septicemia with massive hemolysis is rare but rapidly leads to a severe prognosis. It is important to identify *Clostridium perfringens* infection early and initiate effective treatment, especially abscess aspiration, which should be performed as soon as possible.

Key words: Liver infection; *Clostridium perfringens*; hemolysis; hepatocellular carcinoma; microwave ablation.

J Infect Dev Ctries 2022; 16(1):222-225. doi:10.3855/jidc.13756

(Received 24 August 2020 – Accepted 06 August 2021)

Copyright © 2022 Guo *et al.* This is an open-access article distributed under the Creative Commons Attribution License, which permits unrestricted use, distribution, and reproduction in any medium, provided the original work is properly cited.

Introduction

Clostridium perfringens is an anaerobic, gram-positive bacterium that can be isolated from normal gastrointestinal and genital tracts. It may become pathogenic under certain circumstances, including ischemia, neutropenia, thrombocytopenia or direct trauma. *Clostridium perfringens* can cause a wide spectrum of clinical presentations, ranging from asymptomatic bacteremia to shock and death [1-3]. *Clostridium perfringens* infection often occurs in patients with immunodeficiency due to malignancy, liver cirrhosis, diabetes mellitus, or organ transplantation. Although hepatectomy is an important therapeutic option for hepatocellular carcinoma (HCC), many patients with cirrhosis or an intermediate or advanced liver disease stage do not have opportunities for surgical resection. Locoregional therapy, including radiofrequency ablation (RFA), transcatheter arterial chemoembolization (TACE), microwave ablation (MWA), cryoablation and irreversible electroporation, or radioembolization and stereotactic body radiation therapy, may provide radical treatment opportunities

for these patients [4]. MWA is one of the most commonly used thermal ablation methods and creates rapidly oscillating electromagnetic fields, inducing frictional heat and thus coagulative tissue necrosis. During the MWA procedure, the heat increases the temperature of the target lesion in a short time and produces a large ablation zone, thereby reducing the heat sink effect [5]. Therefore, MWA is a rather safe treatment for HCC patients with cirrhosis. Liver abscess rarely occurs as a major complication [6], especially liver abscess with massive intravascular hemolysis due to *Clostridium perfringens* sepsis. Although this complication is rare, it has a particularly rapid fatal clinical course [7]. This report presents a case of liver abscess with intravascular hemolysis secondary to *Clostridium perfringens* sepsis in an HCC patient after MWA.

Case report

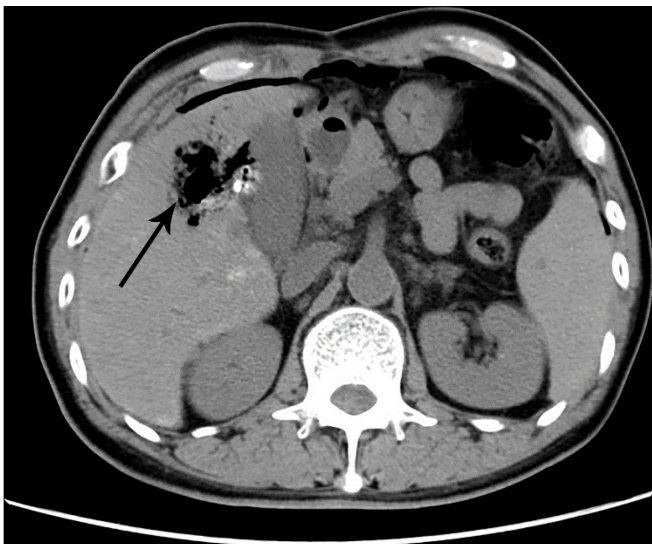
A 62-year-old man was admitted for HCC recurrence. He had hepatitis B virus (HBV)-related cirrhosis and had undergone left lateral segmentectomy

3 years prior. His past medical history was unremarkable, and he had a normal alpha-fetoprotein level (1.9 ng/mL). Abdominal ultrasonography showed one hypoechoic mass in the right lobe of the liver. Computed tomography (CT) revealed one liver tumor (segment V, 50 mm × 30 mm) showing arterial enhancement and venous-phase washout, indicating BCLC A stage HCC.

The patient initially underwent TACE therapy with epirubicin in lipiodol. One week after TACE, he underwent additional treatment with MWA. Ablation was performed at 55 W for 5 min (single-needle superimposed ablation) at the lesion site in segment V. One day after MWA, the patient had a high fever (41.2 °C) with shivering and nausea. He complained of middle abdominal pain most prominently in the right upper quadrant. On examination, he had a heart rate of 100 beats/minute and blood pressure of 120/70 mmHg. The abdomen was soft, nontender, and nondistended. No percussion or rebound tenderness was elicited. His white blood cell count was $3.06 \times 10^9/L$ with 84.21% neutrophils. His hematocrit was 39.6%, and his hemoglobin level was 137 g/L. The procalcitonin level (0.18 ng/mL) was slightly elevated. Aspirin/lysine and intravenous cefuroxime were administered. His condition deteriorated rapidly over 4 hours, and he presented with gastrointestinal symptoms accompanied by severe pain in the liver. Blood tests showed a dramatically elevated white blood cell count ($27 \times 10^9/L$, with 79.74% neutrophils) and procalcitonin level (33.58 ng/mL) and decreased hemoglobin level (77.4 g/L). A liver test showed the following: alanine aminotransferase (ALT)

212.2 U/L, aspartate aminotransferase (AST) 640.1 U/L, total bilirubin (TBIL) 71.6 $\mu\text{mol/L}$, and direct bilirubin (DBIL) 22 $\mu\text{mol/L}$. Abdominal CT revealed abundant air bubbles in the liver and free intraperitoneal gas (Figure 1) as well as a gas-forming pyogenic liver abscess (GPLA). Antibiotic treatment was switched to a combination of meropenem and vancomycin. During the next 5 hours, the patient appeared unwell, severely jaundiced, and extremely restless. Significant laboratory test results consisted of a white blood cell count of $25.00 \times 10^9/L$, with 66.54% neutrophils, hemoglobin level of 56.4 g/L, platelet count of $54.40 \times 10^9/L$, and lactate dehydrogenase (LDH) level of 7519 U/L (normal range, 120–250 U/L). His blood sample was reported by the laboratory as hemolyzed. Arterial blood gas analysis revealed respiratory failure and metabolic acidosis (pH, 7.339; partial pressure of arterial carbon dioxide, 32.6 mmHg; partial pressure of arterial oxygen, 41.4 mmHg; standard bicarbonate, 18 mmol/L; actual bicarbonate, 17.10 mmol/L; base excess, -7.9 mmol/L). A urinalysis showed the following results: protein 5+, occult blood 3+, bilirubin 1+, urobilinogen 1+, and negative urinary red blood cells. His condition was too unstable for drainage of the hepatic abscess. The patient gradually lost consciousness, and he was transferred to the intensive care unit. However, he died within 3 hours following unsuccessful cardiopulmonary resuscitation. Following his death, the blood culture results were reported. After the culture result of blood stored in an anaerobic bottle was positive, the sample was used to cultivate anaerobic bacteria on blood agar using the GENbag anaerobic system (BioMérieux, Marcy l'Etoile, France). The bacteria were identified as *Clostridium perfringens* by mass spectrometry.

Figure 1. Computed tomography showing a gas-forming liver abscess in the right lobe of the liver (arrow).



Discussion

Biliary tract disease is the most common identifiable cause of liver abscess. Portal vein or hepatic artery seeding accounts for an increasing number of liver abscess cases. *Escherichia coli* is the most commonly isolated organism, followed by *Klebsiella pneumoniae*, *Enterococcus*, *Streptococcus* species and *Staphylococcus aureus* in Western countries. The K1 and K2 serotypes of *Klebsiella pneumoniae* have emerged as the most common causes of pyogenic liver abscess (PLA) in much of Asia [8]. GPLA due to *Clostridium perfringens* is a rare complication that can easily lead to the development of sepsis and hemolysis, resulting in an extremely high mortality rate. To the best of our knowledge, only one case of GPLA due to *Clostridium perfringens* and sepsis secondary to MWA

has been reported in the literature to date [9]. In our case, the GPLA due to *Clostridium perfringens* caused very rapid deterioration, including sepsis, massive intravascular hemolysis, and rapid progression to death.

Initially, the patient's nonspecific symptoms, such as fever and abdominal pain, mimicked post-ablation syndrome. Because the laboratory tests showed increased indirect bilirubin and anemia, we prescribed antibiotics; however, cefuroxime monotherapy was ineffective. A previous study found that a regimen of penicillin and clindamycin was associated with a significantly reduced relative risk of death. These data suggested that the combination of penicillin and clindamycin is superior to monotherapy with either drug alone [10]. Although the blood culture result is vital for diagnosis, it does not seem to be helpful for timely alteration of antibiotic treatment. The appearance of an air-containing cavity in the right hepatic lobe with a hepatic abscess on imaging was a reliable indicator for clinical diagnosis. The combination of sepsis and a hemolyzed blood specimen should prompt consideration of *in vivo* hemolysis [11]. When suspecting *Clostridium perfringens* sepsis, the immediate administration of sensitive antibiotics is crucial because the disease progression is rapid. The median time to death from *Clostridium perfringens* bacteremia has been reported to be approximately 9.7 hours (range, 0-96 hours), and the mortality rate following hemolysis ranges from 70% to 100% [10,12]. The pyogenic abscess in this patient may have developed from the liquefactive necrosis of tumor tissue after MWA, and the bacterial infection may have passed through the biliary tree and gastrointestinal tract into the necrotic tumor [13]. Additionally, MWA-induced hepatic ischemia and hypoxia would provide a relatively acidic and hypoxic environment for anaerobe growth. Furthermore, disruption of the gastrointestinal barrier secondary to HCC is one of the most common risk factors for *Clostridium perfringens* bacteremia and hemolysis. Although our patient died, this case illustrates that cirrhosis and HCC patients with GPLA and massive hemolysis are at risk of *Clostridium perfringens* infection.

Conclusions

Clostridium perfringens can cause severe infection and intravascular hemolysis, which rapidly lead to disseminated intravascular coagulation, multiple organ failure and death. Medical practitioners should be aware of GPLA caused by *Clostridium perfringens* after MWA. Due to the rapid deterioration of the patient's condition, the therapeutic window for antibiotic and/or

surgical treatment is extremely narrow. Rapid diagnosis and treatment with appropriate antibiotics are fundamental for patient survival.

Authors' contributions

Study conception and design: Xuesong Gao and Jiang Guo; Data acquisition: Jiang Guo and Changqing Li.

Funding

This work was supported by Health Development and Scientific Research in the capital (2018-1-2181), and Sample Library Program of Beijing Ditan Hospital (201901).

References

1. Kapoor JR, Monteiro B, Tanoue L, Siegel MD (2007) Massive intravascular hemolysis and a rapidly fatal outcome. *Chest* 132: 2016-2019.
2. Shibazaki S, Yasumoto T, Nakaizumi T (2018) Massive intravascular haemolysis due to *Clostridium perfringens*. *BMJ Case Rep* 2018: bcr2017223464.
3. Rechner PM, Agger WA, Mruz K, Cogbill TH (2001) Clinical features of clostridial bacteremia: a review from a rural area. *Clin Infect Dis* 33: 349-353.
4. Llovet JM, De Baere T, Kulik L, Haber PK, Gretten TF, Meyer T, Lencioni R (2021) Locoregional therapies in the era of molecular and immune treatments for hepatocellular carcinoma. *Nat Rev Gastroenterol Hepatol* 18: 293-313.
5. Gaia S, Ciruolo M, Ribaldone DG, Rolle E, Migliore E, Mosso E, Vola S, Rizzo A, Fagoonee S, Saracco GM, Carucci P (2021) Higher Efficiency of Percutaneous Microwave (MWA) Than Radiofrequency Ablation (RFA) in Achieving Complete Response in Cirrhotic Patients with Early Hepatocellular Carcinoma. *Curr Oncol* 28: 1034-1044.
6. Xu Y, Shen Q, Liu P, Xu Z, Wu P, Lu Z, Chen Y, Huang B, Qian G (2017) Microwave ablation for the treatment of hepatocellular carcinoma that met up-to-seven criteria: feasibility, local efficacy and long-term outcomes. *Eur Radiol* 27: 3877-3887.
7. Fujita H, Nishimura S, Kurosawa S, Akiya I, Nakamura-Uchiyama F, Ohnishi K (2010) Clinical and epidemiological features of *Clostridium perfringens* bacteremia: a review of 18 cases over 8 year-period in a tertiary care center in metropolitan Tokyo area in Japan. *Intern Med* 49: 2433-2437.
8. Longworth S, Han J (2015) Pyogenic liver abscess. *Clin Liver Dis* 6: 51-54.
9. Kyang LS, Bin Traiki TA, Alzahrani NA, Morris DL (2016) Microwave ablation of liver metastasis complicated by *Clostridium perfringens* gas-forming pyogenic liver abscess (GPLA) in a patient with past gastrectomy. *Int J Surg Case Rep* 27: 32-35.
10. Simon TG, Bradley J, Jones A, Carino G (2014) Massive intravascular hemolysis from *Clostridium perfringens* septicemia: a review. *J Intensive Care Med* 29: 327-333.
11. Geha RM, Dhaliwal G, Winston LG, Kickler TS, Manesh R (2018) Overcoming the Barrier. *N Eng J Med* 379: 2256-2261.
12. Kurasawa M, Nishikido T, Koike J, Tominaga S, Tamemoto H (2014) Gas-forming liver abscess associated with rapid hemolysis in a diabetic patient. *World J Diabetes* 5: 224-229.

13. Son DJ, Hong JY, Kim KH, Jeong YH, Myung DS, Cho SB, Lee WS, Kang YJ, Kim JW, Joo YE (2018) Liver abscess caused by *Clostridium haemolyticum* infection after transarterial chemoembolization for hepatocellular carcinoma: a case report. *Medicine* 97: e0688.

Corresponding author

Xuesong Gao, PhD.

Department of General Medicine, Beijing Ditan Hospital, Capital Medical University, No.8 Jingshun East Road, Chaoyang District, 100015, Beijing, China

Phone: +8613718689825

Fax: +861084322146

Email: gaoxuesong@ccmu.edu.cn

Conflict of interests: No conflict of interests is declared.