

Case Report

An atypical urticaria case caused by *Giardia intestinalis*

Duygu Yildiz Ozkaya¹, Ozgur Kartal², Fikriye Kalkan²

¹ Division of Internal Medicine, Ankara Gulhane Training and Research Hospital, Ankara, Turkey

² Division of Allergy and Immunology, Ankara Gulhane Training and Research Hospital, Ankara, Turkey

Abstract

Introduction: *Giardia intestinalis* causes diarrhea and malabsorption, especially in developed countries. Although it primarily affects the gastrointestinal system, on rare occasions it causes allergic symptoms such as itching, urticaria, and eczema. Here we describe the case of a 19-year-old man with no past medical history who presented to our hospital with an atypical urticarial rash.

Diagnosis: The only abnormal result in laboratory findings of stool parasitology was *G. intestinalis*. The patient was diagnosed with urticaria due to giardiasis.

Intervention and outcomes: The patient was prescribed Bilastine tablet 20 mg 1 × 1 and referred to the Infectious Diseases Department for treatment. Co-Trimoxazole 400 mg/80 mg tablets 2 × 1 and Metronidazole 500 mg tablets 3 × 1 were prescribed. The urticaria had disappeared at the follow-up visit. The patient confirmed that urticarial symptoms did not recur.

Conclusions: Despite their rarity, *Giardia* and other parasite infections can cause allergic symptoms. Parasitic factors should be considered in patients, especially those living in the communal areas, who present with treatment-resistant urticaria.

Key words: urticaria; parasitic diseases; giardiasis.

J Infect Dev Ctries 2022; 16(11):1781-1783. doi:10.3855/jidc.17177

(Received 29 July 2022 – Accepted 12 September 2022)

Copyright © 2022 Yildiz Ozkaya *et al.* This is an open-access article distributed under the Creative Commons Attribution License, which permits unrestricted use, distribution, and reproduction in any medium, provided the original work is properly cited.

Introduction

Giardia intestinalis is a parasite that causes acute or chronic diarrhea. The parasite is transmitted via the fecal-oral route, often through contaminated water, food, and person-to-person transmission. Those at risk are kindergarten children, childcare workers, those traveling to endemic areas, and those living in communal areas. Immunodeficiency, cystic fibrosis, and oral-anal sexual intercourse are among the risk factors [1]. Cutaneous manifestation is rare; if it occurs, it presents as allergic symptoms such as urticaria, eczema, and pruritus. On occasion, it may present as chronic anal eczema. Patients with asymptomatic infection of *G. intestinalis* may present to a physician with unexplained chronic itching and urticaria. After the treatment of asymptomatic intestinal *Giardia* infection with metronidazole and tinidazole, it was observed that the skin findings including urticaria were improved [2].

Here we report a case of atypical urticaria that started with measles-like rashes related to giardiasis. This report aims to shed light on allergic conditions caused by parasitosis.

Case Report

A 19-year-old male patient, doing his military service, visited the allergy and immunology outpatient clinic with the complaint of a measles-like rash in the forearm volar aspect that faded with pressure. The rashes appeared on the body for the first time one month ago. They were not accompanied by itching and disappeared spontaneously. The rashes were repeated a week ago. At first, there were spot measles-like rashes (Figure 1A), and then the reddish areas started to swell (Figure 1B).

When the rashes first appeared, the patient visited the emergency room and received an IV medication and his symptoms regressed after the treatment. The patient was unable to remember the name of the IV medication. The patient applied to our outpatient clinic after his rashes recurred.

Skin rashes were observed on physical examination and they faded with pressure on the volar face of the forearm. There was no accompanying itching or swelling. There were no rales or rhonchi in the lung. Uvula edema was not observed. During anamnesis, he stated that there were no concomitant chronic diseases and regular medication. He was a smoker and consumed alcohol.

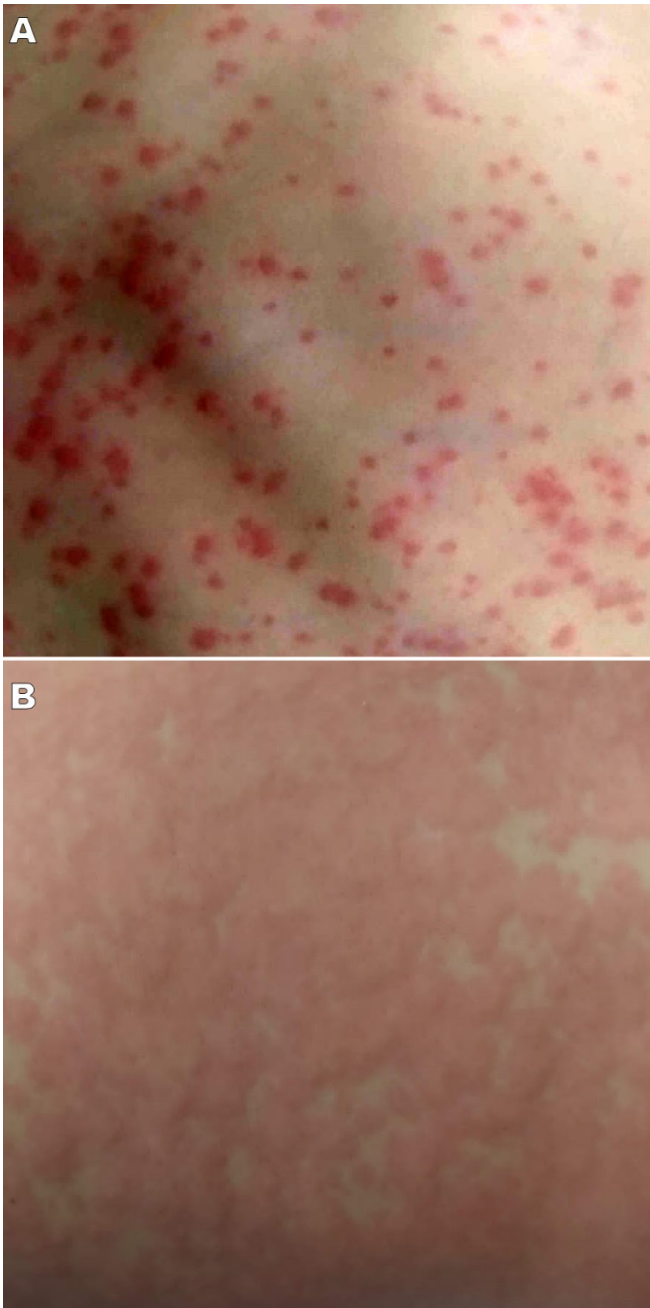
Complete blood count, biochemistry (B12, ferritin, thyroid function tests), stool parasitology, complete urinalysis, and hepatitis markers were ordered. Bilastine tablet 1 × 20 mg was prescribed as a treatment for the rash compatible with urticaria.

Upon reviewing the results of the laboratory tests, the only abnormal finding was *G. intestinalis* in stool parasitology. The patient did not describe abdominal pain, diarrhea, or weight loss. He was diagnosed with urticaria due to giardiasis and referred to the infectious

diseases department for the management of his treatment. Co-Trimoxazole 400 mg/80 mg tablet 2 × 1 and Metronidazole 500 mg tablet 3 × 1 treatment was started by the infectious diseases department.

After one week of treatment, *G. intestinalis* was no longer found in control stool parasitology and the treatment was terminated. During the follow-up visit one month later, the patient confirmed that his urticaria complaints disappeared without the need for antihistamine treatment that was prescribed to him.

Figure 1. The patient first had measles-like rashes (A), three days later, the rashes began to swell as typical urticarial lesions (B).



Discussion

Giardia infection has a prevalence of between 2% and 7% in developed countries. More than 300 million cases are been reported annually worldwide [3,4]. It damages enterocytes and epithelial cells in the small intestine, resulting in the shortening of microvilli and the epithelial barrier function is impaired. This results in watery diarrhea, steatorrhea, nausea and vomiting, abdominal pain, and weight loss [5].

During *Giardia* and other parasitic infections, Th2 and IgE production is activated by the host immune response. Mast cell degranulation and eosinophilia occur. Eosinophils facilitate the subcutaneous migration of parasites by penetrating the skin barriers. Activation of this Th2 mechanism in the host is considered to be the cause of urticaria and other allergic symptoms [6]. In a study on children, it was observed that *Giardia* infection increased the total serum IgE level and IgE response to common allergens [7,8]. In addition to urticaria, Giardiasis can lead to complications such as atopic dermatitis, sensitivity to food antigens, and angioedema [1].

The lifetime prevalence of urticaria is 9%. Urticaria that lasts less than 6 weeks is defined as acute, and when it lasts longer than 6 weeks it is defined as chronic. It may present with rash, angioedema, or both. Itchy erythematous swellings that fade with pressing are indicative of vasodilation and superficial dermal edema and are the main feature of the urticarial bumps. Itching is caused by the release of histamine. The most known triggering condition is upper respiratory tract infections (40%). This is followed by drug reactions (9.2%) and food intolerance (0.9%). While upper respiratory tract pathogens, *Mycoplasma pneumonia*, and parasitic infections are frequently reported among infectious agents in children, viral hepatitis and infectious mononucleosis are the most common causes of urticaria in adults [9].

Conclusions

The presence of parasitosis should be considered in cases of resistant urticaria with an atypical course in which there is no adequate response to standard antihistamine treatments, especially in the case of people living in communal environments (soldiers, students, etc.).

References

1. Leung AKC, Leung AAM, Wong AHC, Sergi CM, Kam JKM (2019) Giardiasis: an overview. *Recent Pat Inflamm Allergy Drug Discov* 13: 134 – 143.
2. Nenoff P, Domula E, Willing U, Herrmann J (2006) *Giardia lamblia* — cause of urticaria and pruritus or accidental association? *Der Hautarzt* 57: 518–522.
3. Dixon BR (2021) *Giardia duodenalis* in humans and animals - transmission and disease. *Res Vet Sci* 135: 283-289.
4. Lanata CF, Fischer-Walker CL, Olascoaga AC, Torres CX, Aryee MJ, Black RE (2013) Global causes of diarrheal disease mortality in children < 5 years of age: a systematic review. *PLoS One* 8: e72788.
5. Vivancos V, González-Alvarez I, Bermejo M, Gonzalez-Alvarez M (2018) Giardiasis: characteristics, pathogenesis and new insights about treatment. *Curr Top Med Chem* 18: 1287-1303.

6. Bakiria AH, Mingomataja EC (2010) Parasites induced skin allergy: a strategic manipulation of the host immunity. *J Clin Med Res* 2: 247-255.
7. Halliez MCM, Buret AG (2013) Extra-intestinal and long-term consequences of *Giardia duodenalis* infections. *World J Gastroenterol* 19: 8974–8985.
8. Di Prisco MC, Hagel I, Lynch NR, Jiménez JC, Rojas R, Gil M, Mata E (1998) Association between giardiasis and allergy. *Ann Allergy Asthma Immunol* 81: 261–265.
9. Antia C, Baquerizo K, Korman A, Bernstein JA, Alikhan A (2018) Urticaria: a comprehensive review, epidemiology, diagnosis, and work-up. *J Am Acad Dermatol* 79: 599-614.

Corresponding author

Duygu Yıldız Ozkaya, MD
Division of Internal Medicine, Ankara Gulhane Training and Research Hospital,
General Dr. Tevfik Sağlam cd. No:1 Etlik/Ankara/Turkey. Postal Code: 06010
Tel: Work (+90)312 304 4007; Mobile (+90)5514026615
Fax: (0 312) 304 27 00
E-mail: md.duyguyildiz@gmail.com

Conflict of interests: No conflict of interests is declared.