

## Coronavirus Pandemic

# Cryptococcal meningitis post-COVID-19 infection: Immunomodulation, a double-edged sword

Hilal W Abdessamad<sup>1</sup>, Michel Achkar<sup>2</sup>, Amal Al Zoghbi<sup>3</sup>, Mohamad Fleifel<sup>2</sup>, Abdul Rahman Ousta<sup>4</sup>, Ahmad Kassar<sup>4</sup>, Nadia L Samaha<sup>5</sup>, Rita Nemr<sup>3</sup>, Anna Farra<sup>1</sup>, Jacques E Mokhbat<sup>1</sup>, Rola Husni<sup>1</sup>

<sup>1</sup> Infectious Diseases, Lebanese American University School of Medicine and Lebanese American University Medical Center–Rizk Hospital, Beirut, Lebanon

<sup>2</sup> Internal Medicine, Lebanese American University School of Medicine and Lebanese American University Medical Center–Rizk Hospital, Beirut, Lebanon

<sup>3</sup> Endocrinology, Lebanese American University School of Medicine and Lebanese American University Medical Center–Rizk Hospital, Beirut, Lebanon

<sup>4</sup> Lebanese American University School of Medicine and Lebanese American University Medical Center–Rizk Hospital, Beirut, Lebanon

<sup>5</sup> Georgetown University School of Medicine, Washington DC, United States

### Abstract

Cryptococcal meningitis is an opportunistic infection associated with altered immunity. Immunomodulatory agent use in severe coronavirus disease 2019 (COVID-19) may predispose such infections. Here, we present a 75-year-old male patient who presented with fever and altered general status after severe COVID-19 infection and developed cryptococcal meningitis. Opportunistic infection may arise from the use of immunomodulation in severe COVID-19, especially in the elderly population. This article describes the case and extensively reviews cryptococcal disease post-COVID-19 literature, highlighting the risk from immunosuppressive treatment.

**Key words:** cryptococcus; meningitis; immunomodulation; COVID-19.

*J Infect Dev Ctries* 2023; 17(5):623-630. doi:10.3855/jidc.17170

(Received 28 July 2022 – Accepted 07 December 2022)

Copyright © 2023 Abdessamad *et al.* This is an open-access article distributed under the Creative Commons Attribution License, which permits unrestricted use, distribution, and reproduction in any medium, provided the original work is properly cited.

### Introduction

Cryptococcal meningitis is a rare infection that mostly occurs in severely immunocompromised patients. According to the Centers for Disease Control, approximately 220,000 cryptococcal meningitis cases occur worldwide each year. This infection was associated with cerebrovascular infarcts [1-4], and a few case reports revealed an association with central diabetes insipidus (DI) [5-10]. More recently, a few studies on cryptococcal meningitis after steroid and tocilizumab use were reported in patients with coronavirus disease 2019 (COVID-19) [1,11]. The co-occurrence of cryptococcal meningitis, cerebral infarcts, and central DI in post-COVID-19 patients is poorly understood and not well documented in the literature [12-15]. Hence, we describe a case and summarize similar published cases to better understand this infection because the induced immunosuppression causes this serious infection, which should be avoided in future patients.

### Patient Presentation

A 74-year-old male patient unvaccinated for COVID-19 presented to our institution on July 14, 2021, with fever and right upper quadrant abdominal and epigastric pain. The patient's complaint began 1 month before the presentation and was reported to worsen with food intake. He was subsequently diagnosed with acute acalculous cholecystitis, but a cholecystectomy was not performed due to his high-risk status for general anesthesia because of COVID-19-induced lung fibrosis. He was previously treated with oral amoxicillin/clavulanic acid at 1 g twice daily and ciprofloxacin at 500 mg twice daily. The patient was symptom-free for 3 weeks; however, his symptoms recurred 1 week before his presentation and admission at our institution.

His past medical history includes hypertension, depression, and a severe COVID-19 infection 3 months before his presentation. He was treated for COVID-19

at a different hospital where he was admitted to the intensive care unit for 45 days without intubation. His admission was complicated by pulmonary fibrosis and dependence on 4 L/min of oxygen via a nasal cannula. He was given 6 mg of dexamethasone daily, then switched to 40 mg of prednisone daily, tapered by decreasing the dose by 5 mg every 3 days, until he remained on 5 mg of prednisone daily for a total of 60 days. The patient also received three doses of 800 mg of intravenous (IV) tocilizumab; one 800mg IV dose every 2 weeks, from April to May 2021. Daily home medications included amlodipine at 5 mg, nebivolol at 5 mg, mirtazapine at 15 mg, and inhaled ipratropium bromide.

His vital signs recorded a temperature of 39 °C, blood pressure of 110/70 mmHg, and a heart rate of 95 beats per minute. He was slow but oriented to person, time, and place. He had dry, pale skin and dry mucosal membranes. His chest exam revealed diffuse rhonchi and bibasilar crackles. Regular S1 and S2 with a systolic ejection murmur (grade I/VI) at the left sternal border were heard on cardiac auscultation. His abdominal exam showed epigastric and right upper quadrant tenderness with a positive Murphy's sign and normal bowel sounds. No signs of distention or costovertebral angle tenderness were observed, and he had a negative McBurney sign. Lower limb pulses were present without notable edema.

The initial laboratory workup showed a white blood cell count of 7,590/microliter with 76% of neutrophils, 11 mg/dL of hemoglobin, 84.6 fL of mean corpuscular volume, 270,000/microliter of platelet, 0.47 mg/dL of creatinine, 15 U/L of serum glutamic-oxaloacetic transaminase, 7 U/L of serum glutamic pyruvic transaminase, 33 U/L of the gamma-glutamyl transferase, 47 U/L of alkaline phosphatase, 31 U/L of lipase, and 7.4 mg/dL of C-reactive protein. Hepatobiliary ultrasound upon admission revealed a distended gall bladder of 10 × 5 cm with a 3-mm wall thickening and decreasing pericholecystic fluid compared to the imaging performed on June 28, 2021.

The patient was admitted and started on IV meropenem at 1 g every 8 hours with a plan for laparoscopic cholecystectomy. His fever resolved after 1 week. However, his neurological status worsened over the few days with tremors in all limbs and vertigo. He was started on carbidopa/levodopa at 25/100 mg daily for his parkinsonian tremors. A brain magnetic resonance imaging (MRI) performed on July 19, 2021, revealed multiple ischemic foci, one at the left centrum ovale and others at the periventricular white matter adjacent to the occipital horns bilaterally, and the left

occipital lobe, showing a high DWI signal and a high T2/fluid-attenuated inversion recovery (FLAIR) signal, with only one focus seen within the left occipital lobe restricting diffusion, denoting its acute component concerning the other subacute/chronic ones (> 10 days). The patient was started on apixaban at 2.5 mg twice daily, and the surgery was postponed. Echocardiography on July 20, 2021, revealed no intracardiac thrombi and normal cardiac function. Carotid echo-doppler studies on July 21, 2021, revealed no carotid stenosis and no plaques. The patient became febrile again after 1 week. Blood and urine cultures remained negative. Vancomycin at 15 mg/kg post-loading dose every 12 h and micafungin at 100 mg daily were added empirically. The fever recurred on July 23, 2021. Meropenem was changed to ceftazidime/avibactam at 2/0.5 g three times daily. The cholecystostomy was finally performed on July 28, 2021, after which the fever resolved completely.

However, the patient's mental status continued to deteriorate for 1 week. He developed an altered sensorium, as well as decreased movement coordination. He showed no focal neurological deficits and no neck stiffness. A new brain MRI on August 19, 2021, revealed a punctate focus of diffusion restriction at the posterior limb of the right internal capsule showing an isointense signal on Analog to Digital Converter (pseudo normalization) with high signal intensity on T2/FLAIR, likely attributed to a subacute lacunar infarct at this level. Mirtazapine and carbidopa/levodopa doses were increased from 15 mg daily to 30 mg and from 100 mg every 8 h to 250 mg every 8 h, respectively. A lumbar puncture was performed on August 5, 2021, which revealed normal opening pressure and clear cerebrospinal fluid (CSF). Cell analysis showed red and white blood cells of 15/mm<sup>3</sup> and 45/mm<sup>3</sup>, respectively; 7% were neutrophils and 93% were lymphocytes. The CSF glucose, protein, and lactate dehydrogenase levels were 42 mg/dL, 90 mg/dL, and 22 U/L, respectively. His blood glucose was 156 mg/dL. IV acyclovir at 750 mg every 8 h and oral fluconazole at 400 mg daily were empirically started (IV fluconazole was not available in Lebanon). The patient showed minimal improvement.

The fever recurred on August 8, 2021, and all cultures taken from blood, urine, and stool, as well as from the cholecystostomy tube, showed no growth. The patient was scheduled for a laparoscopic cholecystectomy, which was performed on August 9, 2021, showing a gangrenous gall bladder that was not sent to pathology (Supplementary Figure 2). CSF multiplex polymerase chain reaction results were out on

August 09, 2021, revealed the absence of Cytomegalovirus, Epstein-Barr virus, Herpes simplex viruses 1 and 2, Varicella-Zoster virus, Enterovirus, Parechovirus, Human Herpes Viruses 6 and 7, *H. influenzae*, *S. pneumoniae*, and *S. agalactiae*. However, cryptococcal antigen was detected by qualitative antigen testing. His human immunodeficiency virus (HIV) serology was negative. His CSF culture was also negative and he had a CD4 count of 117. Acyclovir was discontinued. The patient was started on IV liposomal amphotericin B at 5 mg/kg daily and IV fluconazole at 800 mg daily because of the unavailability and high toxicity of flucytosine. CSF studies were repeated on August 9, 2021, which revealed 100/mm<sup>3</sup> of red blood cells and 85/mm<sup>3</sup> of white blood cells, 85% of which were lymphocytes, with the persistence of the cryptococcal antigen positivity. Quantitative Cryptococcal assay showed a positive titer at a dilution of 1/400.

One day before the antifungal treatment initiation, the patient developed polyuria of 7 L/day. Urine output exceeded 300 mL per 2 h with a total of 6 L/24 h. He had a serum Na of 148 mEq/L that increased to 153 mEq/L. His blood osmolality was 320 mOsmol/kg (276–295 mOsmol/kg), and his urine osmolality was 220 mOsmol/kg (500–850 mOsmol/kg). The fluid restriction did not stop the polyuria. The patient was started on oral desmopressin at 60 mcg twice daily. The dosage was increased to 120 mcg twice a day on day 11. The serum sodium level was gradually corrected by approximately 5 mEq/L/day titrated to urine output reaching 1300 mL/24 h. Supplementary Figure 1 tracks serum sodium from August 10, 2021, to August 21, 2021. Sublingual desmopressin was adjusted with gradual resolution of symptoms over 2 weeks.

The induction phase of anti-cryptococcal treatment was completed on September 1, 2021, and the patient was switched to IV fluconazole at 800 mg daily monotherapy for 2 months. Repeat flow cytometry performed on September 7, 2021, showed an increase

in CD4 count to 238. The patient was finally discharged on September 8, 2021, on IV fluconazole at 800 mg daily and apixaban at 2.5 mg twice daily with a recommendation for scheduled serial lumbar punctures and urine output monitoring. Serial cryptococcal antigen in CSF monitoring on treatment revealed a titer of 1:67 on October 26, 2021, 1:16 on November 22, 2021, and zero on February 15, 2022 (Figure 1). Figure 2 shows the CSF cell count progression and cryptococcal titers.

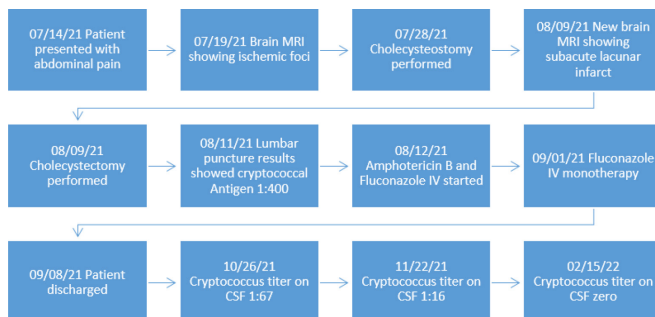
**Discussion and Literature Review**

A myriad of complications has been reported to occur during and/or after COVID-19 infections, such as bacterial superinfections, autonomic dysfunction, delirium, anxiety, depression, autoimmune disease, and rhino-orbital mucormycosis. Here we described a case of cryptococcal meningitis post-COVID-19 infection complicated by central DI and ischemic brain strokes.

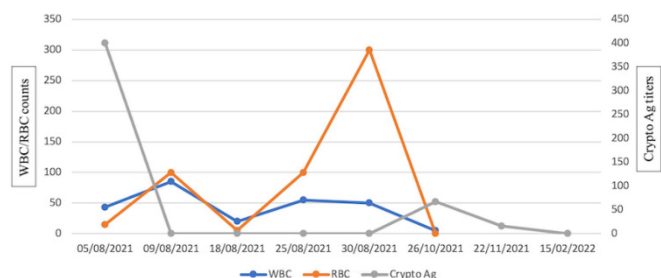
Cryptococcal disease is historically seen in patients with acquired immunodeficiency syndrome (AIDS), but it can also occur in patients with rheumatological diseases, patients on immunosuppressive drugs, organ transplant recipients, and patients with hematological malignancies such as multiple myeloma [5,16]. Patients positive for HIV are more likely to present with central nervous system (CNS) manifestations whereas non-neurologic manifestations are more common in HIV-negative immunocompromised patients [17,18].

Cryptococcal infections were reported in patients taking prolonged courses of steroids with no other apparent cause of immunodeficiency [6,19]. A 2016 study revealed that 60% of patients with cryptococcal infections were on immunomodulating agents upon diagnosis [20]. However, the type of immunosuppressive drug appears to influence the manifestation of cryptococcus infection. This infection has occurred after anti-tumor necrosis factor-alpha treatment, in which patients presented with pneumonia [21,22] and cutaneous manifestations [23]. Other

**Figure 1.** Timeline chart of admission, discharge, interventions, and medications.



**Figure 2.** Variation of CSF RBC, WBC, and Cryptococcal antigen titers through serial lumbar punctures.



immunosuppressive drugs, such as cyclosporin, place recipients at risk of CNS cryptococcal infection [24]. Patients who take tacrolimus showed a faster onset of cryptococcal disease and mainly have skin, soft tissue, and articular manifestations [24,25]. Furthermore, cryptococcal pneumonia and empyema were reported in a patient on ibrutinib for diffuse large B-cell lymphoma [7].

The rise in cryptococcal infections seen in patients with COVID-19 is likely due to the widespread use of immunosuppressive therapy after the RECOVERY trial demonstrated a mortality benefit with the use of dexamethasone in patients with hypoxic COVID-19 [26]. Table 1 shows all reported cases of patients with COVID-19 with cryptococcal infection. Most patients presented with cryptococemia and two presented with meningitis, like our patient. Most patients received long-term steroid treatment and two received steroids with tocilizumab, similar to our patient.

Meningitis was linked with strokes, and one of the proposed mechanisms is the coagulation cascade activation and the decreased fibrinolytic pathway activity resulting in cerebral infarction [27]. However, the incidence of stroke due to cryptococcal meningitis remains the lowest among fungal pathogens [28]. Cerebral infarcts due to cryptococcal meningitis could occur in the acute phase as presenting sign of cryptococcal meningitis and can be recurrent if the cryptococcal infection is not treated, such as our patient [1]. Infarcts caused by cryptococcal meningitis are usually bilateral, multiple, and lacunar with the most common location at the basal ganglia and internal capsule [2]. Strokes due to cryptococcal meningitis affecting the cortical and subcortical areas are rare and are only described in case reports [3,4].

Central DI is caused by different etiologies, including primary or secondary lesions, infiltrative diseases [29], neurosurgery, and trauma, yet the most

**Table 1.** Case reports of cryptococcus infection in COVID 19 patients.

Author	Year	Age	Gender	Case	CD4 COUNT	Treatment	Outcome
Rama V.T, Mondy K, Rose D [57]	2021	75	Male	COVID-19 with superimposed MRSA infection, patient continued to deteriorate and blood culture showed cryptococcus neoformans	Not reported	COVID treatment: Remdesivir, dexamethasone, prednisone and convalescent plasma. <u>Cryptococcus treatment:</u> Did not receive any antifungals prior to death.	Patient passed away.
Alegre-Gonzalez D, Herrera S, Berna J, Soriano A, Bodro M [58]	2021	78	Male	Admitted 2 months after an initial Covid-19 infection for fever, he was found to have CSF cryptococcal Ag and positive blood Culture for cryptococcus.	Not reported	COVID treatment: Dexamethasone methylprednisone followed by a prednisone taper. <u>Cryptococcus treatment:</u> Amphotericin B and flucytosine, then maintenance fluconazole.	Patient passed away, after multiple hospitalizations
Ghanem H, Sivasubramanian G [59]	2021	73	Male	COVID pneumonia, developed new neurological symptoms, CSF cryptococcal antigen was positive and blood Culture grew cryptococcus neoformans	Not reported	COVID treatment: Dexamethasone <u>Cryptococcus treatment:</u> Amphotericin B and flucytosine VP shunt	Discharged to a rehabilitation facility.
Khatib M, Nashwan A, Ahmed A, Said B, Shaat S, Mohamed A [60]	2021	60	Male	Severe covid. After persistent elevation in inflammatory marker blood culture grew Cryptococcus neoformans.	Not reported	COVID treatment: Tocilizumab, methylprednisone and hydrocortisone <u>Cryptococcus treatment:</u> Amphotericin B and flucytosine	Patient passed away
Gil Y, Gil YD, Markou T [61]	2021	59	Male	COVID infection, developed fever at day 10 of hospital stay and blood culture grew cryptococcus neoformans.	636 cells/microliter	COVID treatment: Azithromycin, ceftriaxone, remdesivir and dexamethasone <u>Cryptococcus treatment:</u> Amphotericin B monotherapy then fluconazole.	Recovered.
Chastain D, Andrés F, Austin C, Steele G, Stoudenmire LL, Thomas GM, Franco-Paredes V, Franco-Paredes K, Franco-Paredes C [62]	2022	70	Male	Desaturation due to COVID-19. After a period of improvement, the patient deteriorated again despite multiple antibiotics and blood cultures grew cryptococcus in the postmortem period. Weakness and confusion and found to have Covid-19 pneumonia. Patient was discharged then readmitted with encephalopathy and acute and subacute infarcts Blood and CSF cultures grew cryptococcus neoformas.	Not reported	COVID treatment: Dexamethasone followed by methylprednisone. Ceftriaxone, azithromycin, <u>Cryptococcus treatment:</u> None	Patient passed away
Thota D, Ray B, Sharma K, Hasan M [11]	2022	76	Female		300 cells/mm <sup>3</sup>	COVID treatment: Remdesivir, convalescent plasma, methylprednisone and tocilizumab Cefepime, vancomycin, ampicillin, micafungin <u>Cryptococcus treatment:</u> Amphotericin B and flucytosine.	Transferred to a long-term nursing facility.



common cause is idiopathic [30]. A few cases of DI were reported to be caused by a meningeal infection. Chronic meningitis due to tuberculosis leads to DI due to posterior pituitary gland destruction or infiltration [31,32]. Usually, bacterial meningitis is associated with increased antidiuretic hormone secretion resulting in hyponatremia due to the syndrome of inappropriate secretion of antidiuretic hormone. DI can rarely result from pneumococcal meningitis [33] or even meningococcal meningitis [34]. Most of these cases tend to respond to vasopressin treatment and self-resolve after treating meningitis, similar to our case.

The literature shows no clear cause for DI in cryptococcal meningitis, although the mechanism might be similar to other chronic meningitis conditions, such as tuberculosis [35]. Very few studies have reported DI in HIV-negative patients with cryptococcal meningitis [6,16,18,19,28,36]. Central DI can also occur secondary to an ischemic stroke which has been reported specifically in patients with disrupted blood supply to the posterior pituitary glands and neonates [12,30,37]. These cases tend to respond to desmopressin. Table 2 summarizes the associations between cryptococcal meningitis and DI, while Table 3

**Table 2.** Case reports of cryptococcal meningitis and diabetes insipidus.

Author	Date of publication	Case	Gender	Age	Treatment	Outcome
Juffermans N, Verbon A, Poll T [8]	2002	Patient presented with AIDS and cryptococcal meningitis.	Male	44	Desmopressin and Ambisome	Central DI subsided upon recovery from cryptococcal meningitis
Fujita Y, Kasahara K, Uno K, Konishi M, Maeda K, Yoshimoto E, Murakawa K, Mikasa K, Amano I, Morii T, Kimura H [9]	2005	Patient presented with cryptococemia due to neutropenia. Treatment by amphotericin B caused nephrogenic Diabetes insipidus.	Female	66	Water and potassium replacement.	Resolution upon cessation of amphotericin B.
Sittambalam C, Hanna H, Martello J, Mitsani D [6]	2012	Patient with diabetes, COPD, hepatitis C on chronic steroids presenting for severe headache found to have cryptococcal meningitis and then DI.	Male	63	Amphotericin B and Flucytosine. Fluconazole as maintenance, Dexamethasone for brain edema.	Resolution of DI.
Rosario M., Song SX, McCullough LD [3]	2012	Patient presented with fatigue and gait instability found to have multiple cerebral infarcts. Cerebro-spinal fluid grew cryptococcus.	Male	58	Amphotericin B and flucytosine.	Patient passed away
Swan CD, Gottlieb T [7]	2018	Patient on R-CHOP and ibrutinib for DLBCL, presenting for desaturation and chest pain found to have empyema and new pulmonary nodules. Cryptococcal antigen was positive in the blood and pleural fluid.	Male	79	Amphotericin B and flucytosine. Fluconazole as maintenance.	Resolution of pulmonary nodules and empyema. DI as a result of amphotericin B that resolved after treatment stopped.
Ellis JP, Kalata N, Joekes EC, Kampondeni S, Benjamin LA, Harrison TS, Laloo DG, Heyderman RS [10]	2018	Patient newly diagnosed with HIV and found to have a positive cryptococcal Ag in the cerebro-spinal fluid with central DI.	Male	38	Fluconazole and flucytosine	Resolution of motor deficit. And DI.
Zhou W, Lai J, Huang T, Xu Y, Hu S [4]	2018	Patient presenting with fatigue and headache, Brain MRI showed multiple ischemic foci and narrowing of cerebral arteries. Cerebro-spinal fluid showed positive India ink stain.	Female	81	FLuconazole and mannitol and VP Shunt.	Improvement on further follow-up
Sayhi S, Bouzidi S, Beji I, Nasr AA, Hannachi S, Bedoui I, Layouni S, Fekih-Mrissa N, Louzir B, Nsiri B, Abid R, Battikh R [5]	2020	Patient presenting with new onset headache and blurry vision, cerebro-spinal fluid and blood Cryptococcal antigen were positive. DI later developed. Further workup revealed multiple myeloma.	Male	63	Amphotericin B and flucytosine. Fluconazole as maintenance. Repeated cerebro-spinal fluid taps.	No clinical or radiologic evidence of cryptococcal infection after 9 months. DI symptoms resolved.
Sengel B, Tukenmez TE, Can SR, Midi I, Cerikcioglu N, Odabasi Z [1]	2021	Patient presenting with headache, weakness, inability to walk. MRI showed hypo plastic cerebral arteries and India ink stain was positive.	Male	59	Amphotericin B and fluconazole.	Total regression of symptoms with no sequela

summarizes the literature on associations between strokes and DI.

The case presented reveals a prolonged state of immunodeficiency with high and multiple doses of tocilizumab in combination with steroids. This treatment was given as part of the cytokine storm management in severe COVID-19. Cryptococcal meningitis is among the well-established opportunistic infections associated with low CD4 counts in patients with AIDS, thus the development of this infection in our patient is most likely linked to his severely immunodeficient state induced by the tocilizumab/steroid combination. The additional development of DI and the presence of multiple brain thrombi raises questions in this case. The presence of unexplained multiple thrombi in the brain despite normal cardiac and carotid radiologic examination may indicate their development *in situ*, possibly linking them to the cryptococcal infection. The central DI was completely resolved after treating the cryptococcal infection, making it less likely to be related to the thrombi and more likely related to the fungal infection.

This elucidates the risk of opportunistic infections, such as cryptococcal meningitis, in COVID-19 patients who receive high doses of immune suppression therapy, especially in the elderly population. The CD4 cell counts drop by 1.7 cells/mm<sup>3</sup> every 10 years as part of the natural aging process [38]. However, the drop in our patient’s CD4 cell levels far exceeds this report. The immune system ages with time and the number of circulating effective neutrophils, tissue macrophages, natural killer cells, and dendritic cells, as well as naïve lymphocytes, substantially decrease over the years [39]. The immune cells also get re-distributed toward the adipose tissue rather than high-infectious risk organs,

such as the lungs or the gut [39]. Additionally, the immune protective role of these cells shifts toward a more inflammatory role [39-45]. Tocilizumab has also decreased the number of naïve CD4+ T cells while increasing the number of memory CD4+ T cells [46-51]. Dexamethasone also induced immunosuppression by increasing CTLA-4 protein and mRNA which leads to less T cell differentiation [52-57]. Together, steroids and tocilizumab contribute to decreasing the number of both CD4 and CD8 naïve T cells [58-62].

To our knowledge, this is the first case of cryptococcal disease complicated by strokes and DI in post-COVID-19 infection. The association of the three entities, cryptococci, thrombi, and DI, remains poorly understood. Thus, further studies are needed to assess the incidence of such conditions in immunosuppressed elderly patients with COVID-19.

**Conclusions**

A clear association was found between chronic meningitis and brain infarcts although the quality of evidence is low and mostly based on case reports and case series. CNS infarcts have also been associated with DI in the literature, both in the presence and absence of chronic meningitis, including cryptococcal meningitis. These disease states occur with various types of immunodeficiency, similar to our patients. This case clearly displays a cause for concern in using immunosuppressive agents to treat elderly patients with COVID-19. Administering immunomodulatory agents in the elderly can cause serious morbidity and possibly mortality, especially because of their existing age-related immunocompromised state. The use of immunomodulatory treatment in the elderly population should be avoided or done with extreme caution when

**Table 3.** case reports of stroke and diabetes insipidus.

Authors	Case	Age	Gender	Date	Cause	Treatment	Outcome
Mallesappa P, Ranganath R, Chaudhari A, Upadhayaya K, Mehta H [13]	Patient presenting for headache and vomiting with sepsis. Two days later the she started to develop excessive urination more than 7 L/day.	50	Female	2012	Bilateral multiple vertebral artery dissection and central DI	Sublingual vasopressin	Resolution of DI
Rivas-Crespo M, Miñones-Suárez L, Gallarza S [12]	Patient presenting after 1 week of irritability and feeding difficulties.	28 days old	Male	2012	Intraventricular hemorrhage along with periventricular infiltration and hydrocephalus	Subcutaneous desmopressin 0.02ug BID	Desmopressin for life to control central DI
Jayaraman M, Kumar S, Ahmad FM [14]	Patient presenting with sudden onset left hemiparesis along with a seizure then developed persistent polyuria	35	Male	2013	Multiple ischemic infarcts with hemorrhagic transformation	Nasal Desmopressin For 5 days	Resolution of central diabetes insipidus
Kalita P, Daulagaja B [15]	Patient presenting with progressive loss of sensation 13 days following a right sided hemorrhagic stroke. Patient developed increasing urine output reaching 1760ml in 12 hours	47	Male	2018	Right sided hemorrhagic stroke	Nasal Desmopressin	Patient regained full consciousness. Diabetes Insipidus resolved

indispensable to avoid serious complications and potentially fatal opportunistic infections. This should be considered deciding on severe COVID-19 treatments, especially in the elderly population. Performing an evaluation of immune status (i.e., CD4 counts) and considering unusual opportunistic infections in the assessment of elderly patients may be beneficial.

### Patient Perspective

The patient was adherent to his treatment, and his family was satisfied as they saw him slowly recover.

### Informed Consent

Patient informed consent was taken to write this case report.

### References

- Sengel BE, Tigen ET, Sarinoglu RC, Midi I, Cerikcioglu N, Odabasi Z (2021) Cryptococcus meningitis presented with multiple cerebral infarcts in an immunocompetent patient. *IDCases* 24: 1154.
- Vela-Duarte D, Nyberg E, Sillau S, Pate A, Castellanos P, Chastain DB, Franco-Paredes C, Henao-Martinez AF (2019) Lacunar stroke in cryptococcal meningitis: clinical and radiographic features. *J Stroke Cerebrovasc Dis* 28: 1767-1772.
- Rosario M, Song SX, McCullough LD (2018) An unusual case of stroke. *Neurologist* 18: 229-232.
- Zhou W, Lai J, Huang T, Xu Y, Hu S (2018) Cryptococcal meningitis mimicking cerebral infarction: a case report. *Clin Interv Aging* 13: 1999-2002.
- Sayhi S, Bouzidi S, Beji I, Nasr AA, Hannachi S, Bedoui I, Layouni S, Fekih-Mrissa N, Louzir B, Nsiri B, Abid R, Battikh R (2020) Neuro-meningeal cryptococcal infection revealing a multiple myeloma. *Pan Afr Med J* 36: 324.
- Sittabalam CD, Hanna H, Martello J, Mitsani D (2012) Cryptococcus infection in a non-HIV patient: a case report. *J Community Hosp Intern Med* 2: 19254.
- Swan CD, Gottlieb T (2018) Cryptococcus neoformans empyema in a patient receiving ibrutinib for diffuse large B-cell lymphoma and a review of the literature. *Case Rep* 2018.
- Juffermans NP, Verbon A, Poll TV (2002) Diabetes insipidus as a complication of cryptococcal meningitis in an HIV-infected patient. *Scand J Infect Dis* 34: 397-398.
- Fujita Y, Kasahara K, Uno K, Konishi M, Maeda K, Yoshimoto E, Murakawa K, Mikasa K, Amano I, Morii T, Kimura H (2005) Amphotericin B-induced nephrogenic diabetes insipidus in a case of cryptococemia. *Intern Med* 44: 458-461.
- Ellis JP, Kalata N, Joekes EC, Kampondeni S, Benjamin LA, Harisson TS, Lalloo DG, Heyderman RS (2018) Ischemic stroke as a complication of cryptococcal meningitis and immune reconstitution inflammatory syndrome: a case report. *BMC Infect Dis* 18: 1-5.
- Thota DR, Ray B, Hasan M, Sharma K (2022) Cryptococcal meningoencephalitis during convalescence from severe COVID-19 pneumonia. *The Neurohospitalist* 12: 96-99.
- Rivas-Crespo MF, Miñones-Suárez L (2012) Rare neonatal diabetes insipidus and associated late risks: case report *BMC Pediatr* 12: 1-6.
- Mallesappa P, Ranganath R, Chaudhari AP, Upadhayaya KL, Mehta HJ (2013) Transient central diabetes insipidus following spontaneous bilateral vertebral artery dissection. *Rev Nefrol Dial Traspl* 34: 126-128.
- Muthukrishnan SK, Ahmad F (2013) Transient central diabetes insipidus following ischemic stroke. *Indian J Endocrinol Metab* 17: 152.
- Kalita PP, Daulagajao B (2018) Central diabetes insipidus following hemorrhagic stroke - a case report. *IOSR J Dent Med Sci* 17: 11-13.
- Pappas PG (2013) Cryptococcal infections in non-HIV-infected patients. *Trans Am Clin Climatol Assoc* 124: 61.
- Brizendine KD, Baddley JW, Pappas PG (2013) Predictors of mortality and differences in clinical features among patients with Cryptococcosis according to immune status. *PloS One* 8.
- Bratton EW, El-Husseini N, Chastain CA, Lee MS, Poole C, Stumer T, Jüliano JJ, Weber DJ, Perfect JR (2012) Comparison and temporal trends of three groups with cryptococcosis: HIV-infected, solid organ transplant, and HIV-negative/non-transplant. *Plos One* 7.
- Nidhi A, Meena A, Sreekumar A, Daga MK (2017) Corticosteroid-induced cryptococcal meningitis in patient without HIV. *BMJ Case Rep* 2017.
- Leonhard SE, Fritz D, Van-de-Beeck D, Brouwer MC (2016) Cryptococcal meningitis complicating sarcoidosis. *Medicine* 95.
- Hage CA, Wood KL, Winer-Muram HT, Wilson SJ, Sarosi G, Knox KS (2003) Pulmonary cryptococcosis after initiation of anti-tumor necrosis factor- $\alpha$  therapy. *Chest* 124: 2395-2397.
- Shrestha RK, Stoller JK, Honari G, Procop GW, Gordon SM (2004) Pneumonia due to cryptococcus neoformans in a patient receiving infliximab: possible zoonotic transmission from a pet cockatiel. *Respir Care* 49: 606-608.
- Chiriac A, Mares M, Mihaila D, Solovan C, Moldovan C, Stolnicu S, Hagen F (2017) Primary cutaneous cryptococcosis during infliximab therapy. *Dermatol Ther* 30.
- Husain S, Wagener MM, Singh N (2001) Cryptococcus neoformans infection in organ transplant recipients: variables influencing clinical characteristics and outcome. *Emerg Infect Dis* 7: 375.
- Cruz MC, Del-Poeta M, Wang P, Wegner R, Zenke G, Quesniaux VF, Movva NR, Perfect JR, Crdenas ME, Heitman J (2000) Immunosuppressive and nonimmunosuppressive cyclosporine analogs are toxic to the opportunistic fungal pathogen *Cryptococcus neoformans* via cyclophilin-dependent inhibition of calcineurin. *Antimicrob Agents Chemother* 44: 143-149.
- RECOVERY Collaborative Group (2021) Dexamethasone in hospitalized patients with Covid-19. *N Engl J Med* 384: 693-704.
- Weisfelt M, Determann RM, De-Gans J, Van-Der-Ende A, Levi M, Van-De D, Schultz MJ (2007) Procoagulant and fibrinolytic activity in cerebrospinal fluid from adults with bacterial meningitis. *J Infect* 54: 545-550.
- Chen S, Lu C, Lui C, Huang C, Chuang Y, Tan T, Tsai N, Chang C, Tsai W, Chang W (2011) Acute/subacute cerebral infarction in HIV-negative adults with cryptococcal meningoencephalitis: a MRI-based follow-up study and a clinical comparison to HIV-negative CM adults without ASCI. *BMC Neurolo* 11: 1-7.
- Grois NG, Favara BE, Mostbeck GH, Prayer D (1998) Central nervous system disease in langerhans cell histiocytosis. *Hematol Oncol Clin North Am* 12: 287-305.

30. Kraus J, Heckmann JG, Druschky A, Erbguth F, Neundörfer B (1999) Ondine's curse in association with diabetes insipidus following transient vertebrobasilar ischemia. *Clin Neurol Neurosurg* 101: 196-198.
31. Christ-Crain M, Bichet DG, Fenske WK, Goldman MB, Rittig S, Verbalis JG, Verkman AS. Diabetes insipidus. *Nat Rev Dis Primers* 5: 1-20.
32. Lorber J (1958) Diabetes insipidus following tuberculous meningitis. *Arch Dis Child* 33: 315.
33. Franco-Paredes C, Evans J, Jurado R (2001) Diabetes insipidus due to streptococcus pneumoniae meningitis. *Arch Intern Med* 161: 1114-1115.
34. Christensen C, Bank A (1988) Meningococcal meningitis and diabetes insipidus. *Scand J Infect Dis.* 20: 341-343.
35. Lam KS, Sham MM, Tam SC, Ng MM, Ma HT (1993) Hypopituitarism after tuberculous meningitis in childhood. *Ann Intern Med* 118: 701-706.
36. Loya MK (2016) A case of central diabetes insipidus in a non-HIV patient with cryptococcal meningitis. *Am Thorac Soc* 13: 193.
37. Maghnie M, Genovese E, Aricò M, Villa A, Beluffi G, Campani R, Severi F (1994) Evolving pituitary hormone deficiency is associated with pituitary vasculopathy: dynamic MR study in children with hypopituitarism, diabetes insipidus, and langerhans cell histiocytosis. *Radiology* 193: 493-499.
38. Natural History Project Working Group for the Collaboration of Observational HIV Epidemiological Research Europe (COHERE) in EuroCoord (2014) Factors associated with short-term changes in HIV viral load and CD4 (+) cell count in antiretroviral-naïve individuals. *AIDS* 28: 1351-1356.
39. Mogilenko DA, Shchukina I, Artyomov MN (2022) Immune ageing at single-cell resolution. *Nat Rev Immunol* 22: 484-498.
40. Kikuchi J, Hashizume M, Kaneko Y, Yoshimoto K, Nishina N, Takeuchi T (2015) Peripheral blood CD4 + CD25 + CD127 low regulatory T cells are significantly increased by tocilizumab treatment in patients with rheumatoid arthritis: increase in regulatory T cells correlates with clinical response. *Arthritis Research & Amp. Therapy* 17: 10.
41. Giles A, Hutchinson M, Sonnemann H, Jung J, Fecci P, Ratnam N, Zhang W, Song H, Bailey R, Dionne D, Reid C, Park D, Gilbert M (2018) Dexamethasone-induced immunosuppression: mechanisms and implications for immunotherapy. *J Immunother Cancer.* 6: 1-13.
42. Fanelli V, Montrucchio G, Sales G, Simonetti U, Bonetto C, Rumbolo, F, Mengozzi G, Urbino R, Pizzi C, Richardi L, Cappello P, Brazzi L (1990) Effects of steroids and tocilizumab on the immune response profile of patients with COVID-19-associated ARDS requiring or not veno-venous extracorporeal membrane oxygenation. *Membranes* 11: 603.
43. MacGilvray SS, Billow M (1990) Diabetes insipidus as a complication of neonatal group B streptococcal meningitis. *Pediatr Infect Dis J* 9: 742.
44. Baruteau J, Cartault A, Chanut A, Sevely A, Casper C (2009) Neonatal *Escherichia coli* meningitis can be complicated by central permanent diabetes insipidus. *J Pediatr Endocrinol Metab* 22: 213-214.
45. Cohen C, Rice EN, Thomas DE, Carpenter TO (1998) Diabetes insipidus as a hallmark neuroendocrine complication of neonatal meningitis. *Curr Opin Pediatr* 10: 449-452.
46. Aydogan S, Dilli D, Ozyazıcı A, Cakmakci E, Koyuncu E, Zenciroğlu A (2019) Central diabetes insipidus in an infant with pneumococcal meningitis. *Fetal Pediatr Pathol* 38: 80-84.
47. Kabakus N, Yilmaz B, Aydinoğlu H, Serhathoğlu S (1999) Transient diabetes insipidus following *Escherichia coli* meningitis complicated by ventriculoperitoneal shunt. *J Endocrinol Invest* 22: 800-802.
48. Hay DR (1960) Diabetes insipidus after tuberculous meningitis. *Br Med J* 1:707.
49. Levin AR (1959) Diabetes insipidus associated with tuberculous meningitis. *Br Med J* 2: 1061-1063.
50. Abramsky O, Soffer D, Marks ES (1973) Diabetes insipidus as a complication of pneumococcal meningitis. *J Am Geriatr Soc* 21: 232-234.
51. Kim S, Oh H, Lee D, Ho D, Ann B, Kim K (1998) A case of diabetes insipidus following tuberculous meningitis. *Korean J Med* 1998: 568-571.
52. Jones G, Muriello M, Patel A, Logan L (1960) Enteroviral Meningoencephalitis complicated by central diabetes insipidus in a neonate: a case report and review of the literature. *J Pediatric Infect Dis Soc* 4: 155-158.
53. Wall JP (1960) Diabetes Insipidus after Tuberculous Meningitis. *Br Med J* 2: 68.
54. Gatell JM, Esmatjes E, Serra C, Aymerich M, SanMiguel JG (1982) Diabetes insipidus and anterior pituitary dysfunction after staphylococcal meningitis and multiple brain abscesses. *J Infect Dis* 146:102.
55. Mushtaq MZ, Mahmood SBZ, Aziz A (2020) A fatal case of primary amoebic meningoencephalitis (PAM) complicated with diabetes insipidus (DI): a case report and review of the literature. *Int J Infect Dis* : 4925819.
56. Montejo Gañán I, Romera Santabárbara B, García Íñiguez JP, Ruiz del Olmo Izuzquiza I, Dominguez Cajal MM, Monge Galindo L, Madurga Revilla P (2010) Acute encephalopathy, hydrocephalus and diabetes insipidus central as a form of presentation of meningitis by *Listeria monocytogenes*. *An pediatr* 72: 288-289. [Article in Spanish]
57. Thyagarajan RV, Mondy KE, Rose DT (2021) Cryptococcus neoformans blood stream infection in severe COVID-19 pneumonia. *IDCases* 26.
58. Alegre-González D, Herrera S, Bernal J, Soriano A, Bodro M (2021) Disseminated cryptococcus neoformans infection associated to COVID-19. *Med Mycol Case Rep* 34: 35-37.
59. Ghanem H, Sivasubramanian G (2021) Cryptococcus neoformans meningoencephalitis in an immunocompetent patient after COVID-19 infection. *Case Rep Infect Dis* 2021.
60. Khatib MY, Ahmed AA, Shaat SB, Mohamed AS, Nashwan AJ (2021) Cryptococemia in a patient with COVID-19: A case report. *Clin. Case Rep.* 9: 853-855.
61. Gil Y, Gil YD, Markou T (2021) The emergence of cryptococemia in COVID-19 infection: a case report. *Cureus* 13.
62. Chastain DB, Henao-Martínez AF, Dykes AC, Steele GM, Stoudenmire LL, Thomas GM, Kung V, Franco-Paredes C (2022) Missed opportunities to identify cryptococcosis in COVID-19 patients: a case report and literature review. *Ther Adv Infect Dis* 9.

### Corresponding author

Rola Husni, MD

Lebanese American University School of Medicine and Lebanese

American University Medical Center–Rizk Hospital

Beirut, Lebanon

Tel: 009613924800

Email: [roula.husni@lau.edu.lb](mailto:roula.husni@lau.edu.lb); [roula.samaha@laumerh.com](mailto:roula.samaha@laumerh.com)

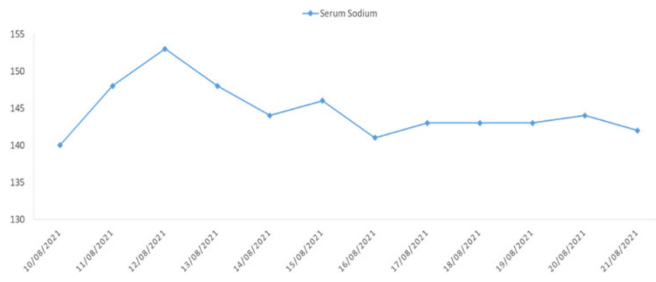
**Conflict of interests:** No conflict of interests is declared.



**Annex – Supplementary Items****Supplementary Table 1.** Case reports of non-cryptococcal meningitis and DI.

Authors	Date	Case	Gender	Age	Treatment	Outcome
MacGilvray S, Billow M. [43]	1990	Case of Pneumococcal meningitis complicated by Central DI 2 days post admission	Female	2 weeks	Subcutaneous vasopressin then intranasal desmopressin	Persistent central DI that was controlled with desmopressin
Christensen C, Bank A [34]	1988	Case of N. Meningitis with sepsis and DIC complicated by central DI	Female	20 years	Desmopressin	recovered from central DI on day 15
Baruteau J, Cartault A, Chanot A, Sevely A, Casper C [44]	2009	Case of E. Coli meningitis resulting in hydrocephalus complicated by central DI 2 days later.	Female	Day 15 of life	Desmopressin	Permanent Central DI controlled with Desmopressin
Cohen C, Rice EN, Thomas DE, Carpenter TO [45]	1998	Case of group B streptococci treated with penicillin. Two days post admission patient became polyureic and was diagnosed with central DI.	Female	8 weeks old	Desmopressin	Lifelong desmopressin treatment.
Aydogan S, Dilli D, Ozyazici A, Cakmakci E, Koyuncu E, Zenciroglu A [46]	2019	Case of a newborn who had CT findings suggestive of Dandy-Walker syndrome was diagnosed with S. pneumonia meningitis, then DI 3 days later.	Male	Day 9 of life	vasopressin	Patient stayed on nasal vasopressin till death 4 months later.
Kabakus N, Yilmaz B, Aydinoglu H, Serhathoglu S [47]	1999	Case of an infant who had dandy-walker malformation with a ventriculoperitoneal shunt found to have E. Coli meningitis, on day 3 post admission then later developed central DI	Male	18 months	vasopressin and fluid adjustment	Patient recovered from central DI on day 20
Hay DR [48]	1960	Case of tuberculous meningitis, complicated by diabetes insipidus 8 months post streptomycin treatment.	Male	3 years	Vasopressin injections later switched to vasopressin snuff	Patient was able to resume normal daily life on intranasal vasopressin
Levin AR [49]	1959	Case of tuberculous meningitis complicated by DI and bilateral Cranial Nerve VI palsies	Female	5 years	Aqueous pitressin which was changed to pitressin in tannate oil	Patient recovered around 3 months after admission
Abramsky O, Soffer D, Marks E [50]	1973	Case of pneumococcal meningitis complicated by DI 10 days later.	Male	68 years	Pitressin intramuscular injections	Improved 2 weeks later.
Mohana KL [36]	2016	Case of cryptococcal meningitis complicated by DI 5 days post admission.	Male	56 years	Vasopressin.	Patient didn't improve on anti-fungal treatment and later passed away.
Kim S, Oh H, Lee D, Ho D, Ann B, Kim K. [51]	1998	Case of tuberculous meningitis followed by increased urine output suggesting central DI	Male	25 years	Vasopressin	Patient suffered a cardiac arrest on Day 20 and passed away
Jones G, Muriello M, Patel A, Logan L [52]	2015	Case of neonate presenting for lethargy and increased urine output. CSF culture was positive for Coxsackie B1 virus and central DI was diagnosed by low ADH levels in addition to low urine osmolality.	Male	Day 3 of life	desmopressin on day 13 of life	Patient progressively improved requiring less desmopressin.
Wall JP [53]	1960	Case of tuberculous meningitis placed on antituberculous treatment. 6 months later patient developed DI	Female	5 years	tannate subcutaneous switched to vasopressin snuff	Patient recovered from tuberculous meningitis however, she was kept on vasopressin for her persistent central DI
Lorber J [32]	1958	Case of relapse tuberculous meningitis complicated by DI 5 months later.	Male	12 years	Started with vasopressin snuff then intramuscular pitressin	Patient was discharged home on maintenance dose
Gatell J, Esmatjes E, Serra C, Aymerich M, SanMiguel J [54]	1982	Case of staphylococcal meningitis with multiple brain abscesses specifically in the parietal lobe complicated by DI 10 days later.	Male	42 years	Intramuscular vasopressin	Central DI resolved after a month from admission
Mushtaq M, Mahmood S, Aziz A [55]	2020	Case of <i>Naegleria fowleri</i> meningoencephalitis, given amphotericin B, miltefosine, rifampin, fluconazole and dexamesathone. 3 days later started having increased urine output, hypernatremia and low urine sodium.	Male	44 years	PO desmopressin	Patient died on day 4 of admission
Montejo GI, Romera SB, Iniguez GJ, Olmo R, Izuzquiza I, Dominguez CM, Monge GL, Madurga RP, Encefalopatía A, Hidrocefalia Y [56]	2010	Case of Listeria. Monocytogenes complicated by DI	Female	8 months	Intranasal desmopressin	Patient fully recovered on day 12

**Supplementary Figure 1.** The Variation of Serum Sodium Concentration (mmol/dL) with Time.



**Supplementary Figure 2.** Necrotic gall bladder removed surgically.

