

Case Report

Guillain-Barré Syndrome and multiple lacunar infarcts in a COVID-19 patient

Yulia Devina Suci¹, Alfian Nur Rosyid¹, Nurwapina Langga Wulaa², Muh Alamsyah³, Irmayani AK⁴, Tamsil Bachrun⁵

¹ Department of Pulmonology and Respiratory Medicine, Dr. Soetomo Academic Hospital, Universitas Airlangga Faculty of Medicine, Indonesia

² Department of Neurology, Dr. Wahidin Sudirohusodo Hospital, Universitas Hasanuddin Faculty of Medicine, South Sulawesi, Indonesia

³ Department of Emergency, Kendari City Hospital, South East Sulawesi, Indonesia

⁴ Department of Neurology Bahteramas Hospital, South East Sulawesi, Indonesia

⁵ Department of Anesthesiology and Intensive Care, Bahteramas Hospital, South East Sulawesi, Indonesia

Abstract

Introduction: Hyperactivity immune responses to coronavirus disease 2019 (COVID-19) can lead to several manifestations in the human organ. One of the most affected organs is the respiratory system. Not only does it affect the respiratory system, but hyperactivity can also affect the neuromuscular and cerebrovascular systems, though it is scarce for both systems to be affected simultaneously.

Case presentation: We presented a mild COVID-19 patient with a history of progressive general weakness and dysphagia on day seventh day after patient was first diagnosed with COVID-19, which continued with diplopia and shortness of breath. The patient experienced respiratory failure type 1 and was admitted to an intensive care unit. A head CT scan showed multiple lacunar infarcts in the nucleus lentiform, while the electromyography (EMG) showed Guillain-Barré syndrome (GBS) with the subtype acute inflammatory demyelinating polyneuropathy (AIDP). The patient was reported to have successful therapy with intravenous immunoglobulin (IVIG) for five days and physical rehabilitation for three months. General weakness disappeared after the therapy, and the patient could do regular daily activities.

Conclusions: Various neurological symptoms can manifest in COVID-19 patients. Acute progressive muscle weakness should be considered as an autoimmune and cerebrovascular disease induced by COVID-19. Early diagnosis and treatment can provide a better outcome for the patient.

Key words: Guillain-Barré syndrome; multiple lacunar infarct strokes; SARS-CoV-2; infectious disease.

J Infect Dev Ctries 2023; 17(11):1641-1646. doi:10.3855/jidc.17975

(Received 22 January 2023 – Accepted 24 May 2023)

Copyright © 2023 Suci *et al.* This is an open-access article distributed under the Creative Commons Attribution License, which permits unrestricted use, distribution, and reproduction in any medium, provided the original work is properly cited.

Introduction

The current worldwide health concern is the coronavirus disease (COVID-19) pandemic, caused by SARS-CoV-2 infection. The World Health Organization (WHO) reported 572,239,451 total confirmed COVID-19 cases on July 29th, 2022. Meanwhile, there were 6,390,401 confirmed deaths [1]. Generally, COVID-19 patients have various signs and symptoms, but the predominant symptoms are shortness of breath, fever, cough, anosmia, or ageusia [2]. However, other symptoms can also appear in the organ systems, including the neurological, gastrointestinal, cardiovascular, and immunological systems [3]. Furthermore, in some cases, it can develop into COVID-19 syndromes with rare variant symptoms [4].

The SARS-CoV-2 also affects the Central nervous system (CNS), Peripheral nervous system (PNS), and

neuromuscular system [5]. Viral infections of COVID-19 can trigger an immune response through angiotensin-converting enzyme-2 (ACE-2) receptors that spread to many organ systems in the body [6]. Viruses can also enter the CNS via retrograde neuronal dissemination, extending to the spine and brain using existing neuronal transport pathways. Moreover, ACE-2's counterregulatory mechanism in the renin-angiotensin system leads to venous and arterial thrombosis [7].

Khan *et al.* reported that five COVID-19 patients were associated with GBS, where one of them had positive RT-PCR from the Cerebrospinal Fluid (CSF) [8]. Additionally, a systematic review by Abu-Rumeileh *et al.* showed that a higher prevalence clinical variant of GBS in COVID-19 is a classic sensorimotor form and acute inflammatory demyelinating polyneuropathy [9]. In addition, rare variants have also

been reported in COVID-19 patients, such as Miller-Fischer syndrome and cerebrovascular complications. A stroke complicates approximately 3% of COVID-19 patients. A study of 214 hospitalized COVID-19 patients in Wuhan, in a non-severe infection group, shows only one patient reported suffering an ischemic stroke [10].

In the following sections, we present a rare neurological manifestation from COVID-19 resulting in GBS with the subtype acute inflammatory demyelinating polyneuropathy (AIDP) type and multiple lacunar infarcts concurrently.

Case presentation

A 33-year-old male patient was admitted to the emergency department with decreased consciousness and respiratory failure. The patient was then intubated in the intensive care unit. The patient had a history of COVID-19 which began seven days prior with mild symptoms such as cough, sore throat, and fever. The patient took medication consisting of favipiravir 1600 mg twice daily on day 1, followed by 600 mg twice daily on days 2-5, vitamin D 5000 units/day, vitamin C 500 mg/day, N-Acetylcysteine 600 mg 3 times/day. After seven days, the patient took a PCR test for COVID-19, and the result was negative. However, on the seventh day, the patient started to experience tension headaches lasting three days. In addition, he also had progressive upper and lower bilateral extremity weakness, followed by swallowing

difficulties and always choking. The patient experienced doubled vision, shortness of breath, and difficulty coughing. On day 12, the patient lost consciousness at home. He was then admitted to the intensive care unit and intubated.

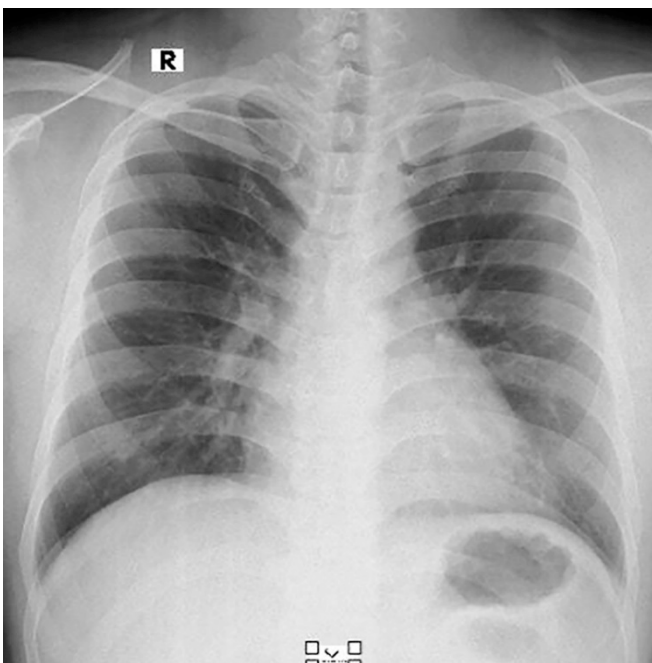
The patient had a history of controlled hypertension grade I and hypercholesterolemia for the past two years. The patient had obesity class I and had been smoking for the last ten years. There was no history of diabetes mellitus, autoimmune disorders, cancer, or trauma. In medical family history, the mother had controlled diabetes mellitus, and the father had a carcinoma pancreas. No history of autoimmune disorders was found in the family. The patient received his third COVID-19 vaccine last year.

The neurological examination found slight paresis N.VII and N.XII left primary type, dysphagia, a decrease in motoric movement in the upper and lower extremities, muscle power at grade 1 in the inferior extremity, and grade 4 in the superior extremity. Tonus decreased in both inferior extremities and physiological reflexes + 2/ + 2. In the inferior and superior extremities, pathological reflexes were negative, and reflexes were sensors within the standard limit.

Complete blood count showed that the rates of hemoglobin were 16.9 g/dL, leucocytes were 21,900 μ L, and thrombocytes were 360,000 μ L. Meanwhile, the other rates included blood sugar 109 mg/dL, urea 68 mg/dL, serum creatinine: 1.02 U/L, SGPT 87 U/L, SGOT 47 U/L, natrium 136 mmol/L, potassium 2.9 mmol/L, chloride 98 mmol/L, total cholesterol 177 mg/dl, high-density lipoprotein 36 mg/dL, low density lipoprotein 49 mg/dL, and D Dimer 550 ng/mL. No abnormality was found in the chest X-ray on the first day positive for COVID-19 (Figure 1). The CT scan head found multiple lacunar infarcts in nuclei lentiform bilateral (Figure 2).

The patient's nerve conduction study (NCV) and electromyography (EMG) (Table 1) showed prolonged distal latency on the left median motor, the right peroneal motor, the left tibial motor, the right tibial motor, and the right ulnar motor nerves (L20,0, R29,1, L12,0, R13,9, R10,6 ms) and reduced amplitude (L0,5, R0,0, L0,6, R1,0, R0,9 mV). The right median motor nerve showed prolonged distal onset latency (23,4 ms), reduced amplitude (0,3 mv), and decreased conduction velocity (Wrist-Elbow, 44 in/s). The left peroneal motor nerve showed prolonged distal onset latency (17,2 ms), reduced amplitude (0,1 mv), and decreased conduction velocity (Poplt-B Fib, 19 in/s). The left ulnar motor nerve showed prolonged distal onset latency (6,8 ms), reduced amplitude (1,0 mv), and decreased conduction

Figure 1. Chest X-ray patient shows no abnormality in the lung parenchyma.



velocity (B Elbow-Wrist, 20 in/s). The left median sensory nerve showed no response (Wrist) and no response (Elbow). The right median sensory, the left ulnar sensory, and the right ulnar sensory nerves showed reduced amplitude (R1,5, L4,9, R1,5 μV).

F-wave studies indicated the following results. The left median F wave had prolonged latency (74.35 ms), which was also found in the right median F wave (78.28 ms). The left ulnar F wave also had prolonged latency (62.43 ms), while the right ulnar F wave showed no response. Left vs right comparison data for the median F wave indicated an abnormal L-R latency difference (3.93 ms). The NCV and EMG indicated demyelinating sensorimotor polyneuropathy suitable for GBS-AIDP subtype.

Based on the EMG results, the patient immediately received 400 mg/kg of intravenous immunoglobulin (IVIg) for five days. During the first day of IVIg administration, the patient’s double vision disappeared. On the second day, the patient could cough effectively, and learn to swallow, and the extremity weakness was improving daily. After seven days post-IVIg treatment, the patient was discharged from the hospital. The patient no longer needed a ventilator and could breathe

Figure 2. CT scan head found multiple lacunar infarct nuclei lentiform bilateral.

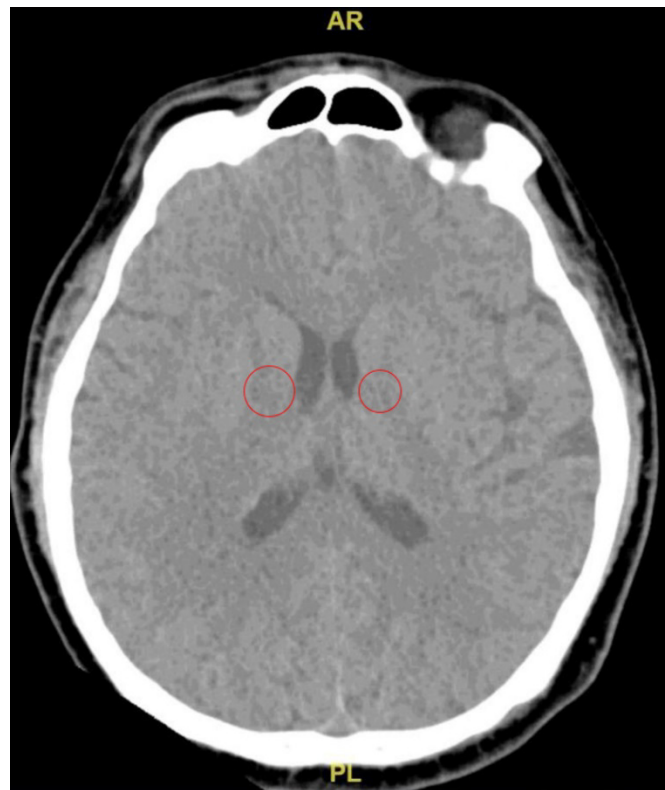


Table 1. Nerve conduction studies.

Nerve	Latency (ms)	Amplitude (mV)	Conduction velocity (m/s)	F-Wave Latency
Left Median Motor				
Wrist	20.0	0.5	58	74.35
Elbow	23.3	0.4		
Right median motor				
Wrist	23.4	0.3	44	78.28
Elbow	28.8	0.2		
Left Peroneal Motor				
Ankle	17.2	0.1	43	
B Fib	22.3	0.1	19	
Poplt	25.4	0.1		
Right Peroneal motor				
Ankle	29.1	0.0	100	
B Fib	31.3	0.0	47	
Left Tibial Motor				
Ankle	12.0	0.6	54	
Knee	17.6	0.5		
Right Tibial Motor				
Ankle	13.9	1.0	39	
Knee	21.5	0.5		
Left ulnar motor				
Wrist	6.8	1.0	20	62.43
B Elbow	17.5	0.5		
Right ulnar motor				
Wrist	10.6	0.9	54	No response
B Elbow	17.5	0.5		
Left median sensory				
Wrist	-	-	-	
Elbow	-	-	-	
Right median sensory				
Wrist	1.3	1.5	108	
Left ulnar sensory				
Wrist	2.5	4.9	56	
Right ulnar anti sensory				
Wrist	1.8	1.5	78	

normally, but he still could not walk properly because of muscle wasting. The patient underwent physical therapy for three months and was back to regular activity without any neurological deficit.

Discussion and literature review

The co-occurrence of cerebrovascular accident and autoimmunity is a rare neurological condition in COVID-19 patients. Delayed diagnosis of this condition will put patients in high morbidity and mortality especially patients with respiratory failure complications. In this case report, the patient presented with multiple infarct lacunars and GBS with mild respiratory symptoms. Respiratory failure in this patient might have been caused by progressive weakness of both the inspiratory and the expiratory muscles. The patients also had difficulties swallowing and diplopia. The mechanism of this case might be caused by infection of SARS-CoV-2 induces severe systemic inflammation, neuroinflammation, and direct viral infection that led to neurologic autoimmune disorder and microvascular thrombosis which led to multiple infarct lacunar.

After SARS-CoV-2 infection, there will be an increase in inflammatory cytokines such as interleukin-6, activities of T-lymphocytes, endothelial cells, and macrophages. Inflammation leads to cytokine release syndrome (CRS), which is characterized by systemic inflammation and organ dysfunction [11]. These conditions can lead to vascular leakage, activation of the complement and coagulation cascade, and ultimately organ damage, including neural damage [12].

This patient presented GBS without a history of autoimmune disease before. GBS is an infection-associated, immune-mediated illness of the peripheral nerves and nerve roots. In GBS, serum antibodies are directed against gangliosides, which are abundant in the axolemma and other peripheral nerve components. Complement activation, macrophage infiltration, and oedema are standard features of peripheral nerves and nerve roots damages in GBS patients [13].

Axonal GBS presents with inflammatory oedema of the proximal nerve trunks, particularly in the spinal nerves. The degeneration of the primary axon occurs without inflammation or demyelination [14]. Intracranial cytokine storms result in blood-brain-barrier breakdown and enhance leucocyte migration [15]. Prolonged SARS-CoV-2 infection exposure leads to increased T cell activation and immune responses, in which effector cell growth predominates and causes lymphopenia. This condition may lead to failure in

peripheral tolerance maintenance and effector T cell activation with autoimmune potential. Loss of self-tolerance is a mechanism that shows an association between lymphopenia and autoimmunity [16].

For GBS patients with COVID-19, cytokine storm will increase IL-6, IL-1 β , IL-17, TNF- α , IFN- γ and another chemokine. In the acute phase of GBS, TNF- α serum will increase and correlate with its clinical severity and decrease IVIG or plasma exchange treatment. To date, the increase of IL-17 serum has been linked to myelin damage via Schwann cell-mediated demyelination. Furthermore, IL-17 and IL-22 serum levels in CSF correlate with the severity of GBS on disability scale scores (GDSs) at the acute phase [17]. The Th1 and Th17 serum levels in the blood significantly increase in GBS patients, while the number of circulating Th17 cells and IL-17A decreases after IVIG treatment [18]. This might explain why the patient's condition in this case improved after receiving the IVIG.

Neurological symptoms were found in the patient five days after respiratory symptoms. Ellul *et al.* reported that neurological symptoms started at a median of seven days (range of 7 to 24 days) after respiratory or systemic features. However, two patients developed febrile illness seven days after the onset of GBS [19].

The GBS-AIDP type confirms the existing literature showing AIDP is the most frequent GBS variation in COVID-19 patients. About 66% of GBS cases in COVID-19 are AIDP type [20]. A systematic review by Aladawi *et al.* revealed that the predominant EMG variant of GBS was AIDP (59 patients), followed by AMSAN (10 cases) and AMAN (8 cases). Moreover, the use of immunomodulatory therapy for GBS was verified in 89 studies. There were 72 patients treated with IVIG, ten with plasmapheresis (PLEX) and seven with combined IVIG and PLEX [21].

Electromyography will help clinicians with different GBS subtypes. Typical findings on electromyography in GBS are prolonged or abnormal F waves, absent H reflexes, reduced motor conduction velocities, and absent or diminished sensory action potentials [22]. In this case, the patient presented with prolonged F waves in the right median and left ulnar. The right ulnar F wave had no response with the conclusion of demyelinating sensorimotor polyneuropathy suitable for GBS-AIDP type.

Besides autoimmune conditions, the over-exuberance response of the immune system results in a cytokine storm in the brain. Immune cells release many cytokines like IL-2, IL-6, IL-10, IL-7, TNF- α , and granulocyte colony-stimulating factors. These all cause

hyperinflammation, severe encephalopathy, and stroke [15].

In multiple lacunar infarcts, SARS-CoV-2 has been linked to triggering CNS vasculitis by an inflammatory response mediated by the cytokine storm, especially IL-6. This mechanism, through viral replication, causes direct vascular injury or destruction. The virus binding to ACE II receptors in CNS damages endothelial cells, promoting inflammation and thrombosis. Autoregulatory function causes an increase in blood pressure leading to vessel wall damage predisposing to dissections [23].

This case showed multiple infarct lacunar in the nucleus lentiform bilateral. Lacunar infarct strokes typically present as an acute manifestation of the chronic condition. This lacunar infarct is less likely to leave patients physically disabled. There are several mechanisms by which lacunar stroke can occur, like micro embolism, vasospasm, lipo hyalinosis or fibrinoid necrosis, and arteriolar endothelial dysfunction. Evidence of direct viral infection of the endothelial cell and diffused endothelial inflammation shows widespread endothelial dysfunction that leads to ischemia and tissue infarction [24].

The association between GBS and multiple lacunar infarcts occurs in that autoimmune disorders can increase the risk of ischemic stroke risk through various mechanisms, including systemic inflammation [25]. Another mechanism is shown by ischemic stroke which is followed by aseptic inflammation. This mechanism will change the brain tissue and expose the co-stimulatory molecules of the immune system and the neuronal antigens [26]. This immune activation may cause secondary tissue injury.

The patient had some unique features compared to recently described cases COVID-19 cases. This patient presented with Guillain Barre Syndrome accompanied by multiple infarct lacunar, with the main neurological symptom appearing after five days of positive COVID-19. The patient received IVIG as therapy for GBS, and the issue was ultimately resolved. Recognizing the neurologic symptoms of COVID-19 and early diagnosis can provide a better prognosis for the patients.

Conclusions

The presence of ACE2 receptors in almost every organ of the human body makes various symptoms of COVID-19 occur besides respiratory symptoms. We reported an uncommon presentation of a COVID-19 patient with GBS-AIDP type and multiple lacunar infarcts without a prior history of autoimmune disease or stroke. Neuroinvasive SARS-CoV-2 could be the

underlying cause of this disorder. Due to this, patients with neuromuscular and neurovascular disease should be screened for COVID-19 and vice versa.

Ethics statement

The authors declare that appropriate written informed consents were obtained to publish this case report and accompanying images.

References

1. World Health Organization (2022) WHO coronavirus (COVID-19) dashboard. Available: <https://Covid19.Who.Int/1>. Accessed: 29 July 2022.
2. Virani A, Rabold E, Hanson T, Haag A, Elrufay R, Cheema T, Balaan M, Bhanot N (2020) Guillain-Barré syndrome associated with SARS-CoV-2 infection. *IDCases* 20: e00771. doi: 10.1016/j.idcr.2020.e00771.
3. Ahmed JO, Ahmad SA, Hassan MN, Kakamad FH, Salih RQ, Abdulla BA, Rahim Fattah FH, Mohammed SH, Ali RK, Salih AM (2022) Post COVID-19 neurological complications; a meta-analysis. *Ann Med Surg* 76: 103440. doi: 10.1016/j.amsu.2022.103440.
4. Visco V, Vitale C, Rispoli A, Izzo C, Virtuoso N, Ferruzzi GJ, Santopietro M, Melfi A, Rusciano MR, Maglio A, Di Pietro P, Carrizzo A, Galasso G, Vatrella A, Vecchione C, Ciccarelli M (2022) Post-COVID-19 syndrome: involvement and interactions between respiratory, cardiovascular and nervous systems. *JCM* 11: 524. doi: 10.3390/jcm11030524.
5. Ali L, Muhammad A, Khan A, Mohammed I, Janjua I, Zada Y, Sharif M, Naeem M, Iqar A, Haroon KH (2022) Acute neurological manifestations of COVID-19 patients from three tertiary care hospitals in Qatar. *Cureus* 14: e23150. doi: 10.7759/cureus.23150.
6. Akhter N, Ahmad S, Alzahran FA, Dar SA, Wahid M, Haque S, Bhatia K, Almalki SS, Alharbi RA (2020) Impact of COVID-19 on the cerebrovascular system and the prevention of RBC lysis. *Eur Rev Med Pharmacol Sci* 24: 10267–10278.
7. Elshereye A, Erdinc B (2020) Multiple lacunar cerebral infarcts as the initial presentation of COVID-19. *Cureus* 12: e9638. doi: 10.7759/cureus.9638.
8. Khan F, Sharma P, Pandey S, Sharma D, Vijayarvarman V, Kumar N, Shukla S, Dandu H, Jain A, Garg RK, Malhotra HS (2021) COVID-19-associated Guillain-Barre syndrome: postinfectious alone or neuroinvasive too? *J Med Virol* 93: 6045–6049. doi: 10.1002/jmv.27159.
9. Abu-Rumeileh S, Abdelhak A, Foschi M, Tumani H, Otto M (2021) Guillain-Barré syndrome spectrum associated with COVID-19: an up-to-date systematic review of 73 cases. *J Neurol* 268: 1133–1170. doi: 10.1007/s00415-020-10124-x.
10. Mao L, Jin H, Wang M, Hu Y, Chen S, He Q, Chang J, Hong C, Zhou Y, Wang D, Miao X, Li Y, Hu B (2020) Neurologic manifestations of hospitalized patients with coronavirus disease 2019 in Wuhan, China. *JAMA Neurol* 77: 683. doi: 10.1001/jamaneurol.2020.1127.
11. Nugroho CW, Suryantoro SD, Yuliasih Y, Rosyid AN, Asmarawati TP, Andrianto L, Setiawan HW, Mahdi BA, Windradi C, Agustin ED, Fajar JK (2021) Optimal use of tocilizumab for severe and critical COVID-19: a systematic review and meta-analysis. *F1000Res* 10: 73. doi: 10.12688/f1000research.45046.1.

12. Abdullahi A, Candan SA, Soysal Tomruk M, Elibol N, Dada O, Truijen S, Saeys W (2021) Is Guillain–Barré syndrome associated with COVID-19 infection? a systemic review of the evidence. *Front Neurol* 11: 566308. doi: 10.3389/fneur.2020.566308.
13. Leonhard SE, Mandarakas MR, Gondim FAA, Bateman K, Ferreira MLB, Cornblath DR, Van Doorn PA, Dourado ME, Hughes RAC, Islam B, Kusunoki S, Pardo CA, Reisin R, Sejvar JJ, Shahrizaila N, Soares C, Umapathi T, Wang Y, Yiu EM, Willison HJ, Jacobs BC (2019) Diagnosis and management of Guillain–Barré syndrome in ten steps. *Nat Rev Neurol* 15: 671–683. doi: 10.1038/s41582-019-0250-9.
14. Berciano J (2022) Axonal pathology in early stages of Guillain–Barré syndrome. *Neurologia* 37: 466–479. doi: 10.1016/j.nrleng.2020.08.001.
15. Yavarpour-Bali H, Ghasemi-Kasman M (2020) Update on neurological manifestations of COVID-19. *Life Sciences* 257: 118063. doi: 10.1016/j.lfs.2020.118063.
16. Katz-Agranov N, Zandman-Goddard G (2021) Autoimmunity and COVID-19 – the microbiotal connection. *Autoimmun Rev* 20: 102865. doi: 10.1016/j.autrev.2021.102865.
17. Li S, Yu M, Li H, Zhang H, Jiang Y (2012) IL-17 and IL-22 in cerebrospinal fluid and plasma are elevated in Guillain–Barré syndrome. *Mediators Inflamm* 2012: 1–7. doi: 10.1155/2012/260473.
18. Hussain FS, Eldeeb MA, Blackmore D, Siddiqi ZA (2020) Guillain Barré syndrome and COVID-19: possible role of the cytokine storm. *Autoimmun Rev* 19: 102681. doi: 10.1016/j.autrev.2020.102681.
19. Ellul MA, Benjamin L, Singh B, Lant S, Michael BD, Easton A, Kneen R, Defres S, Sejvar J, Solomon T (2020) Neurological associations of COVID-19. *Lancet Neurol* 19: 767–783. doi: 10.1016/S1474-4422(20)30221-0.
20. Sriwastava S, Kataria S, Tandon M, Patel J, Patel R, Jowkar A, Daimi M, Bernitsas E, Jaiswal P, Lisak RP (2021) Guillain Barré syndrome and its variants as a manifestation of COVID-19: a systematic review of case reports and case series. *J Neurol Sci* 420: 117263. doi: 10.1016/j.jns.2020.117263.
21. Aladawi M, Elfil M, Abu-Esheh B, Abu Jazar D, Armouti A, Bayoumi A, Piccione E (2022) Guillain Barre syndrome as a complication of COVID-19: a systematic review. *Can J Neurol Sci* 49: 38–48. doi: 10.1017/cjn.2021.102.
22. Carpenter K, Iqbal A, Singh R, Deepika K, Koritala T, Jain N, Alur RS, Adhikari R, Mellekate VS (2022) COVID-19 infection and Guillain-Barre syndrome: a case series. *Cureus* 14: e21998. doi: 10.7759/cureus.21998.
23. Al-Mufti F, Becker C, Kamal H, Alshammari H, Dodson V, Nuoman R, Dakay K, Cooper J, Gulko E, Kaur G, Sahni R, Scurlock C, Mayer SA, Gandhi CD (2021) Acute cerebrovascular disorders and vasculopathies associated with significant mortality in SARS-CoV-2 patients admitted to the intensive care unit in the New York epicenter. *J Stroke Cerebrovasc Dis* 30: 105429. doi: 10.1016/j.jstrokecerebrovasdis.2020.105429.
24. Chouksey D, Rathi P, Garg R, Prabhaskar R (2021) Lacunar stroke in COVID-19. *Ro J Neurol* 20: 121–122. doi: 10.37897/RJN.2021.1.18
25. Parikh NS, Merkler AE, Iadecola C (2020) Inflammation, autoimmunity, infection, and stroke: epidemiology and lessons from therapeutic intervention. *Stroke* 51: 711–718. doi: 10.1161/STROKEAHA.119.024157.
26. Tsygan NV, Trashkov AP, Litvinenko IV, Yakovleva VA, Ryabtsev AV, Vasiliev AG, Churilov LP (2019) Autoimmunity in acute ischemic stroke and the role of blood-brain barrier: the dark side or the light one? *Front Med* 13: 420–426. doi: 10.1007/s11684-019-0688-6.

Corresponding author

Alfian Nur Rosyid
Pulmonology and Respiratory Medicine
Mulyorejo Campus C Universitas Airlangga,
Surabaya, Indonesia.
Tel: +62 813 5012 5649
Email: alfian-n-r-10@fk.unair.ac.id

Conflict of interests: No conflict of interests is declared.