

Case Report

A fatal case of Ecthyma Gangrenosum in a critically ill and immunocompromised patient

Marija Tomanovic¹, Vesna Reljic^{1,2}, Jelena Peric^{1,2}, Dubravka Zivanovic^{1,2}

¹ Clinic of Dermatology and Venereology, University clinical center of Serbia, Belgrade, Serbia

² School of medicine, University of Belgrade, Belgrade, Serbia

Abstract

Introduction: This brief picture-oriented case report focuses on typical skin lesions in a patient who developed *Ecthyma gangrenosum* and pseudomonal sepsis after extensive immunosuppressive therapy for *Pemphigus vulgaris*.

Case presentation: The patient was immunosuppressed with high doses of glucocorticoids and azathioprine; the follow-up after the treatment was not carried out well due to the pandemic conditions and because the patient herself got a Covid infection, which resulted in the development of pseudomonal sepsis and *Ecthyma gangrenosum*. The outcome was fatal despite extensive broad-spectrum antibiotic therapy, plasmapheresis, and intravenous immunoglobulins.

Conclusions: Infections with *Pseudomonas aeruginosa* have become a real concern in hospital-acquired infections, especially in critically ill and immunocompromised patients, because of multi-drug resistance in the first place.

Key words: Ecthyma gangrenosum; *Pseudomonas aeruginosa*; sepsis; immunocompromised; Pemphigus vulgaris.

J Infect Dev Ctries 2023; 17(11):1654-1657. doi:10.3855/jidc.18040

(Received 06 February 2023 – Accepted 24 May 2023)

Copyright © 2023 Tomanovic *et al.* This is an open-access article distributed under the Creative Commons Attribution License, which permits unrestricted use, distribution, and reproduction in any medium, provided the original work is properly cited.

Introduction

Ecthyma gangrenosum (EG) is a rare and often life-threatening opportunistic infection that requires urgent treatment. EG causes localized skin and subcutaneous fat tissue necrosis, leading to multiple ulcerations surrounded by local hyperemia. Two types of EG have been described: the classical one (with bacteremia) - secondary to hematogenous spread - and the localized one or the non-septicemic form, in which the lesions are located at the site of inoculation of the organism into the skin [1]. The most commonly affected are immunosuppressed and immunocompromised patients [2]. The prognosis is poor, especially in individuals with underlying immunodeficiency. The immunocompromised patients who develop EG lesions without bacteremia reportedly have a better prognosis [3]. EG requires urgent intervention as it is associated with a high mortality rate, estimated to range from 38% to 77%, even with an appropriate treatment [4]. If the diagnosis is suspected, prompt empiric coverage with dual antipseudomonal antibiotics is recommended until the causative organism(s) is isolated, especially in patients with risk factors.

Case presentation

We present a fatal case of Ecthyma gangrenosum in a 26-year-old Caucasian female with a previously diagnosed autoimmune blistering disease *Pemphigus vulgaris* (PV). On admission, typical lesions for PV - multiple erosions covered with crusts on the scalp, face, and trunk - were present (Figures 1 A and B). Before admission, the patient had already been treated with prednisone (1 mg/kg p.d), and azathioprine (1.67 mg/kg p.d), which were continued. A systemic antibiotic therapy was also initiated according to the antibiogram findings of erosion swabs (*Pseudomonas aeruginosa* and *Staphylococcus aureus* were isolated). The control bacteriological swabs were sterile, so pulse glucocorticoid therapy was initiated (Dexamethasone 1.5 mg/kg for three consecutive days). An immediate therapeutic response was achieved, and the epithelization of erosions started a few days later (Figures 1C and 1D), but the patient was discharged at her request.

Seven days later, she returned in a severely deteriorated condition (Figure 2A). *Pseudomonas aeruginosa* was detected in bacteriological swabs; moxifloxacin was introduced.

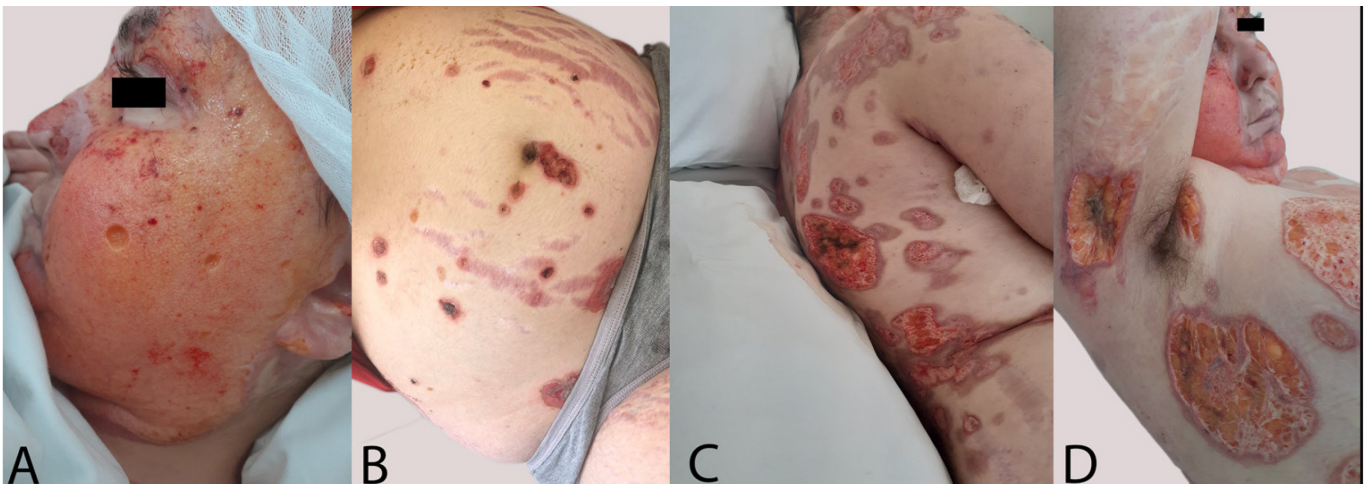
Figure 1. A and B: multiple erosions covered with crusts on the face, on admission; **B and C:** epithelization of the lesions after the first cycle of the pulse glucocorticoid therapy.

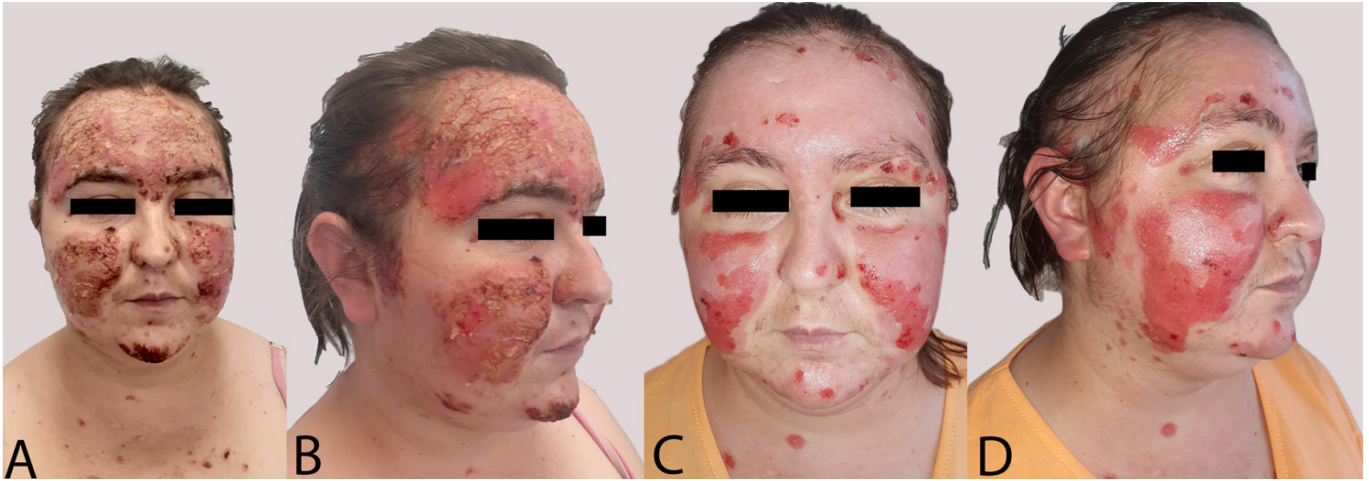

Figure 2. Skin lesions after discharge. **A:** face; **B:** scalp and trunk; **C:** back.

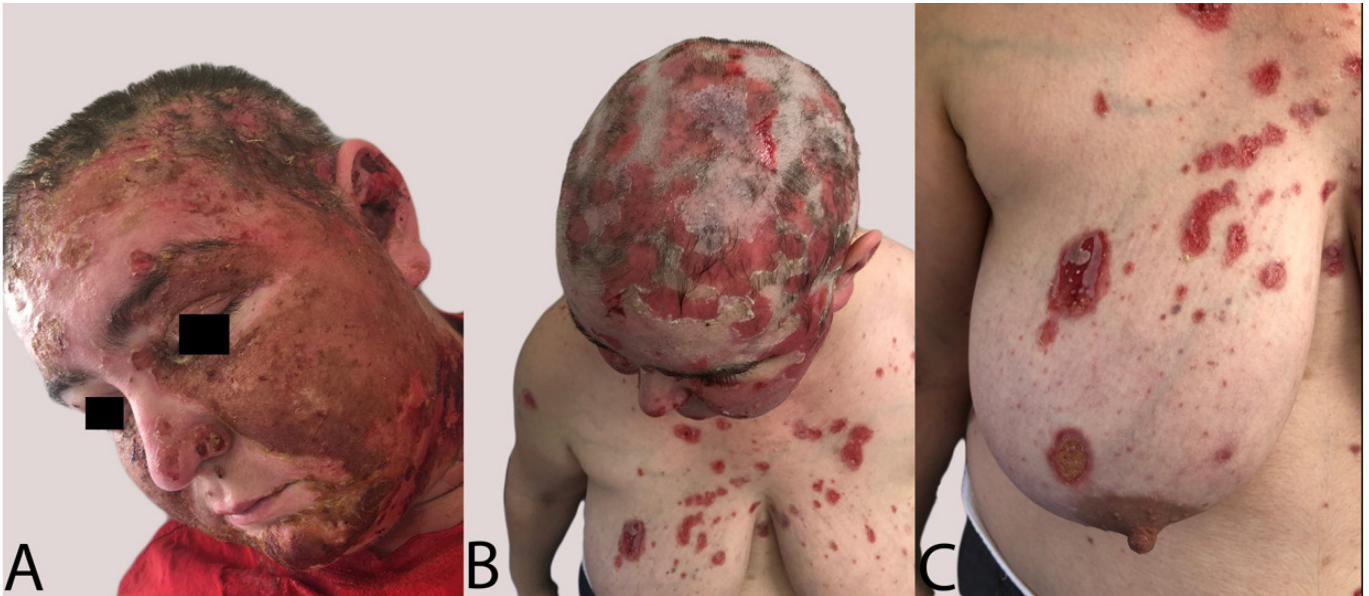

Figure 3. A: An ulcer on the face; **B:** Necrotic ulcers covered with crusts on the abdomen; **C and D:** deep, extensive ulcers.



After taking sterile control bacteriological swabs, a second cycle of pulse therapy was administered, but a few days later, the patient was positive for the SARS-CoV-2 infection on a real-time PCR test. The azathioprine was discontinued, and the patient was discharged and referred to a COVID hospital. Two weeks later, she returned to our department in a severe condition, febrile, with high inflammation markers (CRP 502.7 mg/mL, D dimer 3.79 mg/L, PCT 20 ng/mL, Ferritin 1868 µg/L); no neutropenia was recorded. More extensive erosions covered with crusts were clinically present (Figures 2 B and C). Soon upon admission, hemorrhagic blisters and necrotic ulcers on the head, neck, trunk, and limbs occurred (Figures 3 A and B).

Several bacteriological swabs (three times per week) and hemocultures were taken during the hospital stay, all showing *Pseudomonas aeruginosa* (PA). First, a multidrug-resistant (MDR) PA and then in the further course an extensively drug-resistant (XDR) PA (sensitive only to colistin) were isolated. Due to high levels of D dimer, a thoracic computerized tomography (CT) and CDS of lower extremities were performed; multiple thrombi in the lungs and femoral arteries were detected, despite the LMWH therapy.

Plasmapheresis was performed and intravenous immunoglobulins were administered (before diagnosing thrombotic masses); transfusions, albumin, and electrolyte recouplement, as well as the extensive antibiotic therapy, were all administered according to the antibiogram findings, including polymyxins, glycopeptides, and carbapenems. Unfortunately, new lesions suggestive of EG occurred on the face, trunk, extremities, and perineal area. The existing erosions deepened, forming extensive ulcers (Figures 3C and 3D). As the last hemoculture was positive on *Candida krusei*, Diflucan and Amphotericin B were also introduced. Despite all treatments, the outcome was fatal.

Discussion

Ecthyma gangrenosum is a rare, life-threatening skin infection clinically presented as hemorrhagic blisters and gunmetal-gray-infracted macules/papules rapidly evolving into necrotic ulcers with an erythematous halo [5]. The lesions may be multiple or solitary, followed by systemic signs and symptoms indicative of sepsis (high body temperature, malaise, hypotension). The predilection sites are the gluteal/perineal area (57%), extremities (30%), trunk (6%), and face (6%); the disease was present in all these areas in our patient [2]. It affects both genders equally

with no age predilection. 62% to 75% of affected individuals have an underlying immunodeficiency, but there are also reported cases in otherwise healthy patients [6]. The most frequent etiological factor is *Pseudomonas aeruginosa* (PA), but it can be caused by other bacteria, fungi, and viruses [7,8]. Some authors suggest the term “Ecthyma gangrenosum-like” lesions for those not caused by PA [2]. The form of EG with bacteremia is more common; it is considered septic vasculitis and is often complicated by a septic shock, which is why prompt and aggressive treatment is required [9].

Besides immunosuppressive therapy, the predisposing factors for developing EG are neutropenia, multiple myeloma, leukemia, malnutrition, diabetes mellitus, and extensive burns [10]. Our patient did not have neutropenia but was immunosuppressed due to previous and ongoing treatment for an autoimmune blistering disorder (PV). In addition, a previous COVID-19 infection also led to an immunological impairment.

Based on clinical findings, the treatment should be initiated immediately without waiting for blood culture reports [11]. In addition, one should start the empiric dual antibiotic anti-pseudomonal therapy as soon as possible. Traditionally, PA is one of a few bacterial pathogens for which a combination therapy is routinely considered. Two commonly cited reasons are the potential for synergistic efficacy and the potential to reduce the emergence of resistance [12]. Eight categories of antibiotics are mainly used to treat PA infections, including aminoglycosides, carbapenems, cephalosporins, fluoroquinolones, penicillin with β-lactamase inhibitors in combination with clavulanic acid or tazobactam, monobactams, Fosfomycin, and polymyxins [12].

The mortality of patients with Ecthyma gangrenosum and pseudomonal sepsis ranges from 20% to 77%, while in the absence of sepsis, it is 8% [9]. The major problem leading to high mortality lies in the rapid and ongoing spread of drug-resistant strains (MDR and XDR or pan-drug-resistant (PDR) [12,13]. Therefore, many approaches to developing novel anti-infectives are currently being pursued. The resistance to cephalosporins and fluoroquinolones has led to an increased usage of carbapenems, with the consequent rapid emergence of carbapenem-resistant species [13,14]. The shortage of effective antibiotics against MDR Gram-negative strains and the increased risk of toxicity in frail patients make optimal therapy extremely complicated.

In the presented case, it is difficult to assess whether and to what extent Pemphigus itself contributed to the development of EG. The patient was immunosuppressed with high doses of glucocorticoids and azathioprine, and the follow-up after the treatment was not carried out adequately due to the COVID-19 pandemic. Despite the early treatment and combination of multiple antibiotic therapy, the outcome was fatal.

We can speculate that thrombotic masses in our patient's lungs and femoral arteria can result from pseudomonas bacteriemia and the formation of septic emboli, but also thrombosis due to the previous COVID-19 infection. Unfortunately, a biopsy was not performed.

Conclusions

Infections with *Pseudomonas aeruginosa* have become a real concern in hospital-acquired infections, especially in critically ill and immunocompromised patients. One of the significant outcome factors is the delayed administration of appropriate antibiotics and the possible occurrence of resistant strains. Therefore, timely administration of adequate antibiotic therapy is crucial for survival in these patients.

References

1. Marques, SA, Abbade, LPF (2020) Severe bacterial skin infections. *An Bras Dermatol* 95: 407-417. doi: 10.1016/j.abd.2020.04.003.
2. Vaiman M, Lazarovitch T, Heller L, Lotan G (2015) Ecthyma gangrenosum versus ecthyma-like lesions: should we separate these conditions? *Acta Dermatovenerol Alp Pannonica Adriat* 24: 69-72. doi: 10.15570/actaapa.2015.18.
3. Martínez-Longoria CA, Rosales-Solis GM, Ocampo-Garza J, Guerrero-González GA, Ocampo-Candiani J (2017) Ecthyma gangrenosum: a report of eight cases. *An Bras Dermatol* 92: 698-700. doi: 10.1590/abd1806-4841.20175580.
4. Russomanno K, Cardis M, Kirkorian AY (2021) Ecthyma gangrenosum: The critical role of biofilms and other mechanisms of antibiotic resistance and implications for management. *Pediatr Dermatol* 38: 458-460. doi: 10.1111/pde.14496.
5. Wu CT, Huang, JL (2010) Multiple ecthyma gangrenosum in a healthy infant with community-acquired *Pseudomonas aeruginosa* sepsis. *Pediatr Emerg Care* 26: 750-1. doi: 10.1097/PEC.0b013e3181f39b5e.
6. Vaiman M, Lazarovitch T, Heller L, Lotan G (2015) Ecthyma gangrenosum and ecthyma-like lesions: review article. *Eur J Clin Microbiol Infect Dis* 34: 633-9. doi: 10.1007/s10096-014-2277-6.
7. Fang KC, Lin FJ, Chen CH, Huang YN, Lan J, Tseng HC, Huang YC (2022) Ecthyma gangrenosum secondary to methicillin-sensitive staphylococcus aureus in an atopic child with transient neutropenia: a case report and review of the literature. *Diagnostics (Basel)* 12: 1683. doi: 10.3390/diagnostics12071683.
8. Jamal A, Saleem A, Rezwani F, Sheikh A, Shamsi T (2022) Successful management of colistin- and carbapenem-resistant *Klebsiella pneumoniae*-associated ecthyma gangrenosum in acute myeloid leukemia: A rare complication. *SAGE Open Med Case Rep* 10. doi: 10.1177/2050313X221102113.
9. Shah M, Crane JS (2022) Ecthyma gangrenosum. StatPearls Publishing, Treasure Island (FL)
10. Korte AKM, Vos JM (2017) Ecthyma gangrenosum. *N Engl J Med* 377: e32. doi: 10.1056/NEJMicm1702302.
11. Gargouri L, Maaloul I, Kamoun T, Maalej B, Safi F, Majdoub I, Hachicha M, Mahfoudh A (2015) Ecthyma gangrenosum: A manifestation of community-acquired *Pseudomonas aeruginosa* septicemia in three infants. *Arch Pediatr* 22: 616-20. doi: 10.1016/j.arcped.2015.03.006.
12. Bassetti M, Vena A, Croxatto A, Righi E, Guery B (2018) How to manage *Pseudomonas aeruginosa* infections. *Drugs Context* 212527. doi: 10.7573/dic.212527.
13. Castaldo N, Givone F, Peghin M, Righi E, Sartor A, Bassetti M (2017) Multidrug-resistant *Pseudomonas aeruginosa* skin and soft-tissue infection successfully treated with ceftolozane/tazobactam. *J Glob Antimicrob Resist* 100-102. doi: 10.1016/j.jgar.2017.02.012.
14. Perez F, Bonomo RA (2015) Editorial commentary: Bloodstream infection caused by extended-spectrum β -lactamase-producing Gram-negative bacteria: how to define the best treatment regimen? *Clin Infect Dis* 60: 1326-9. doi: 10.1093/cid/civ007.

Corresponding author

Marija Tomanovic, MD
 Clinic of Dermatology and Venereology,
 University clinical Center of Serbia
 Pasterova 2, 11 000 Belgrade, Serbia.
 Tel: +381669032623
 Fax: +38112682652
 Email: marijaa.tomanovic@gmail.com

Conflict of interests: No conflict of interests is declared.