

Case Report

Metagenomic Next-Generation Sequencing (mNGS) of cerebrospinal fluid for diagnosis of human herpesvirus 6B encephalitis following transplantation for severe aplastic anemia

Kaile Zhang¹, Jianli Xu¹, Gang Chen¹, Ruixue Yang¹, Ming Jiang¹, Hailong Yuan¹

¹ Hematology Center, the First Affiliated Hospital of Xinjiang Medical University, Xinjiang Institute of Hematology, Urumqi 830054, China

Abstract

Introduction: Human herpesvirus 6B (HHV-6B) encephalitis is common in immunosuppressed patients and presents a diagnostic challenge for physicians. Metagenomic next-generation sequencing (mNGS) may facilitate early diagnosis of HHV-6B encephalitis. Herein, we described a case of HHV-6B encephalitis following transplantation for severe aplastic anemia (SAA) diagnosed by mNGS.

Case summary: A 31-year-old male underwent myeloablative haploid hematopoietic stem cell transplantation for the treatment of SAA. On day + 21 after transplantation, the patient developed symptoms such as sudden epilepsy, drowsiness, memory dislocation, and memory loss. HHV-6B encephalitis was confirmed based on cranial MRI and mNGS of cerebrospinal fluid. Following antiviral therapy with sodium foscarnet, the symptoms improved and HHV-6B was negative by mNGS. There were no serious sequelae. Currently, the patient is in good health and is still under follow-up.

Conclusions: A case of HHV-6B encephalitis after SAA transplantation was diagnosed by mNGS of cerebrospinal fluid in time and was effectively treated with sodium foscarnet.

Key words: Human herpesvirus 6B (HHV-6B); encephalitis; severe aplastic anemia; metagenomic next-generation sequencing.

J Infect Dev Ctries 2024; 18(1):152-157. doi:10.3855/jidc.18152

(Received 28 February 2023 – Accepted 26 June 2023)

Copyright © 2024 Zhang *et al.* This is an open-access article distributed under the Creative Commons Attribution License, which permits unrestricted use, distribution, and reproduction in any medium, provided the original work is properly cited.

Introduction

Human herpesvirus 6B (HHV-6B) encephalitis is a life-threatening infection-related complication after hematopoietic stem cell transplantation, with a morbidity of 0.69 to 11.6%, and a significant mortality rate [1,2]. The diagnosis of HHV-6B encephalitis is clinically challenging due to the lack of specific symptoms and clear diagnostic criteria. Ideally, confirmation of HHV-6B infection requires a pathological examination of tissue samples from the affected part of the patient's brain. However, implementing this method in clinical practice can be challenging. Currently, diagnosis of HHV-6B infection is based on the appearance of acute-onset mental status changes, short-term memory loss, or seizures, the exclusion of other infectious or non-infectious factors, and the detection of HHV-6B DNA in the cerebrospinal fluid [3]. However, HHV-6B encephalitis typically presents as post-transplant acute limbic encephalitis with no significant changes in cerebrospinal fluid protein and cell count and negative magnetic resonance imaging (MRI) findings at disease onset, which makes its initial screening challenging. Metagenomic next-

generation sequencing (mNGS) is an unbiased approach that can theoretically detect all pathogens in a clinical sample and is especially suitable for rare, novel, and atypical etiologies of complicated infectious diseases. Superior diagnostic performance of mNGS has been demonstrated in central system and ocular infections [4-6]. However, the diagnosis of HHV-6B encephalitis after transplantation by mNGS has been rarely reported. Herein, we reported a case of HHV-6B encephalitis following transplantation for severe aplastic anemia (SAA) diagnosed by mNGS.

Case report

Chief complaints

A 31-year-old male patient developed symptoms such as epileptiform seizure, drowsiness, memory dislocation, and memory loss after SAA treatment with myeloablative haploid hematopoietic stem cell transplantation.

History of present illness

Beginning on Jan 31, 2022 (day + 11 after transplantation), the patient presented with a fever

accompanied by sore throat, redness, swelling, and ulceration of the oral mucosa. On Feb 2, 2022 (day + 15 after transplantation), the patient's temperature peaked at 40.8 °C. On Feb 8, although the patient's sore throat and oral ulcerations improved, new dark red skin rashes appeared with desquamation on the head, and dense dark red skin rashes appeared on the chest and abdomen. Acute graft-versus-host disease (GVHD) was considered, and the patient received methylprednisolone sodium succinate (80mg q12h). Throughout this period, the patient was conscious, able to perform daily activities, and had no headaches or dizziness. At 01:13 on Feb 10, 2022 (day + 21 after transplantation), the patient began to foam at the mouth, became unresponsive to calls, experienced convulsions throughout the body with clenched teeth, and had a blood pressure of 174/101mmHg. At 01:25, another epileptic seizure occurred, characterized by stiffness in the upper limbs, claw-like hands with wrists turned downwards, and convulsions throughout the body, which lasted for roughly 30 seconds. Additionally, the patient presented with snoring-like breathing and frothy saliva at the mouth along with a gaze deviation, i.e., both eyes were leaning towards the left. To sedate the patient, Diazepam and mannitol dehydration were administered, which resulted in drowsiness, difficulty following instructions, and illogical responses to questions. A temperature of 38 °C was recorded on the day of the seizure.

History of past illness

On Nov 15, 2021, the patient presented with symptoms of ecchymosis on limbs, systemic scattered purpura, and gingival hemorrhage, with no obvious cause. According to the results of bone marrow biopsy and cellular immunity (such as the Cytogenetic test), the diagnosis was determined as "SAA". The patient and his family members declined to use ATG (Anti-Thymocyte Globulin) for treatment due to its potential adverse effects. Therefore, Cyclosporine A (250 ng/mL) was administered orally. Since December 27, 2021, he developed a fever with a body temperature of up to 38.5 °C as well as a left nasal infection and nasal mass formation. The HLA-matched unrelated fully compatible donor was unavailable. The patient and his family members still declined to receive ATG. Then, the related haploid hematopoietic stem cell transplantation was planned with his sister as a donor, and the matching type was 5/10 (the blood type of the patient and the donor were O and B, respectively).

The busulfex/cyclophosphamide/ATG-based pre-conditioning regimen was administered from January

11, 2022. The donor received granulocyte-colony stimulating factor (8 µg/kg/d) for stem cell mobilization. Bone marrow blood hematopoietic stem cells (mononuclear cells: 1.9×10^8 /kg; CD34⁺ cells: 0.2×10^6 /kg) from the donor were administered on January 18, 2022. Peripheral blood hematopoietic stem cells (mononuclear cells: 5.53×10^8 /kg; CD34⁺ cells: 2.1×10^6 /kg) from the donor were administered on January 19 and 20, 2022.

GVHD prophylaxis included cyclosporine, methotrexate, mycophenolate mofetil, and anti-CD25 monoclonal antibody. Infection prophylaxis was performed according to our center's standard protocol.

The neutrophil count was 1.06×10^9 /L from + 14 days after stem cell transplantation and platelet count was maintained above 30×10^9 /L in a setting of continuous transfusion. The nasal boils and infections completely disappeared. Full-donor chimerism was observed on day 15 and sustained until 8 months after transplantation.

Personal and family history

The patient denied any family history of HHV-6B encephalitis.

Physical examination

Physical examination showed that blood pressure was 174/101mmHg. Both pupils were equally large with a diameter of about 3 mm. There was left lower gaze in both eyes, negative Babinski sign, negative Oppenheim sign, negative Gordon sign, and negative Kernig sign. The muscle tone of the extremities was normal. The muscle strength of both upper limbs was grade 3, and that of both lower limbs was grade 2.

Laboratory examinations

Routine blood test showed a white blood cell count of 12.67×10^9 /L, hemoglobin of 10^5 g/L, and platelet count of 14×10^9 /L. The plasma concentration of tacrolimus was 9.3 ng/mL. Coagulation function showed a prothrombin time of 15 seconds, plasma fibrinogen of 2.1 g/L, and, activated partial thromboplastin time of 43.1 seconds. The serum sodium level was 123 mmol/L. Serum magnesium level was 0.59 mmol/L. Blood potassium level was 3.74 mmol/L. Kidney function was normal with a creatinine level of 86 µmol/L and a urea level of 6.65 µmol/L. Blood glucose level was 11.2 mmol/L.

Imaging examinations

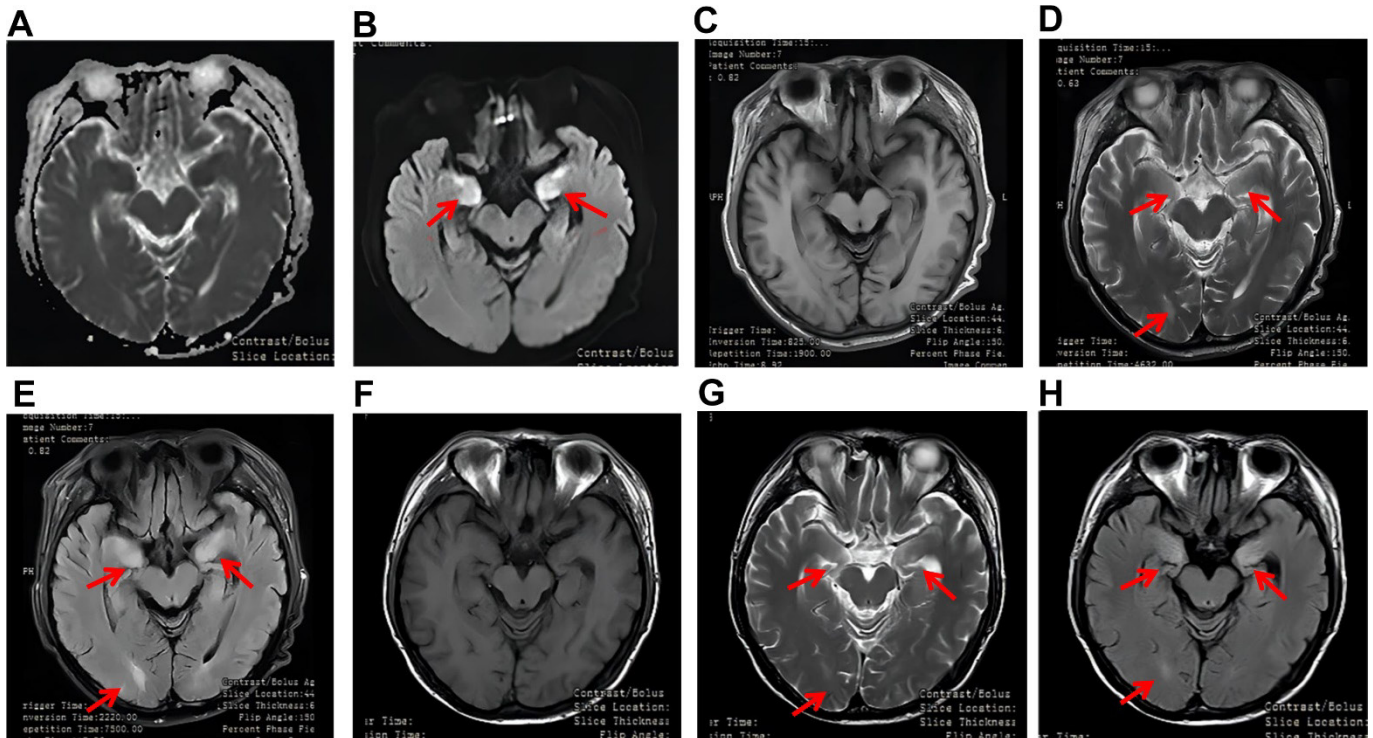
On day + 21 (Feb 10, 2022) after transplantation, the patient developed a seizure, and a cranial CT scan after seizure showed no bleeding.

Table 1. The results of autoimmune encephalitis antibodies in cerebrospinal fluid.

| Autoimmune encephalitis antibody | Detection method | Results |
|---|-------------------|----------|
| Anti-NMDAR receptor antibody | Cell Transfection | Negative |
| Anti-AMPA1 receptor antibody | Cell Transfection | Negative |
| Anti-AMPA2 receptor antibody | Cell Transfection | Negative |
| Anti-LGI1 receptor antibody | Cell Transfection | Negative |
| Anti-CASPR2 receptor antibody | Cell Transfection | Negative |
| Anti-GABABR receptor antibody | Cell Transfection | Negative |
| Anti-DPPX receptor antibody | Cell Transfection | Negative |
| Anti-IgLON5 receptor antibody | Cell Transfection | Negative |
| Anti-GAD65 receptor antibody | Cell Transfection | Negative |
| Anti-GlyR1 receptor antibody | Cell Transfection | Negative |
| Anti-DRD2 receptor antibody IgG | Cell Transfection | Negative |
| Anti-mGluR1 receptor antibody IgG | Cell Transfection | Negative |
| Anti-mGluR5 receptor antibody IgG | Cell Transfection | Negative |
| Anti-GABABR α 1 receptor antibody IgG | Cell Transfection | Negative |
| Anti-GABABR β 3 receptor antibody IgG | Cell Transfection | Negative |
| Anti-Neurexin3 α receptor antibody IgG | Cell Transfection | Negative |

NMDAR: N-methyl-D-aspartate receptor; AMPA1: α -amino-3-hydroxy-5-methyl-4-isoxazolepropionic acid 1 receptor; AMPA2: α -amino-3-hydroxy-5-methyl-4-isoxazolepropionic acid 2 receptor; LGI1: leucine rich glioma inactivated 1 receptor; CASPR2: contactin-associated protein 2 receptor; GABABR: γ -aminobutyric acid type B receptor; DPPX: dipeptidyl-peptidase-like protein-6 receptor; GAD65: glutamic acid decarboxylase 65 receptor; GlyR1: glycine receptor 1; DRD2: Dopamine D2 receptor; mGluR1: metabotropic glutamate receptor 1; mGluR5: metabotropic glutamate receptor 5; GABABR α 1: γ -aminobutyric acid type B receptor α 1; GABABR β 3: γ -aminobutyric acid type B receptor β 3.

Figure 1. Pre-treatment and post-treatment cranial MRI images.



Pre-treatment cranial MRI scan showed a slightly high DWI signal in bilateral hippocampal and parahippocampal gyrus: **A**: No abnormal signal was observed in the ADC sequence of nuclear magnetic resonance; **B**: there was slightly higher MRI DWI sequence in the bilateral hippocampus, parahippocampal gyrus, and left thalamus (arrows); **C**: no abnormal signal was observed in the cranial MRI T1 sequence; **D**: there was slightly long T2 signal in the bilateral hippocampus, parahippocampal gyrus, left thalamus, posterior horn of bilateral ventricles, and right occipital lobe (arrows); **E**: there was slightly high signal in the water suppression sequence in the bilateral hippocampus, parahippocampal gyrus, left thalamus, posterior horn of bilateral ventricles, and right occipital lobe (arrows); **F**: no abnormal signal was observed in the cranial MRI T1 sequence. **G**: Post-treatment MRI showed that compared with before treatment, the long T2 signal in bilateral hippocampus, parahippocampal gyrus, and left thalamus disappeared (arrows); **H**: Post-treatment MRI showed slightly high patchy signal in water suppression sequence in bilateral hippocampal gyrus and parahippocampal gyrus (arrows).

On day + 23, cranial MRI showed slightly long T2 signals in the bilateral hippocampus and parahippocampal gyrus, left thalamus, posterior horn of bilateral ventricles, and right occipital lobe, slightly high signal in water suppression sequences, and slightly high signals in DWI sequences (Figure 1).

Further diagnostic workup

On day + 24, biochemistry analysis of cerebrospinal fluid (CSF) showed that the total number of cells was $1005 \times 10^6/L$, glucose content was 4.7 mmol/L, protein content was 0.78 g/L, chlorine was 111.5 mmol/L, and adenosine dehydrogenase was 5.5 U/L. The results for autoimmune encephalitis were negative (Table 1). The mNGS detection of CSF showed an HHV-6B sequence number of 950 (Figure 2A).

Final diagnosis

The patient was diagnosed with HHV-6B encephalitis.

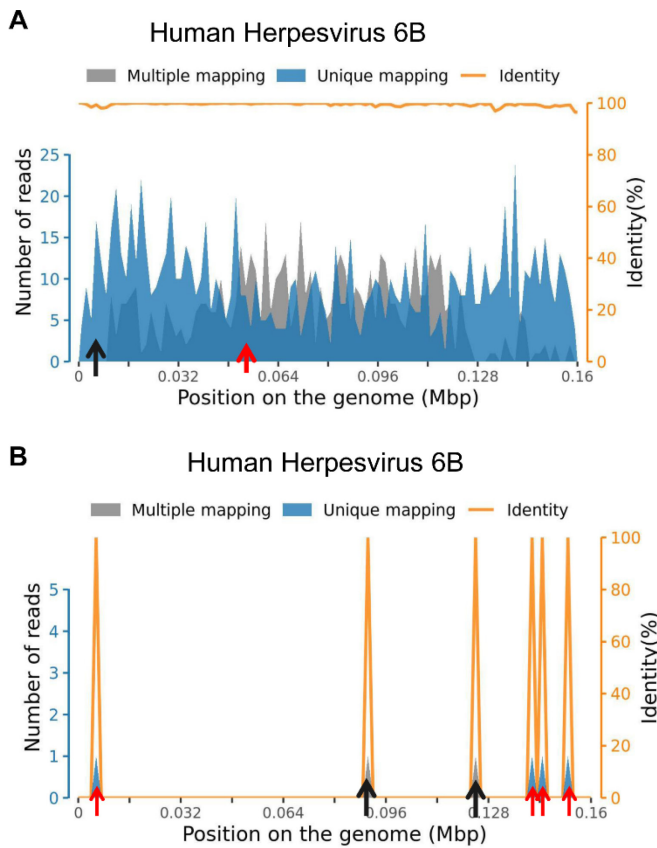
Treatment

Antiviral therapy with foscarnet sodium (40 mg/kg, once per 8 hours) was administrated. Human intravenous immunoglobulin (PH4) (400 mg/kg) was intravenously injected for 5 days. Meanwhile, methylprednisolone sodium succinate was promptly discontinued, and cyclosporine A (maintenance concentration of 250-350 ng/mL) was given intravenously to prevent GVHD. Levetiracetam was also given orally.

Outcome and follow-up

Thereafter, the patient did not have recurrent epilepsy and had gradually improved consciousness, but was in poor mental state, dull response, and memory impairment, manifested as memory weakening, anterograde amnesia, and memory misconstruction. Physical examination showed conjunctival edema of both eyes, normal muscle tone of the extremities, and gradual recovery of muscle strength to grade 3 to 4. Oral administration of cyclosporine A was continued for GVHD prophylaxis. On day + 47, biochemistry analysis of CSF showed that the total number of cells was $155 \times 10^6/L$, glucose content was 3.3mmol/L, protein content was 1.52 g/L, chlorine was 119.9 mmol/L, and, adenosine dehydrogenase was 3.8 U/L. CSF mNGS showed that the HHV-6B sequence number was 4 (Figure 2B). On day + 50, cranial MRI showed a patchy slightly high signal on both hippocampal gyrus and parahippocampal gyrus on the T2 water suppression image, slightly enlarged left ventricular temporal horn, and no obvious abnormal signals in the remaining brain parenchyma (Figure 1). The patient was regularly followed up. He did not have a seizure and the globular conjunctival edema disappeared. He had a good mental state, with normal limb muscle strength, free movement, and only mild memory impairment manifesting as recent memory loss, which is the most common sequelae of HHV-6B encephalitis after antiviral therapy.

Figure 2. CSF mNGS results.



A: Pre-treatment CSF mNGS results. The sequence number of Roseolovirus (black arrow) was 1522 and that of HHV-6B (red arrow) was 950; **B:** Post-treatment CSF mNGS results. The sequence number of Roseolovirus (black arrow) was 6 and that of HHV-6B (red arrow) was 4.

Discussion

HHV-6B encephalitis after hematopoietic stem cell transplantation is a serious and rare complication with a high mortality rate [7,8], which may induce cognitive sequelae [9]. The umbilical cord transplantation is known to be a risk factor for HHV-6B encephalitis [8,10]. The engraftment syndrome and acute GVHD are also important factors for HHV-6B reactivation [2]. In 30-70% of cases, reactivation of HHV-6B can be detected in plasma 2-4 weeks after allogeneic hematopoietic stem cell transplantation [1]. The

glucocorticoids can inhibit the HHV-6B-specific immune response and promote apoptosis of HHV-6B-infected T lymphocytes, leading to the proliferation of HHV-6B [11]. In this report, the patient received haploid hematopoietic stem cell transplantation. He suffered from agranulocytosis for a long time. Moreover, he received immunosuppressants before transplantation (such as cyclosporine A) and received higher doses of pre-conditioning chemotherapy, ATG, glucocorticoids, and cyclosporine A during transplantation. All these factors mentioned above constitute a basis for HHV-6B reactivation.

The diagnosis of HHV-6B encephalitis after hematopoietic stem cell transplantation is difficult, and current guidelines recommend the following criteria for its diagnosis [3]: 1) the diagnosis of HHV-6B encephalitis should be based on HHV-6B DNA in CSF, accompanied by acute onset of mental status changes (encephalopathy), short-term memory loss, or seizures; 2) other possible infectious or non-infectious causes must be excluded; 3) chromosomally integrated human herpesvirus 6B (CIHHV-6B) in donors and recipients should be excluded; 4) If CIHHV-6B is detected, evidence of CIHHV-6B reactivation in CSF or brain tissue is required to confirm CIHHV-6B infection.

It is difficult to determine the cause of infection based on conventional microbiological testing (CMT) and imaging. For clinically suspected HHV-6B encephalitis, early diagnosis and treatment based on timely detection of HHV-6B DNA in CSF is essential to prevent neurological sequelae [12]. It is shown that mNGS has advantages in diagnosing chronic meningitis and encephalitis [13]. The mNGS is a powerful DNA sequencing technique that utilizes second-generation sequencing platforms to rapidly and accurately sequence nucleic acids in clinical samples. The obtained nucleic acid sequences are then compared to known microbial sequence databases to determine the types and proportions of microorganisms present in the sample. This approach enables unbiased and high-throughput sequencing of nucleic acids from clinical specimens, facilitating the rapid and objective detection of pathogenic microorganisms such as viruses, bacteria, fungi, and parasites [14]. The CSF is usually sterile and has a small cell number. Therefore, it is difficult to detect possible RNA viruses, DNA viruses, bacterial, fungal, and parasitic infections by using CMT. More than half of patients with suspected infection are still undiagnosed after repeated CMT, and the diagnosis depends on mNGS and other tests [15,16]. Carbo *et al.* [14] identified the pathogens in 18 immunocompromised patients with mNGS analysis of

CSF, indicating that mNGS has a high sensitivity in immunocompromised patients. In this study, the patient had normal CMT results and was confirmed as HHV-6B encephalitis by CSF mNGS. The result of CSF mNGS became negative after targeted treatments. Therefore, we assume that CSF mNGS is important for the diagnosis of HHV-6B encephalitis.

In the current treatment practice of HHV-6B encephalitis, sodium foscarnet (90 mg/kg bid) or ganciclovir (5 mg/kg bid) is recommended for HHV-6B infection [3]. Toomey *et al* [2] retrospectively analyzed 123 cases in 52 studies, and found that the percentage of death or sequelae in patients who received ganciclovir monotherapy was 63.6%, in patients who received foscarnet monotherapy was 55.3%, and in patients who received foscarnet and ganciclovir combination therapy was 37.5%. Logistic regression analysis showed that foscarnet monotherapy and ganciclovir monotherapy were associated with a higher risk of encephalitis sequelae compared with the foscarnet and ganciclovir combination therapy, but there was no significant difference in terms of mortality. In this study, sodium foscarnet 120 mg/kg/day was administered, and serum electrolytes and kidney function were closely monitored. After 2 weeks of sodium foscarnet treatment, the number of viral sequences in CSF was reduced, the hippocampus and parahippocampal gyrus lesions disappeared on MRI, and the patient only had mild memory dysfunction. Prophylactic ganciclovir or foscarnet has not reduced the incidence of HHV-6B encephalitis [17,18]. However, oral cidofovir may reduce the incidence of HHV-6B viremia [18] but has no clear effect on encephalitis. Therefore, ganciclovir or foscarnet is not currently recommended for the prevention of HHV-6B reactivation or HHV-6B encephalitis in patients receiving transplantation.

Conclusions

HHV-6B encephalitis has an acute onset and presents with serious clinical symptoms including epilepsy. Its diagnosis and differential diagnosis are challenging. Timely CSF mNGS is very important for early identification of the pathogens, especially in the early stage of transplantation, thus improving the early diagnosis, instauration of the treatment, and the long-term survival of patients.

Funding

This work was supported by the Xinjiang Uygur Autonomous Region Natural Science Fund Grant (No. 2017D01C297).

Authors' contributions

Kaile Zhang: Data Collection, Data Interpretation; Manuscript Preparation. Jianli Xu: Data Collection. Gang Chen: Data Collection. Ruixue Yang: Literature Search. Ming Jiang: Manuscript Preparation. Hailong Yuan: Study Design, Funds Collection, Manuscript Preparation.

References

- Ogata M, Fukuda T, Teshima T (2015) Human herpesvirus-6 encephalitis after allogeneic hematopoietic cell transplantation: what we do and do not know. *Bone Marrow Transplant* 50: 1030-1036. doi: 10.1038/bmt.2015.76
- Toomey D, Phan TL, Nguyen V, Phan TT, Ogata M (2021) Retrospective case analysis of antiviral therapies for HHV-6 encephalitis after hematopoietic stem cell transplantation. *Transpl Infect Dis* 23: e13443. doi: 10.1111/tid.13443.
- Ward KN, Hill JA, Hubacek P, de la Camara R, Crocchiolo R, Einsele H, Navarro D, Robin C, Cordonnier C, Ljungman P, European Conference on Infections in L (2019) Guidelines from the 2017 European Conference on Infections in Leukaemia for management of HHV-6 infection in patients with hematologic malignancies and after hematopoietic stem cell transplantation. *Haematologica* 104: 2155-2163. doi: 10.3324/haematol.2019.223073.
- Wilson MR, Naccache SN, Samayoa E, Biagtan M, Bashir H, Yu G, Salamat SM, Somasekar S, Federman S, Miller S, Sokolic R, Garabedian E, Candotti F, Buckley RH, Reed KD, Meyer TL, Seroogy CM, Galloway R, Henderson SL, Gern JE, DeRisi JL, Chiu CY (2014) Actionable diagnosis of neuroleptospirosis by next-generation sequencing. *N Engl J Med* 370: 2408-2417. doi: 10.1056/NEJMoa1401268.
- Salzberg SL, Breitwieser FP, Kumar A, Hao H, Burger P, Rodriguez FJ, Lim M, Quinones-Hinojosa A, Gallia GL, Tornheim JA, Melia MT, Sears CL, Pardo CA (2016) Next-generation sequencing in neuropathologic diagnosis of infections of the nervous system. *Neurol Neuroimmunol Neuroinflamm* 3: e251. doi: 10.1212/NXI.0000000000000251
- Doan T, Wilson MR, Crawford ED, Chow ED, Khan LM, Knopp KA, O'Donovan BD, Xia D, Hacker JK, Stewart JM, Gonzales JA, Acharya NR, DeRisi JL (2016) Illuminating uveitis: metagenomic deep sequencing identifies common and rare pathogens. *Genome Med* 8: 90. doi: 10.1186/s13073-016-0344-6.
- Lee YJ, Su Y, Cho C, Tamari R, Perales MA, Jakubowski AA, Papanicolaou GA (2022) Human herpesvirus 6 DNAemia is associated with worse survival after ex vivo t-cell-depleted hematopoietic cell transplant. *J Infect Dis* 225: 453-464. doi: 10.1093/infdis/jiab412.
- Handley G (2022) Current role of prospective monitoring and preemptive and prophylactic therapy for human herpesvirus 6 after allogeneic stem cell transplantation. *Open Forum Infect Dis* 9: ofac398. doi: 10.1093/ofid/ofac398
- Yassin A, Al-Mistarehi AH, El-Salem K, Momani A, Al Qawasmeh M, Rodriguez R, Tummala S (2020) Clinical, radiological, and electroencephalographic features of HHV-6 encephalitis following hematopoietic stem cell transplantation. *Ann Med Surg (Lond)* 60: 81-86. doi: 10.1016/j.amsu.2020.10.022.
- Wang X, Patel SA, Haddadin M, Cerny J (2021) Post-allogeneic hematopoietic stem cell transplantation viral reactivations and viremias: a focused review on human

herpesvirus-6, BK virus and adenovirus. *Ther Adv Infect Dis* 8: 20499361211018027. doi: 10.1177/20499361211018027.

- Ito Y, Toyama K, Honda A, Nakazaki K, Arai S, Kurokawa M (2020) Posterior reversible encephalopathy syndrome concurrent with human herpesvirus-6B encephalitis after allogeneic hematopoietic stem cell transplantation. *J Infect Chemother* 26: 265-268. doi: 10.1016/j.jiac.2019.07.016.
- Sakamoto A, Yamada M, Tsujimoto SI, Osumi T, Arai K, Tomizawa D, Ishiguro A, Matsumoto K, Imadome KI, Kato M (2020) A case of human herpesvirus 6 encephalitis following pediatric hematopoietic stem cell transplantation: early diagnosis and treatment matters. *Int J Hematol* 112: 751-754. doi: 10.1007/s12185-020-02905-x.
- Piantadosi A, Mukerji SS, Ye S, Leone MJ, Freimark LM, Park D, Adams G, Lemieux J, Kanjilal S, Solomon IH, Ahmed AA, Goldstein R, Ganesh V, Ostrem B, Cummins KC, Thon JM, Kinsella CM, Rosenberg E, Frosch MP, Goldberg MB, Cho TA, Sabeti P (2021) Enhanced Virus detection and metagenomic sequencing in patients with meningitis and encephalitis. *mBio* 12: e0114321. doi: 10.1128/mBio.01143-21.
- Carbo EC, Buddingh EP, Karelioti E, Sidorov IA, Feltkamp MCW, Borne P, Verschuuren J, Kroes ACM, Claas ECJ, de Vries JJC (2020) Improved diagnosis of viral encephalitis in adult and pediatric hematological patients using viral metagenomics. *J Clin Virol* 130: 104566. doi: 10.1016/j.jcv.2020.104566.
- Xing XW, Zhang JT, Ma YB, He MW, Yao GE, Wang W, Qi XK, Chen XY, Wu L, Wang XL, Huang YH, Du J, Wang HF, Wang RF, Yang F, Yu SY (2020) Metagenomic next-generation sequencing for diagnosis of infectious encephalitis and meningitis: a large, prospective case series of 213 patients. *Front Cell Infect Microbiol* 10: 88. doi: 10.3389/fcimb.2020.00088.
- Haston JC, Rostad CA, Jerris RC, Milla SS, McCracken C, Pratt C, Wiley M, Prieto K, Palacios G, Shane AL, McElroy AK (2020) Prospective cohort study of next-generation sequencing as a diagnostic modality for unexplained encephalitis in children. *J Pediatric Infect Dis Soc* 9: 326-333. doi: 10.1093/jpids/piz032.
- El Jurdi N, Rogosheske J, DeFor T, Bejanyan N, Arora M, Bachanova V, Betts B, He F, Holtan S, Janakiram M, Larson S, Maakaron J, Rashidi A, Warlick E, Wagner JE, Young JH, Weisdorf D, Brunstein CG (2021) Prophylactic foscarnet for human herpesvirus 6: effect on hematopoietic engraftment after reduced-intensity conditioning umbilical cord blood transplantation. *Transplant Cell Ther* 27: 84 e81-84 e85. doi: 10.1016/j.bbmt.2020.10.008.
- Hill JA, Nichols WG, Marty FM, Papanicolaou GA, Brundage TM, Lanier R, Zerr DM, Boeckh MJ (2020) Oral brincidofovir decreases the incidence of HHV-6B viremia after allogeneic HCT. *Blood* 135: 1447-1451. doi: 10.1182/blood.2019004315.

Corresponding author

Corresponding author

Hailong Yuan

Chief physician, Hematology Center, the First Affiliated Hospital of Xinjiang Medical University, Xinjiang Institute of Hematology, No.137, Liyushan South Road, Urumqi 830054, China.

Tel.: +86-13999961228

Email: snail612s@163.com

Conflict of interests: No conflict of interests is declared.