

Case Report

Management of severe tetanus in Afghanistan: lessons from the field

Ornella Spagnolello^{1,2}, Ahmad K Aryan¹, Muhebullah Ahmadzai¹, Arezo Dost¹, Abdul G Boosti¹, Giancarlo Ceccarelli^{2,3}, Gina Portella^{1,4}, Martina Baiardo Redaelli^{1,5}

¹ EMERGENCY Hospital, Kabul, Afghanistan

² Department of Public Health and Infectious Diseases, Sapienza University, Rome, Italy

³ Azienda Ospedaliero-Universitaria, Policlinico Umberto I, Rome, Italy

⁴ EMERGENCY NGO, Onlus, Milan, Italy

⁵ Department of Anesthesia and Intensive Care, San Raffaele Scientific Institute (IRCCS), Milan, Italy

Abstract

Introduction: Tetanus is a rather rare disease in the Western countries thanks to widespread vaccination programs and the availability of prophylactics for patients with tetanus-prone injuries. The few cases that do occur are promptly managed in intensive care units (ICUs). However, tetanus is not so rare in developing countries, where access to a suitable level of care is limited. An unstable political situation can be a significant factor influencing patient outcomes.

Case report: A ten-year-old boy presented at the EMERGENCY hospital in Lashkar-Gah (southern Afghanistan) with generalized tetanus after falling off his bicycle. In response to his rapidly deteriorating general conditions – respiratory failure and hemodynamic instability – the patient was urgently transferred by ambulance to the ICU at the EMERGENCY hospital in Kabul (northern Afghanistan). The patient was placed on mechanical ventilation while receiving intravenous sedation and pharmacologic paralysis for almost four weeks. A prolonged infusion of a high dose of magnesium sulphate and labetalol was also given to counteract autonomic dysfunction. Multiple complications related to the long stay in the ICU were observed and promptly addressed. During this period, several mass casualties took place in Kabul, which stretched the hospital's surge capacity. The patient was discharged and accompanied back to Lashkar-Gah three months after his admission to the hospital.

Conclusions: This case report shows some of the many difficulties that arise when managing a patient with severe tetanus in a war zone where resources are limited.

Key words: generalized tetanus, intensive care, Afghanistan, armed conflicts, civilian war victims.

J Infect Dev Ctries 2024; 18(4):640-644. doi:10.3855/jidc.18739

(Received 14 June 2023 – Accepted 10 August 2023)

Copyright © 2024 Spagnolello *et al.* This is an open-access article distributed under the Creative Commons Attribution License, which permits unrestricted use, distribution, and reproduction in any medium, provided the original work is properly cited.

Introduction

Tetanus is a potentially fatal infection and is characterized by generalized skeletal muscle spasms that can lead to respiratory failure [1]. The spore-forming bacterium *Clostridium tetani*, which is responsible for the disease, is commonly found in contaminated soil and can penetrate the body through cuts or abrasions. Wounds with a consistent amount of tissue injury are prone to bacterial spore germination. Tetanospasmin, a potent toxin released by the tetanus bacilli, binds gangliosides within local nerve terminals and proceeds to the ventral horns of the spinal cord or the motor horns of the cranial nerves. The final result is the deactivation of the inhibitory neurotransmission of these neuronal pathways, which causes increased muscle tone and widespread autonomic instability. The clinical scenario that follows includes generalized body spasms, respiratory failure, and hemodynamic instability, and it can last for four to six weeks.

The management of severe cases requires admission to and treatment in an intensive care unit (ICU). Therefore, it is not surprising that the likelihood of mortality is greatly affected by geography [2,3].

In war-torn and low-income countries like Afghanistan, tetanus continues to be a threat to the population. Despite the availability of an effective and inexpensive vaccine since the 1930s, vaccination programs are still limited in the country, particularly in remote areas. In addition, Afghan civilians are faced with a constant risk of tetanus-prone injuries from explosions, landmines and other trauma, due to the ongoing violence in the country. According to the World Health Organization (WHO) and the United Nations Children's Fund (UNICEF), the estimated immunization coverage with diphtheria-pertussis-tetanus (DPT) vaccine in Afghanistan in 2021 was 74% with the first dose, and just 66% with the third dose. This is a reduction in coverage going back to 2017

levels [4]. Moreover, the coverage is still far from the goal established by the Global Vaccine Action Plan, which aimed at 90% national coverage and 80% coverage in every district for all vaccines in the national programs by 2020 [5]. Notably, the WHO and the UNICEF also reported that in 2021, 31.6% of tetanus cases worldwide occurred in Afghanistan (3,070 out of 9,708 worldwide).

After decades of constant war, beginning in 1979 with the Russian invasion of the country, a large part of the Afghan population does not have access to healthcare services. Moreover, healthcare facilities are limited in number and are able to provide a limited level of care. ICUs with mechanical ventilation are also uncommon in the main cities. Finally, poor health education among the vast majority of the population prevents people from accessing basic healthcare services, such as vaccines, even where they are available.

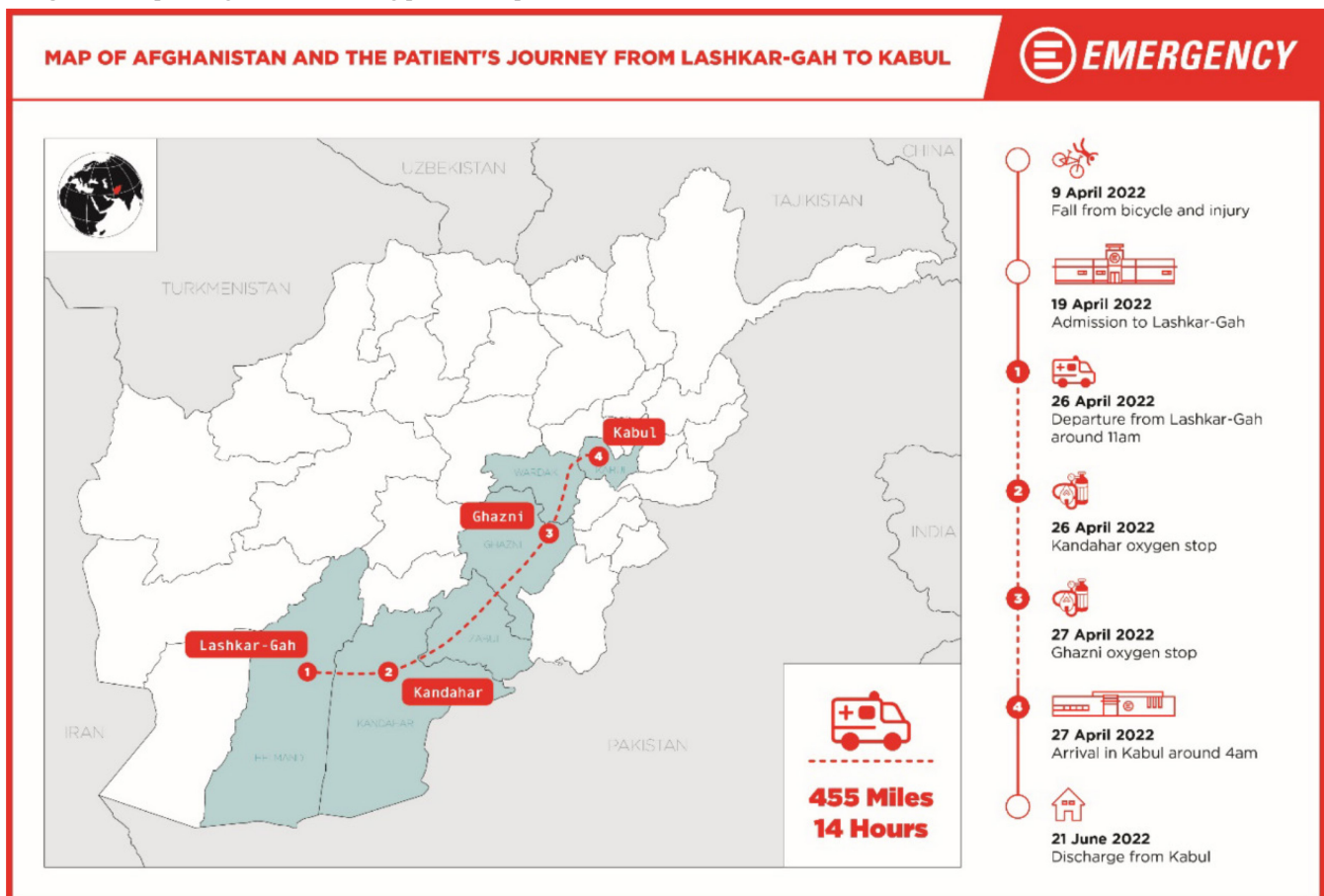
Here we report the lessons we have learnt while managing severe generalized tetanus in a low-resource area afflicted by long-standing conflicts.

Case Presentation

On April 19, 2022, a ten-year-old boy was brought to the EMERGENCY surgical center in Lashkar-Gah, Helmand province, ten days after he fell off his bicycle. Upon arrival at the emergency department, the patient had trismus and fever. His physical examination was unremarkable apart from a 1-cm-long infected wound on his left heel. Tetanus was suspected and the patient was admitted for surgical debridement and close observation in the hospital’s high-dependency unit. Antibiotic therapy with penicillin G and metronidazole was started. The tetanus vaccine and immunoglobulins were promptly administered. On day three, the patient developed generalized tetanic attacks, partly in response to diazepam and phenobarbital administered intravenously. On day five, in response to increasing respiratory distress, the patient underwent a tracheostomy and the decision was made to transfer him urgently to the ICU at EMERGENCY hospital in Kabul.

Following a challenging 14-hour-long ambulance journey to Kabul (requiring manual ventilation, with limited oxygen available and in difficult driving

Figure 1. Map of Afghanistan showing patient’s trip from Lashkar-Gah to Kabul



conditions), the patient finally arrived at our emergency department at 4 a.m. on April 27 (Figure 1). The clinical picture was of very poor general conditions. Assessment using the Glasgow coma scale was impossible due to sedation and severe generalized muscle spasms, despite medical treatment. The patient's response to pain stimulus was only a minimal facial expression of discomfort. Respiratory rate was 55 breaths/min, SpO₂ was 96% with 4 L/min of O₂ through the tracheostomy cannula. Hemodynamics responses were spontaneous and unstable, with a heart rate of 160 beats/min, blood pressure of 100/60 mmHg, and body temperature was 36.4 °C. At the first blood check, lactate was 5.4 mmol/L and creatine kinase above 4000 U/L. The clinical picture was in line with a grade 4 tetanus condition [6,7].

The patient was promptly placed on mechanical ventilation, paralysis was induced with vecuronium via continuous infusion (CI) and deep sedation with a combination of propofol, midazolam and morphine (Table 1). A high dose of magnesium sulphate via CI was also started after his admission to the ICU in order to reduce autonomic disturbance. The ongoing medical treatment with antibiotics baclofen and phenobarbital was continued.

The patient developed several complications over a 30-day stay in the ICU under mechanical ventilation. The complications included catheter-associated urinary tract infection, tracheostomy site infection and ventilator-associated pneumonia, severe acute respiratory distress syndrome (ARDS) that required protective mechanical ventilation and cycles of prone positioning. Accordingly, different antibiotic strategies were put in place, stepwise, and all the devices were replaced according to clinical needs.

Autonomic dysfunction leading to hemodynamic instability was another important point of concern. Despite the high dose of magnesium sulphate via CI and the subsequent intravenous infusion of clonidine, a

significant result in terms of hemodynamic stability was only achieved after labetalol was added via CI (Table 1).

From the nutritional point of view, the patient received enteral feeding after admission to our hospital, initially through a nasogastric tube and then by gastrostomy, which was done 27 days after his hospitalization. However, the supportive manoeuvres (prolonged prone position) done on the patient often prevented him from reaching the number of kilocalories desirable for someone of his age, and he lost significant body weight during his long stay in the ICU. At the time of admission to Lashkar-Gah his body weight was estimated to be 37 kg, and it dropped to 25 kg after one month.

Generalized muscle spasms were resolved after 27 days of deep sedation and paralysis via CI. Once tetanic attacks were under control, a progressive weaning from mechanical ventilation was feasible. Throughout this time, the patient was managed in a relatively quiet environment, with earplugs and sunglasses in order to minimize environmental stimulation.

To support the child psychologically in his process of recovery, his father was encouraged to stand by his bedside as soon as it was possible to communicate with him.

The patient was discharged after a stay of three months in the hospital and followed up with intensive rehabilitative physiotherapy. A new bicycle was given to the boy the day before he was discharged, and he was able to ride again.

Discussion

EMERGENCY is an Italian non-governmental organization (NGO) which provides free, high-quality healthcare to victims of war. EMERGENCY has been running three hospitals in Afghanistan (in Kabul, Lashkar-Gah and Anabah) and a growing network of 42 first aid posts since 1999. The Kabul hospital is a 100-

Table 1. Summary of dosages, course of therapy and drugs administered to the patient.

	Day after admission when the drug administration was initiated	Course of therapy	Maximum dose
Diazepam IV	Upon admission	3 days	2 mg QID
Midazolam CI	2 nd	4 weeks	8 mg/h
Phenobarbital IV	4 th	4 weeks	85 mg BID
Propofol CI	8 th	4 weeks	5 mg/kg/h
Morphine CI	12 th	3 weeks	2 mg/h
Vecuronium IV	8 th	4 weeks	1.2 mcg/kg/h
Magnesium sulphate IV	1 st	8 weeks	20 gr/die
Labetalol CI	21 st	3 weeks	2 mg/h
Clonidine IV	7 th	5 weeks	0.1 mg BID
Baclofen NGT	2 nd	8 weeks	15 mg QID

IV: intravenous; CI: continuous infusion; NGT: nasogastric tube; BID: two times a day; QID: four times a day.

bed facility, including a six-bed ICU with mechanical ventilation [8].

Our experience in the field raises some interesting points about tetanus management. In a difficult setting where there is no public healthcare system, vaccination certificates are not readily available, and supplies of tetanus vaccine and tetanus immune globulin are scarce, it is advisable to have an intervention strategy that minimizes the impact of these failings on the local population. Resource rationing should prioritize not only the most clinically severe cases but also those who are least likely to be vaccinated. To this end, adequate knowledge of previous vaccination campaigns in the area, the target population reached in those campaigns, and the coverage achieved, could be useful in identifying the least protected groups in the population. Where resources are limited, tetanus immune globulin should be reserved for those less likely to have the protective antibodies or those that would benefit the most from it [3].

Interestingly, despite the large number of patients coming to us with tetanus-prone wounds from a population with low immunization thresholds, this condition rarely occurs if an aggressive soft tissue debridement is promptly performed and the patient is started on standard prophylactic antibiotics according to our local protocol (ampicillin \pm chloramphenicol \pm metronidazole). However, considering the lack of an emergency care system outside the hospital, and the unsafe state of transport, especially from remote areas, most of the patients arrive at our hospital long after the “golden hour” [9]. It is well demonstrated that the time from injury is a relevant risk factor in the occurrence of tetanus. This can be explained not only by the probability of spore germination over time, but also by the patients’ general condition, which can facilitate the same process. Tissue hypoperfusion in patients who are bleeding and have to spend a long time travelling to our facilities can further encourage a local anaerobic environment that enforces spore germination.

Another consideration is about the general management of the most severe tetanus cases. An ICU is essential as soon as clinical conditions deteriorate; and little can be done without mechanical ventilation, continuous full-parameter monitoring, and adequate equipment for treatment. Therefore, early identification of such cases and their prompt transfer to a hospital with an ICU is the first step if the patient is to survive. Unfortunately, these processes do not come without risks (lack of adequate ambulance services and trained staff, limited availability of well-equipped, free-of-charge hospitals, safety concerns about both

infrastructure and the chance of passing through active war zones) in Afghanistan, and most of the time the balance between benefits and risks is weighed towards the latter.

The natural history of the disease is often very long – four to six weeks – as recovery requires not only degradation of tetanospasmin, but also the growth of new axonal terminals. Not accounting for this long course of action could lead to excessively quick and abrupt changes in the treatment plan (which should be avoided) and deep frustration for medical staff.

The medical plan should mainly focus on respiratory and hemodynamic support, along with prevention and treatment of the complications inherent to a long stay in the ICU. The plan should not be ended too fast or prematurely, regardless of staff’s expectations [10]. This point is particularly important in a hospital with just six ICU beds and regularly managing mass casualties. In a limited-resource setting, the choice to allocate an ICU bed is not free from ethical dilemmas [11,12].

Conclusions

Tetanus is a preventable disease which unfortunately represents a threat in Afghanistan. The country carries the burden of more than one-third of tetanus cases worldwide. The lack of basic medical education among the general population, together with the lack of an effective and easily accessible preventive strategy and ventilated, free-of-charge ICU beds, represents a potentially fatal combination. A broad program of vaccination should be strongly supported, regardless of the decrease in financial support for, and interest in, the country by the international community after August 2021 (the date the American troops evacuated from Afghanistan). At the moment, an aggressive surgical approach together with empirical preventive antibiotic therapy are the main prophylactic measures to be taken on a regular basis for tetanus-prone wounds [13]. Early vaccination and immunoglobulin, when feasible and sustainable, should be administered to all patients, especially those with additional risk factors (arriving at the hospital more than six hours after the injury, a non-linear wound deeper than 1 cm, injury from missiles, crushing, burns or frostbite, devitalized tissue, and contaminants) [14]. In our experience, a prolonged intravenous high dose of magnesium, leading to normal renal function proved to be safe even when serum levels could not be checked regularly. Labetalol via CI was crucial in the management of dysautonomia-related hemodynamic instability, where other treatments alone failed.

Acknowledgements

The authors would like to thank all the local and international staff who have taken part in EMERGENCY's projects in Afghanistan. A special thanks to George Cowie (EMERGENCY UK) for editing and language revision and to Daniela Buffagni (EMERGENCY, Milan) for the graphics. In loving memory of Gino Strada (founder of EMERGENCY in 1994).

Authors' contributions

All the authors contributed to the planning, drafting and revision of the article.

Compliance with ethical standards

Informed consent for publication was obtained from the father of the patient

References

1. Alagappan K, McGowan J, DeClaro D, Ng D, Silverman R (2008) Tetanus antibody protection among HIV-infected US-born patients and immigrants. *Int J Emerg Med* 1: 123-126. doi: 10.1007/s12245-008-0020-8.
2. Fan Z, Zhao Y, Wang S, Zhang F, Zhuang C (2019) Clinical features and outcomes of tetanus: a retrospective study. *Inf Drug Res* 16: 1289-1293. doi: 10.2147/IDR.S204650.
3. Finkelstein P, Teisch L, Allen CJ, Ruiz G (2017) Tetanus: a potential public health threat in times of disaster. *Prehosp Disaster Med* 32: 339-342. doi: 10.1017/S1049023X17000012.
4. World Health Organization (2023) Diphtheria tetanus toxoid and pertussis (DTP) vaccination coverage. Available: <https://immunizationdata.who.int/pages/coverage/dtp.html?CODE=AFG&ANTIGEN=&YEAR=>. Accessed: 3 February 2023.
5. World Health Organization (2013) Global vaccine action plan 2011-2020. Geneva. Available: <https://www.who.int/publications/i/item/global-vaccine-action-plan-2011-2020/> Accessed: 3 February 2023.
6. Ablett JJJ (1967) Analysis and main experiences in 82 patients treated in the Leeds Tetanus Unit, in: Ellis M, ed. Symposium on Tetanus in Great Britain, Boston Spa, National Lending Library.
7. Cook TM, Protheroe RT, Handel JM (2001) Tetanus: a review of the literature. *Br J Anaesth* 87: 477-487. doi: 10.1093/bja/87.3.477.
8. EMERGENCY (2023) Surgical centre for war victims in Kabul, Afghanistan. Available: <https://en.emergency.it/projects/afghanistan-kabul-surgical-centre/> Accessed: 3 February 2023.
9. Spagnolello O, Gatti S, Shahir MAA, Afzali MF, Portella G, Baiardo Redaelli M (2022) Civilian war victims in Afghanistan: five-year report from the Kabul EMERGENCY NGO hospital. *Eur J Trauma Emerg Surg* 49: 1401-1405. doi: 10.1007/s00068-022-02137-0.
10. Olum S, Eyul J, Lukwiya DO, Scolding N (2021) Tetanus in a rural low-income intensive care unit setting. *Brain Commun* 3: fcab013. doi: 10.1093/braincomms/fcab013.
11. Spagnolello O, Esmati S, Amiri AF, Shahir MAA, Gatti S, Portella G, Langer M (2022) Kabul airport suicide bombing attack: mass casualty management at the EMERGENCY NGO Hospital. *J Trauma Acute Care Surg* 93: 552-557. doi: 10.1097/TA.0000000000003724.
12. Spagnolello O, Gatti S, Esmati S, Shahir MAA, Portella G (2022) Kabul airport suicide attack: report of a mass casualty. *Eur J Trauma Emerg Surg* 48: 2687-2688. doi: 10.1007/s00068-022-01898-y.
13. Yen LM, Thwaites CL (2019) Tetanus. *Lancet* 393: 1657-1668. doi: 10.1016/S0140-6736(18)33131-3.
14. World Health Organization (2023) Current recommendations for treatment of tetanus during humanitarian emergencies: WHO technical note. Available: <https://apps.who.int/iris/handle/10665/70219>. Accessed: 3 February 2023.

Corresponding author

Ornella Spagnolello, MD, PhD.
Sapienza University of Rome,
Viale del Policlinico 155, 00161 Roma (RM), Italy.
Tel: +39 0649971
Email: spagnolello.ornella@gmail.com

Conflict of interests: No conflict of interests is declared.