

Case Report

Acute Q fever pneumonia diagnosed by metagenomic next-generation sequencing

Bin Liu¹, Peng Huang¹, Yanchao Liang¹, Shuangbo Liu¹, Fangwei Chen¹, Xiping Luo¹, Tengjuan Xu¹, Bo Xie²

¹ Department of Pulmonary and Critical Care Medicine, Zhuzhou Central Hospital, Zhuzhou Hospital Affiliated to Xiangya School of Medicine, Central South University, Zhuzhou, Hunan, China

² Department of Medical Administration, Zhuzhou Central Hospital, Zhuzhou Hospital Affiliated to Xiangya School of Medicine, Central South University, Zhuzhou, Hunan, China

Abstract

Introduction: Q fever, a zoonotic disease caused by *Coxiella burnetii* (*C. burnetii*), presents diagnostic challenges due to its clinical and radiological nonspecificity, which often mimics community-acquired pneumonia, coupled with the limitations of traditional diagnostic methods. Metagenomic next-generation sequencing (mNGS) has become an indispensable tool in clinical diagnostics for its high-throughput pathogen identification capabilities. Herein, we detail a case of acute Q fever pneumonia diagnosed with mNGS.

Case presentation: The patient exhibited symptoms of fever, cough, expectoration, and diarrhea for three days, with the pathogen undetected in initial laboratory assessments. Bronchoscopy and bronchoalveolar lavage (BAL) were conducted, leading to the identification of *C. burnetii* in the lavage fluid via mNGS. Consequently, the patient was promptly initiated on a treatment regimen of 100 mg doxycycline, administered orally every 12 hours.

Results: Post-treatment, the patient's temperature normalized, and a full recovery was observed. The follow-up chest CT scan revealed complete resolution of the right lower lobe consolidation.

Conclusions: The clinical presentation of Q fever pneumonia lacks specificity, making diagnosis based solely on symptoms and imaging challenging. mNGS offers a superior alternative for identifying elusive or rarely cultured pathogens.

Key words: Q fever; pneumonia; *Coxiella burnetii*; metagenomic next-generation sequencing; mNGS; diagnosis.

J Infect Dev Ctries 2024; 18(5):834-838. doi:10.3855/jidc.18314

(Received 03 April 2023 – Accepted 04 October 2023)

Copyright © 2024 Liu *et al.* This is an open-access article distributed under the Creative Commons Attribution License, which permits unrestricted use, distribution, and reproduction in any medium, provided the original work is properly cited.

Introduction

Q fever is a zoonotic disease caused by *C. burnetii*. Infection with *C. burnetii* can lead to a systemic illness, which is categorized into two forms: acute and chronic Q fever [1]. Without treatment, about 5% of patients with acute Q fever may progress to chronic Q fever, potentially resulting in persistent localized infection or endocarditis, complicating treatment [2]. While traditional diagnostic methods like culture and serological testing are utilized for Q fever, they suffer from low sensitivity and delayed results. Metagenomics next-generation sequencing (mNGS) is a recent molecular technique that can detect a wide array of microbes by analyzing all DNA or RNA present in a sample. This method has also been effective in identifying rare pathogens, such as *C. burnetii* [3].

We present a rare case of Q fever in a male patient characterized by recurrent fever and pneumonia. Empirical anti-infective treatments proved ineffective,

leading to a definitive diagnosis via mNGS analysis of bronchoalveolar lavage fluid (BALF).

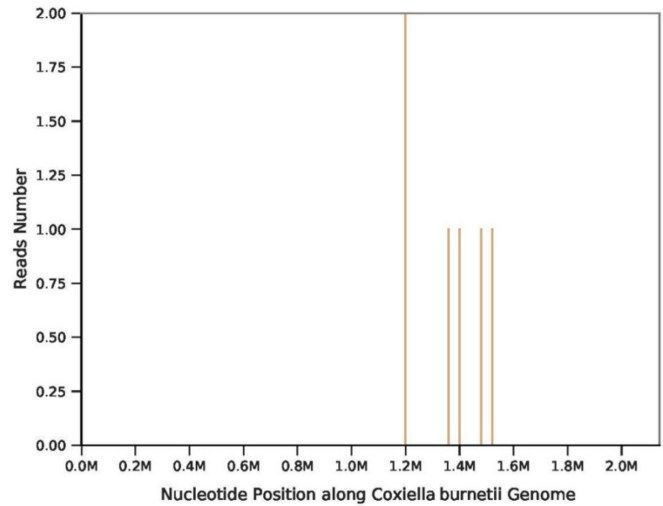
Case report

A 60-year-old male, presenting with fever, cough, expectoration, and diarrhea for three days, was admitted to our hospital on May 7th, 2022. A long-term resident of the local city, he had no history of pet or poultry farming. He had no exposure to epidemic water or areas. He had a decade-long history of pneumoconiosis, type 2 diabetes, and hypertension. Additionally, he had been diagnosed with rheumatoid arthritis ten years earlier and was maintained on a regimen of methotrexate (10mg/week) and methylprednisolone (4mg/day) for symptomatic management. Chest CT scan on May 4th, 2022, at a local hospital showed pneumoconiosis, right lower lobe consolidation, and suspected infection (Figure 1a). He was initially treated with Cefoperazone sodium and sulbactam, along with moxifloxacin for antibacterial therapy. Despite initial

treatment, he continued to have a fever, prompting admission to our hospital for further evaluation. Physical examination noted diminished breath sounds in the right lower lung and right-hand joint deformity. Laboratory findings indicated a hemoglobin of 97 g/L, leukocyte count of $5.88 \times 10^9/L$, serum albumin of 26.2 g/L, alanine aminotransferase at 41 U/L, and aspartate aminotransferase at 47 U/L. However, renal function was within normal limits. Elevated infection markers included C-reactive protein (197 mg/mL), procalcitonin (0.636 ng/mL), and erythrocyte sedimentation rate (110 mm/hour). Influenza A and B antigen tests, as well as adenovirus nucleic acid testing, were negative. Rickettsial IgM antibody testing was also negative. Tumor marker tests, Widal reaction, and screenings for hepatitis, HIV, syphilis, and syphilis (RPR) were all negative. CD4 T-cell count was 231 cells/ μL ; CD8 T-cell count was 141 cells/ μL . The initial diagnosis was bacterial pneumonia. However, viral pneumonia could not be definitively excluded. Thus, the patient was given empiric antibiotics (Levofloxacin 500mg/day intravenous drip, Imipenem 1g/8 hours intravenous drip) and antiviral therapy (Oseltamivir 75mg/12 hours oral).

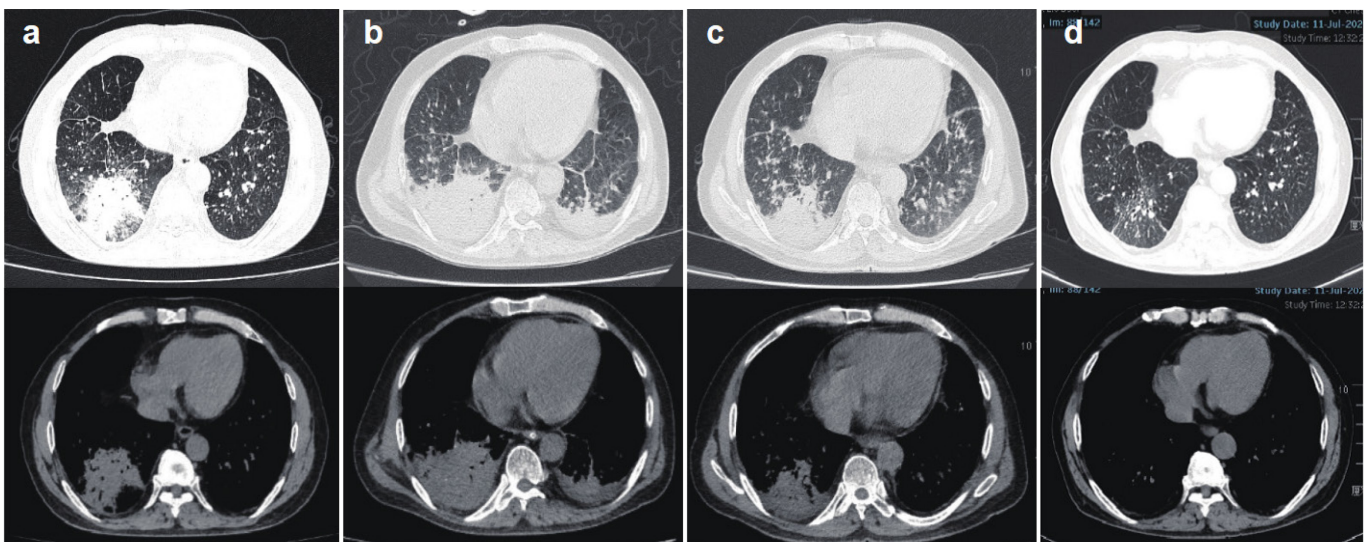
He showed a marginal response to therapy, with persistent mild to moderate fever. No pathogens were identified in blood, stool, urine, or sputum cultures. On May 10th, 2022, the patient developed acute dyspnea, with oxygen saturation plummeting to 60%. He was immediately sedation, intubated, and placed on mechanical ventilation. Chest CT scan showed progressive lower lung lesions (Figure 1b). On May 11th, 2022, bronchoscopy revealed congested bronchial

Figure 2. The coverage of *Coxiella burnetii* detected by mNGS in BALF.



mucosa in all lung lobes. BALF was collected and for PACEseq mNGS at BGI Genomics, Wuhan, China, and conventional pathogen detection. The patient’s condition stabilized, and mechanical ventilation was discontinued on May 12th, 2022. The mNGS result, obtained on May 13th, 2022, identified *C. burnetii* with five reads (Figure 2). The patient reported no close contact with individuals diagnosed with Q fever, which is rare in the region. Hence, we re-assessed the patient’s history, uncovering his recent two-week rural residency before symptom onset. Rat activity was noted at his residence; however, there were no reports of tick bites or skin lesions. Given the patient’s environmental exposure, radiological findings, and mNGS pathogen identification, a diagnosis of Q fever pneumonia was

Figure 1. Pre- and post-therapy CT scan. **a.** Chest CT before treatment; **b.** Chest CT after oseltamivir, levofloxacin, and imipenem treatment; **c.** Chest CT after doxycycline treatment; **d.** Chest CT after one month of doxycycline treatment.



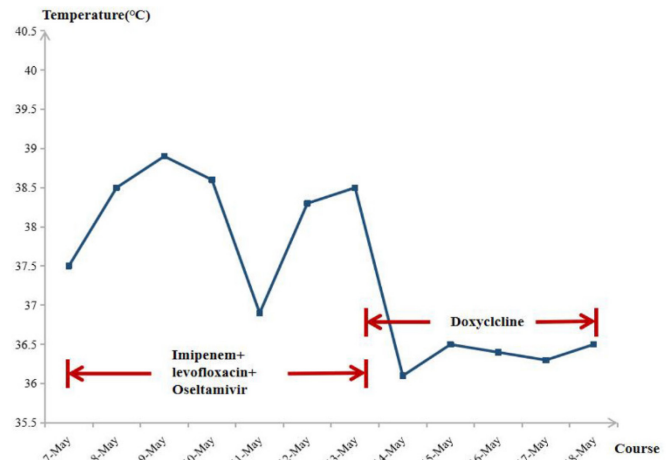
confirmed. Doxycycline treatment was initiated at a dosage of 100 mg every 12 hours orally. Normalization of body temperature was observed following doxycycline therapy, leading to the discontinued and antivirals (Figure 3). Subsequently, the patient's fever resolved, with concurrent normalization of C-reactive protein and procalcitonin levels. After 13 days of doxycycline, a follow-up chest CT scan showed diminished bilateral lung lesions (Figure 1c). The patient was discharged with a residual dry cough and continued doxycycline for an additional eight days. Upon return visit on July 11th, 2022, the chest CT scan demonstrated complete resolution of the right lower lobe consolidation, with a residual fibrous strip, signifying full recovery (Figure 1d).

Discussion

Q fever can infect a broad spectrum of hosts and is transmissible through ruminants, various domestic and wild animals, birds, and arthropods [4]. *C. burnetii* is predominantly found in the urine, feces, amniotic fluid, and other excretions of infected animals. *C. burnetii* has a long environmental persistence, can form aerosols under certain conditions, and can spread Q fever over long distances via wind [5,6]. Inhalation is the primary route of human infection, leading to pulmonary disease, although systemic infections can arise via lymphatic and hematopoiesis spread. Yet, in numerous instances, no clear epidemiological links or direct animal exposures are found, underscoring the high virulence and environmental resilience of *C. burnetii* spores [7]. In this case, there was no reported history of tick bites, although rodent activity was noted in the patient's environment, leaving the specific epidemiological factors undetermined. A hypothesis suggests a correlation between the biological traits of *C. burnetii* and the infection's origin.

Highly virulent, *C. burnetii* can provoke systemic infection from inhaling minimal amounts bacteria into the respiratory tract [8]. Acute Q fever typically manifests as pneumonia with symptoms including fever, cough, dyspnea, and abnormal auscultation [7]. Q fever pneumonia is also marked by extrapulmonary symptoms—such as muscle and joint pain, rash, and diarrhea—with neurological symptoms being less common [7]. Regrettably, the clinical and radiological features of Q fever pneumonia are nonspecific, which can result in misdiagnosis. Moreover, isolation and culturing *C. burnetii* has a low success rate, complicating pathogen identification. While radiological findings are not definitive for distinguishing Q fever pneumonia from other types,

Figure 3. Longitudinal analysis of temperature and medication. After using specific drugs—doxycycline, the temperature was effectively controlled and did not rebound.



they can show distinctive features [9]. Voloudaki *et al.* [10] examined chest CT scans from twelve patients with Q fever pneumonia. CT scans showed air-space involvement with lesions appearing as lobar, segmental, patchy, or mixed patterns. One patient exhibited extensive patchy consolidation, nodular lesions linked to vasculature, and a ground-glass opacity halo. VonRanke *et al.* [11] also reported HRCT findings in 6 patients with acute Q fever pneumonia. HRCT scans predominantly showed consolidation (100%) and nodular lesions (66.6%), along with ground-glass opacities. These opacities were mainly observed in a segmental and peripheral distribution. Differences observed may stem from variations in CT technology. VonRanke *et al.* employed advanced technology, enhancing sensitivity in detecting ground-glass opacity. In this case, the initial CT scan showed consolidation with halos of ground-glass opacity. With ineffective antibiotics, the consolidation expanded, affecting the left lower lung and causing pleural effusion. However, upon starting the correct antibiotics, the consolidation resolved, with residual fibrous strip shadows.

Currently, Q fever diagnosis predominantly depends on laboratory tests, including pathogen culture and serology. Pathogen culture necessitates a high biosafety level laboratory, which is not readily available in most hospitals. Fluorescence quantitative PCR offers good specificity and sensitivity but is costly to operate. Therefore, serological antibodies detection is the mainstay for diagnosing Q fever in the clinical lab [12]. However, it is essential to recognize that serological tests may lack sensitivity in early disease stages or before antibody production, risking false negatives. Advancing biological technology has led to the

application of mNGS for diagnosing Q fever. For example, Huang *et al.* [13] used mNGS to successfully identify an acute Q fever outbreak in Zhuhai, China, from 2018 to 2019. mNGS is a high-throughput sequencing technique that directly detects DNA nucleic acid sequences from clinical samples. Bioinformatics then analyzes these sequences to identify pathogens within the samples. mNGS offers significant advantages over conventional PCR by concurrently detecting bacteria, fungi, parasites, and viruses. Traditional culture methods usually require days to weeks and have a low detection rate. In contrast, mNGS significantly reduces detection time, enabling rapid pathogen identification. mNGS is particularly adept at identifying rare, culture-resistant pathogens. Here, *C. burnetii* was identified within 23 hours, expediting pathogen identification.

Studies suggest doxycycline, gatifloxacin, levofloxacin, moxifloxacin, and ciprofloxacin are the most effective antibiotics against *C. burnetii* isolates [14]. The patient initially received moxifloxacin and levofloxacin, but the response was unsatisfactory. However, initiating doxycycline treatment led to the resolution of the patient's fever and gradual improvement in condition. This suggests doxycycline's higher efficacy against *C. burnetii* in this instance. The United States Centers for Disease Control and Prevention recommends doxycycline as the first-line treatment for severe Q fever in patients regardless of age. The adult dosage is typically 100mg every 12 hours for a duration of 14 to 21 days [15]. Immunosuppression is recognized as a risk factor for persistent *C. burnetii* infection [16]. Despite limited research, doxycycline has been used to treat Q fever in immunosuppressed patients [2]. The patient had been on methotrexate and methylprednisolone for an extended period. These immunosuppressants were discontinued upon the onset of fever and other signs of infection. A three-week doxycycline course significantly improved the patient's condition, with complete resolution of the right lower lobe consolidation.

In conclusion, the nonspecific clinical presentation of Q fever pneumonia complicates diagnosis based on symptoms and imaging alone. Nevertheless, mNGS is a valuable molecular diagnostic tool offering rapid, accurate, and comprehensive pathogen detection, including common, rare, and emerging ones. In clinical practice, mNGS should be considered early on if traditional detection methods are inconclusive, facilitating timely pathogen identification and targeted treatment for complex cases.

Acknowledgements

The authors thank all the clinicians, microbiologists, and radiologists who have assisted with this research.

Authors' Contributions

Bin Liu, Peng Huang, Yanchao Liang, Shuangbo Liu, Fangwei Chen, Xiping Luo, Tengjuan Xu, and Bo Xie co-authored the manuscript and approved the final version.

Ethical considerations

The authors have noted ethical issues, including plagiarism, informed consent, misconduct, data untruth and falsification, double publication and submission, redundancy among others.

References

1. Raoult D, Marrie T (1995) Q fever. *Clin Infect Dis* 20: 489-495. doi: 10.1093/clinids/20.3.489.
2. Melenotte C, Million M, Raoult D (2020) New insights in *Coxiella burnetii* infection: diagnosis and therapeutic update. *Expert Rev Anti Infect Ther* 18: 75-86. doi: 10.1080/14787210.2020.1699055.
3. Kondo M, Dalai SC, Venkatasubrahmanyam S, Eisenberg N, Robinson BD, Westblade LF, Marks KM (2019) Diagnosis and genotyping of *Coxiella burnetii* endocarditis in a patient with prosthetic pulmonary valve replacement using next-generation sequencing of plasma microbial cell-free DNA. *Open Forum Infect Dis* 6: ofz242. doi: 10.1093/ofid/ofz242.
4. Alvarez J, Perez A, Mardones FO, Pérez-Sancho M, García-Seco T, Pagés E, Mirat F, Díaz R, Carpintero J, Domínguez L (2012) Epidemiological factors associated with the exposure of cattle to *Coxiella burnetii* in the Madrid region of Spain. *Vet J* 194: 102-107. doi: 10.1016/j.tvjl.2012.02.022.
5. Opsteegh M, Hogerwerf L, Nooijen S, Dam-Deisz C, de Heer L, Reusken C, Bouma A, Roest HJ, Nielsen M, van der Giessen J (2012) Experimental inoculation of male rats with *Coxiella burnetii*: successful infection but no transmission to cage mates. *Appl Environ Microbiol* 78: 5661-5665. doi: 10.1128/AEM.01169-12.
6. Candela MG, Caballol A, Atance PM (2017) Wide exposure to *Coxiella burnetii* in ruminant and feline species living in a natural environment: zoonoses in a human-livestock-wildlife interface. *Epidemiol Infect* 145: 478-481. doi: 10.1017/S0950268816002454.
7. España PP, Uranga A, Cillóniz C, Torres A (2020) Q Fever (*Coxiella burnetii*). *Semin Respir Crit Care Med* 41: 509-521. doi: 10.1055/s-0040-1710594.
8. Beslagić E, Hamzić S, Beslagić O, Zvizdić S (2006) Public health problem of zoonoses with emphasis on Q fever. *Ann N Y Acad Sci* 1078: 203-205. doi: 10.1196/annals.1374.094.
9. Biecker A, Bitzer M, Biecker E (2017) Q fever pneumonia in Southwest Germany: radiographic and clinical findings. *Rofo* 189: 146-151. doi: 10.1055/s-0042-121610.
10. Voloudaki AE, Kofteridis DP, Tritou IN, Gourtsoyiannis NC, Tselentis YJ, Gikas AI (2000) Q fever pneumonia: CT findings. *Radiology* 215: 880-883. doi: 10.1148/radiology.215.3.r00jn21880.
11. von Ranke FM, Clemente Pessoa FM, Afonso FB, Gomes JB, Borghi DP, Alves de Melo AS, Marchiori E (2019) Acute Q fever pneumonia high-resolution computed tomographic

- findings in six patients. *Br J Radiol* 92: 20180292. doi: 10.1259/bjr.20180292.
12. de Wit NC, de Jager CP, Meekelenkamp JC, Schoorl M, van Gageldonk-Lafeber AB, Leenders AC, Kusters R, Wever PC (2009) Markers of infection in inpatients and outpatients with acute Q-fever. *Clin Chem Lab Med* 47: 1407-1409. doi: 10.1515/CCLM.2009.307.
 13. Huang M, Ma J, Jiao J, Li C, Chen L, Zhu Z, Ruan F, Xing L, Zheng X, Fu M, Ma B, Gan C, Mao Y, Zhang C, Sun P, Liu X, Lin Z, Lu C, Lu Z, Zhou D, Wen B, Chen W, Xiong X, Xia J (2021) The epidemic of Q fever in 2018 to 2019 in Zhuhai city of China determined by metagenomic next-generation sequencing. *PLoS Negl Trop Dis* 15: e0009520. doi: 10.1371/journal.pntd.0009520.
 14. Andoh M, Naganawa T, Yamaguchi T, Fukushi H, Hirai K (2004) In vitro susceptibility to tetracycline and fluoroquinolones of Japanese isolates of *Coxiella burnetii*. *Microbiol Immunol* 48: 661-664. doi: 10.1111/j.1348-0421.2004.tb03476.x.
 15. Anderson A, Bijlmer H, Fournier PE, Graves S, Hartzell J, Kersh GJ, Limonard G, Marrie TJ, Massung RF, McQuiston JH, Nicholson WJ, Paddock CD, Sexton DJ (2013) Diagnosis and management of Q fever--United States, 2013: recommendations from CDC and the Q Fever Working Group. *MMWR Recomm Rep* 62: 1-30.
 16. Fenollar F, Fournier PE, Carrieri MP, Habib G, Messana T, Raoult D (2001) Risks factors and prevention of Q fever endocarditis. *Clin Infect Dis* 33: 312-316. doi: 10.1086/321889.

Corresponding author

Bo Xie, MD
 Department of Medical Administration,
 Zhuzhou Central Hospital, Zhuzhou Hospital Affiliated to Xiangya
 School of Medicine, Central South University,
 No.116, Changjiang South Road, Tianyuan District, Zhuzhou,
 Hunan, 412007, China
 Tel: +8619973365056
 E-mail: potter0712@126.com

Conflict of interests: No conflict of interests is declared.